

Prevalence and causal conditions for amputation surgery in the third world: ten years experience at Dodoma Regional Hospital, Tanzania

A. LORO and F. FRANCESCHI

The Orthopaedic Department, Dodoma Regional Hospital, Dodoma, Tanzania

Abstract

This is a partly retrospective study of 252 major limb amputations carried out in regional hospital in Tanzania over a period of ten years mostly by the authors.

The paper reports on the aetiology and levels of amputation and identifies prevalence and sex of the amputees. The causes of amputation – classified under tumours, vascular diseases, trauma, infections, burns, animal bites, iatrogenic causes, maduromycosis and miscellanea – are discussed with particular reference to the influence of the environment, cultural habits and local customs.

Introduction

This investigation was performed at the Orthopaedic Department of Dodoma Regional Hospital, one of the few orthopaedic centres currently operating in Tanzania.

It scrutinises all the available data concerning 252 major limb amputations, which were carried out from 1983 to 1992. The paper is an epidemiological research aimed at investigating, as accurately as possible, the field of amputation surgery in a developing country.

It is a report focusing on topics which were raised or hinted at by a paper published a few years ago (Loro *et al.*, 1990), to which the readers are referred, because it offers still valid general information about the Region, the hospital, the working setting and the local facilities. When comparing the resulting data with those reported by similar studies conducted

in western countries, one can easily appreciate the peculiarities and the clear differences, mainly when consideration is given to general parameters, such as age and aetiology, or to specific ones such as amputation level.

Looking at the different aetiological groups (Table 1), one of the most interesting points concerns their classification and their relative percentages as regards the total, with tumours topping the list, followed by vascular diseases.

Traumatic injuries was the third most prevalent group, with injuries at work and a rising number of motor and train accident victims, a trend reported also by other African countries during the last years.

Finally, there was a group of causes representing almost 25% of the total number that indicate how the environment, cultural habits and local customs may play a role as cause or predisposing agents.

Materials and methods

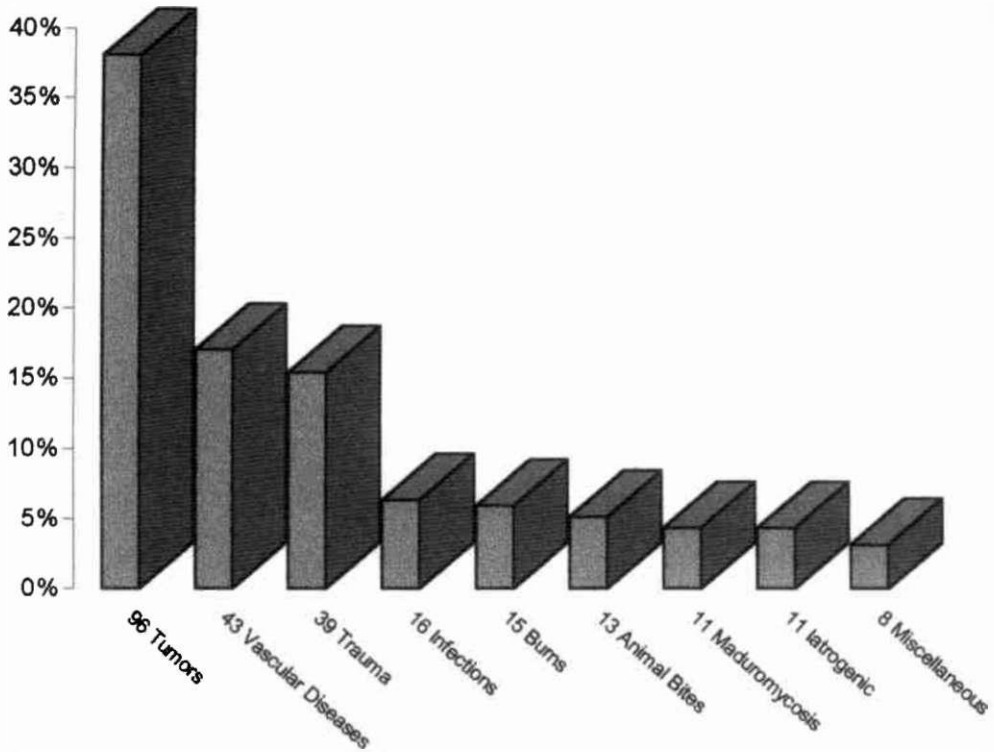
In the period under review, 241 patients underwent limb amputations of these, 8 lost two limbs while one lost all four limbs. There were 172 males and 69 females, with a mean age at the time of operation of 39.5 years (minimum 20 days, maximum 71 years). This parameter has shown great variation in relation to the specific aetiological agents.

There were 214 amputations involving the lower limbs of 207 patients (148 males and 59 females) and 38 upper limb amputations performed on 34 patients (24 males and 10 females). Table 2 shows the distribution of different types of amputation.

With the exception of a few cases, all

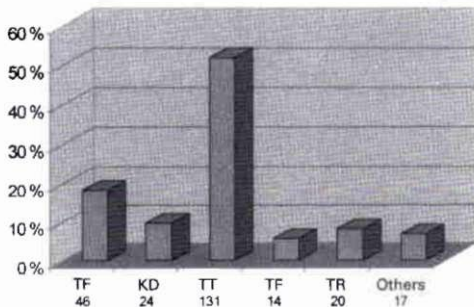
All correspondence to be addressed to Antonio Loro, Via Chiesa 28, 35044 Montagnana, Padova, Italy.

Table 1. Prevalence of amputations by indications. There are thirty cases of unclear classification included in the vascular disease group (see text).



amputations were performed by either author, according to standardised pre-operative and post-operative protocols. Pre-operatively, only

Table 2. Prevalence of amputations by level. Note the clear prevalence of amputation at or below knee level (approximately 60% of the total). This high percentage finds its explanation in a group of causes that are specifically related to an African setting.



TF: trans-femoral
 KD: knee disarticulation
 TT: trans-tibial
 TF: trans-femoral
 TR: trans-radial

simple laboratory investigations, such as complete blood cell count, blood sugar and routine urinalysis were requested. Plain radiographs of the affected part were taken only if the investigation was judged clinically justifiable by the surgeon. When needed, specimens for histological examination were sent abroad, mainly to the Department of Surgical Pathology at the Mayo Clinic in Rochester, Minnesota, and, less frequently, to the Pathology Department of the University of Verona, Italy.

Before discharge, patients were informed about the rehabilitation programme available at the hospital, including the range of orthopaedic devices which could be provided.

Indications for amputation

Tumours

Tumours in general, were directly involved in almost 40% of the total number of amputations. Following an histological basis, they have been classified into four different groups, namely bone tumours, soft tissue sarcomas, melanomas

and squamocellular carcinomas. There were 11 cases of malignant bone tumours (7 osteosarcomas, 2 giant cell tumours, 1 Ewing's tumour and 1 Burkitt's lymphoma). As expected, all patients were young, mostly in their second decade of life. All had reported late to hospital and, when seen, were showing clinical signs and radiological features of a malignancy in an advanced stage. Except for the child treated for Burkitt's lymphoma, the prognosis was grim for all of them.

Eight patients presented with soft tissue sarcomas (3 synovial sarcomas, 1 Kaposi's, 2 fibrous hystiocytoma, 1 leiomyosarcoma and 1 schwannoma) while five patients, all females aged more than 50 years, presented with long-standing foot melanomas (Fig. 1).

All the remaining patients belonging to the tumours group were diagnosed as having squamocellular carcinomas, a rather common cancer in Tanzania. As already reported (Amir *et al.*, 1992; Lifeso *et al.*, 1990) the development of this cancer seems strictly related to long-standing ulcers, burn scars, leprotic ulcers (Awofeso, 1992) and chronic fistulae. All are regarded as predisposing factors to carcinomatous degeneration of the skin and, indeed, they were frequently recorded among the patients of this series. There were 58 males and 14 females, a male:female ratio of 4:1. Commonly, they were in their fifth or sixth decade of life when amputation was performed (mean age: 53 years).

All tumours, with the exception of three cases, involved the lower limb, particularly the distal

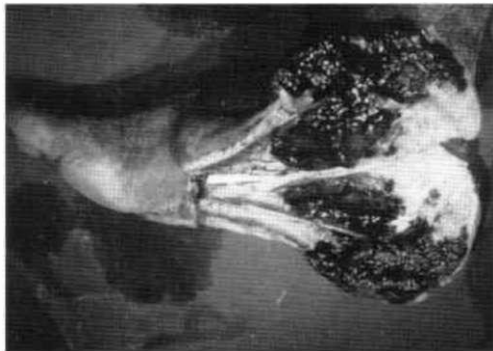


Fig. 1. Pathological aspect of a deeply invasive melanoma involving the hindfoot of a 60-year-old woman. Note the blackening of the calcaneal tuberosity. Amputation was employed as a palliative act. Patient died within 4 months of amputation.

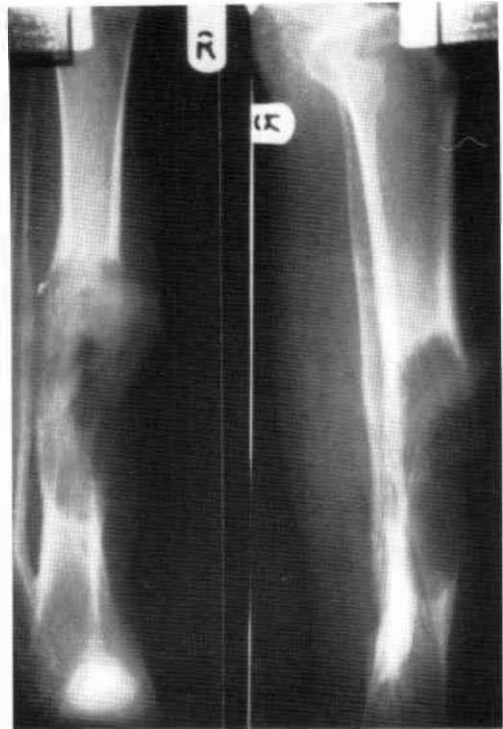

Fig. 2. Extensive infiltration of the right tibia of a middle-aged man, who presented with a cancerised skin ulcer dating back 10 years. A leg amputation was performed. As in similar cases the stump healed well; the bone appears to be normally structured and spared just a few centimetres proximally to the border of the lytic area. No reamputation or revision surgery was required for local relapse of the condition.

half of the leg or the ankle joint region, with no significant difference in relation to the side.

Most of the patients were farmers, illiterate, often living alone under difficult circumstances. All had a long past medical history; tumours were, on admission, at an advanced stage, often infiltrating the bones and, in almost 50% of the cases, already spread to the regional lymph nodes. Pulmonary metastases were recorded in a few patients.

Two prevalent radiographic patterns were observed.

The first one was that of bone infiltration. Roentgenographic pictures varied from minimal indentation of the cortex to multiple lytic areas with scalloped borders (Fig. 2), from extensive resorption, leading to pathological fracture, to complete bone disappearance as is typically seen in metastatic lesions (Fig. 3).

The second one was a picture of bone

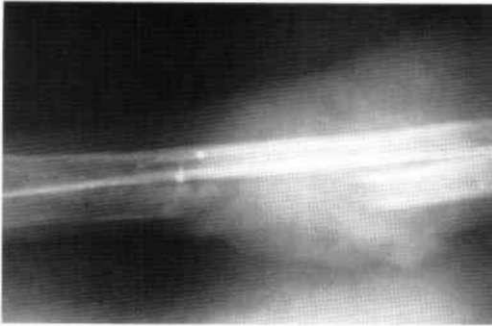


Fig. 3. Extensive ulnar defect observed in a 45-year-old man having a squamocellular carcinoma of three years duration. Cancer developed in a scar, left by a burn which had occurred ten years earlier.

“irritation”, as that seen in chronic periostitis. Radiographically, it appeared as an enlargement and deformity of both leg bones, particularly the fibula (Fig. 4). It was not uncommon to observe an involvement of the interosseous membrane, signalled by the presence of scattered, round calcifications; a picture of complete synostosis was seen in long-standing cases.

Post-operative examination of the amputated legs confirmed the radiographic findings. There were specimens characterised by extensive bone replacement by neoplastic tissue and cases where bone was spared, even if it was in close contact with the cancer. To the naked eye, at least, the cortex underlying the tumour was apparently intact.

No clear relationship was established between either bone reaction and any other parameter such as cause, site or length of the disease, sex, age, previous treatments and grade of tumour differentiation.

Vascular diseases

This is a section that had to be revised and reorganised over the years, because of the uncertainty of classification of a rather important number of vasculopathies typically seen in an African context.

The assertion that classic atherosclerosis and diabetic vasculopathy are almost unknown to Africans (Rolfe, 1990) was confirmed by the authors' study, where only three amputations were performed for diabetic complications and all three patients were belonging to the Arab or Indian communities living in the region.

It was assumed, for a long time, that Buerger's disease was to be regarded as a rare cause of

amputation in African people. But, in order to cast light on several patients who described the clinical course seen in thromboangioitis obliterans, since mid-89, specimens for histological examination were taken in any case of gangrene of dubious aetiology. Surprisingly, out of ten specimens that were sent to the USA for diagnosis clarification, six showed features typical of thromboangioitis, whereas in the remaining four the findings of “vasculitis- phlebitis” were considered highly suggestive of it. Although only a few patients among them had a history of smoking, it should be kept in mind that in Dodoma region tobacco is widely chewed and/or sniffed.

All six patients with histologically proven Buerger's disease were males, four were older than 55 years, three were smokers and one, the youngest patient in this group (35 years), was also leprotic and the only one with upper limb involvement.

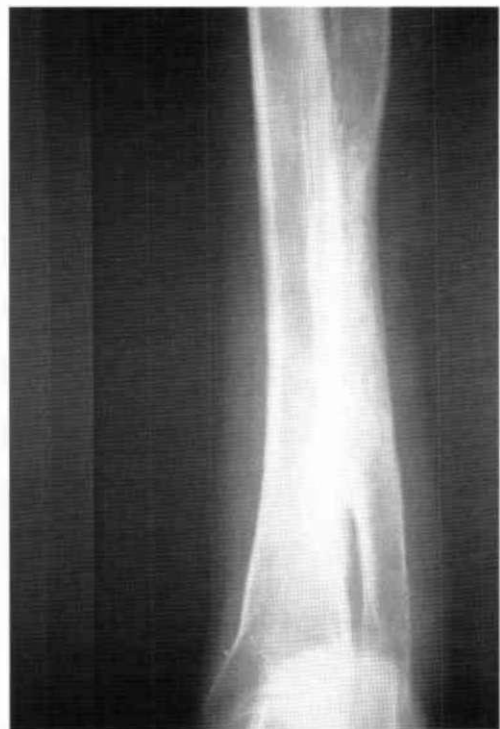

Fig. 4. Radiographs of the left leg of a 63-year-old man, presenting with a skin cancer that developed in an ulcer spontaneously erupted three decades earlier. Note the fibular enlargement and deformity, coupled with a synostosis matching the involved leg segment. Usually complete synostosis is preceded by slow but progressive calcification of the interosseous membrane.

Even the four patients with findings suggestive of Buerger's were all males, three were older than 60 years and only one was an active smoker.

Open questions and doubts remain when the most consistent group included in this section is addressed, because to date there is no histological evidence to support sure classification. However, on the grounds of prevalence of Buerger's disease, records of this group of thirty patients were reviewed and, retrospectively, it was possible to separate 15 cases of probable thromboangiitis obliterans, four involving the upper limbs.

On the other hand no useful clues were found for classification of five cases of foot gangrene observed in three children aged 2 years, 2 years and 6 months and 6 years, even if a coagulation disorder was postulated. Parents denied permission for autopsy examination in all the cases.

No explanation was found for ten patients and they were included into the general group of "idiopathic peripheral gangrene" or "gangrene of unknown origin" (Barr *et al.*, 1972; Steiner and Hutt, 1972). Among them, one patient reported that his hand became necrotic after taking, three weeks earlier, a full course of chloroquine for a malaria attack, while two other patients reported a history quite similar to that described by Gelfand (1947). Furthermore in three cases histological examinations reported inconclusive findings, because the pathologist was unable to further classify the evident vasculitis or to explain the simple venous thrombosis.

Trauma

Out of 39 amputations included in this group, 10 were due to casual accidents, 4 to injuries at work, and 17 were due to motor and train accidents.

Criminal actions were responsible for 8 amputations. Among them, six occurred during cattle rustling; five were caused by pangas or axes and one by a gun-shot. One alleged thief lost both upper limbs after a rope was tied around his arms and he was left helpless for several hours in the bush (amputations were performed seven days apart).

Infections

Chronic osteomyelitis required lower limb

amputation in four patients; three of whom were children aged less than 15 years and all had been repeatedly operated on before reaching the authors' institution.

Five amputations were due to gas gangrene, all following an overlooked thorn prick injury; three to the muscles of the calf region and two to those of the forearm. All the interventions were performed as emergency procedures in rapidly evolving life-threatening conditions. Seven ablations were due to severe limb infections secondary to an inappropriately managed open injury. In six patients, all but one coming from other hospitals operating in the area, it was necessary to resort to an open type of amputation in order to eradicate the infection.

Interestingly one upper limb amputation was carried out for an extensive hand phlegmon following an improperly managed human bite that had occurred a few days earlier.

Burns

Fire and epilepsy are considered together in this section grouping 15 amputations, mostly performed in young people and sometimes in infants.

In villages, the custom to place cooking fires at floor level predisposes to burns children who crawl or play inside or around the hut, especially when they are in custody of young sisters. Besides that, there seems to be a link between fire and epilepsy, considering the relatively high number of epileptic patients who got burnt when left alone. In this series, this link was recorded in six patients.

Although there is no satisfactory explanation for this common observation, it is suggested that fire, with its changing and flashing light, could trigger epileptic crises.

On admission, the burnt limbs were all in a condition of dry gangrene or mummification, with exposed bones and joints. Furthermore, more than half of the patients were showing additional scars from previous injuries in other regions of the body, while two of them had already lost one limb some years earlier.

Animal bites

Wild animal bites were the cause of 13 amputations.

The bite of the puff adder, locally known with the name of "kifutu" (Maimu, 1982), whose venom has haemolytic properties, was the cause

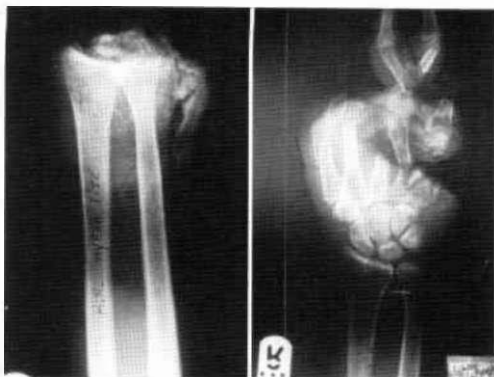


Fig. 5. A young man, attacked by a rabid(?) hyena lost both hands. He was in a group of six people going home from work, at mid-day. Only one person was left unhurt. A few weeks later, another group of four women was attacked in the same area.

of 8 amputations, mostly involving the upper limbs of young farmers.

All patients were seen late; it has often proved impossible to identify and separate natural damage from that related to human action at the accident site. Severe maiming injuries, caused by hyena attacks and involving mainly the upper limbs, were seen in 5 patients in the series (Fig 5). Because of extensive mangling of bones and soft tissues, a radical solution had to be employed in all the cases. It is well known that the hyena is provided with extremely powerful jaws.

What still needs clarification is the assertion that only rabid beasts attack human beings, as is thought by indigenous people.

Iatrogenic causes

This is a section which includes 11 amputations, all seen in children or young adults, occurring after polio surgery, fracture treatment or topical drug application on the feet.

Three lower limb amputations were performed in two polio patients a few days after an one-stage surgical correction of severe hip and knee joint contractures, while four children lost one upper limb for vascular complications in the course of treatment of simple forearm fractures (Ofiaeli, 1991; Wilson, 1991). In three cases, the plaster was applied in the out-patient clinic by untrained staff, while in one case the immobilisation was applied at village level, by means of two wooden sticks held together with a home-made bandage.

Four cases of dry gangrene were observed in male patients who had been attending the services of local healers for pain and numbness. All reported that the foot gangrene became evident after the application of a liquid substance on fresh razor cuts. It is unclear whether the gangrene was really due to the drug itself or whether the patients, all active smokers, were suffering from Buerger's disease in its early phases.

Maduromycosis

This chronic fungal infection that almost exclusively involves the foot was managed by leg amputation in 11 patients. All cases were farmers, in their mid-age. This is a condition that, if left untreated for several years, may lead to collapse of the bony architecture of the foot and, consequently, to complete loss of function (Loro and Franceschi, 1998). Although a quite rare condition in this Region, 1 case per year, it must be kept in mind and suspected at an early stage. In later phases, the foot may become really useless and troublesome, and the patient himself may demand a radical solution. That happened in four cases in this series.

Miscellanea

One amputation was due to a congenital cavernous lymphangioma seen in a child whose limb mass was 15kg.

Two ablations were done in new-borns for constriction band syndrome (Bourne and Klassen, 1987), while two were performed in children who presented with tibial total longitudinal deficiencies. According to the classification of Jones *et al.* (1978), one child had a type 1B and the other a type 2 deficiency.

Finally three amputations were carried out in two patients who were referred from an area stricken by an outbreak of meningococcal meningitis. They were showing the peripheral gangrene that is sometimes observed among the complications of purpura fulminans (Huang and Clarke, 1997) (Fig. 6).

Discussion

This clinical study on amputation surgery in a developing country offers more than one area for discussion and for further research, mainly when data concerning specific fields of investigations are compared with those coming out from researches conducted in western countries.

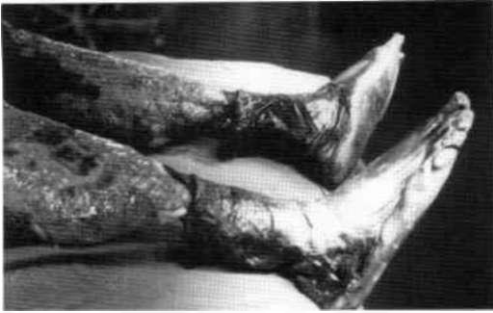

Fig. 6. A 31-year-old man was sent to the Department from a nearby district where an epidemic of meningococcal meningitis was going on. As known, extensive tissue necrosis may be seen in case of purpura fulminans. Bilateral leg amputation was required in this case, followed, later on, by multiple skin grafts. Patient survived and, a few months later, he was supplied with bilateral patellar-tendon-bearing prosthesis.

There are striking differences if consideration is given to specific parameters such as aetiology, age, availability of diagnostic tools and treatment options.

First of all, this study has confirmed the findings reported by other authors (Amir *et al.*, 1992), of the high prevalence of the squamocellular carcinoma, a cancer responsible for almost 30% of the total number of the reviewed amputations. There seems to be an attitude to overlook this tumour, probably because of the slow progress of the disease allowing farmers to conduct an acceptable quality of life for several years. It was quite unusual to take care of patients affected by cancer in early stages.

It is wrong to consider a chronic leg "ulcer" as a benign lesion; this tumour has to be regarded as a dangerous and debilitating neoplasm, able to spread to regional lymph nodes (more than 50% in this series) or to distant organs such as liver or lungs.

As for other malignancies, amputation was sometimes prompted by a mixture of palliative purposes and humanitarian reasons. Treating malignancies in peripheral hospitals in developing countries often presents a diagnostic task which is not balanced by available curative options.

Prevention, early diagnosis and, when possible, prompt referral should be given a decisive push, particularly in rural areas, where it is easier for skin lesions to occur and where the great majority of the population live.

Analysis of the data showed that people living in rural areas were more prone to get diseases or to sustain traumatic injuries responsible for amputation, with greater exposure to snake bites, to skin ulcers and to fungal infections. Moreover villages in rural zones are usually poorly served by public transport, so referring patients to qualified health institutions may become really difficult.

The authors' experience suggests that particular attention should be directed to lesions due to thorn pricks, to burn scars, to leprotic ulcers and to chronic sinuses. It is interesting to note that several patients admitted that the ulcer erupted in an area where, some decades earlier, a thorn prick had occurred.

Once more this research has shown that diabetes is rarely responsible for gangrene in African people perhaps because of diet (Rolfe, 1990).

On the other hand the collected data indicate that the prevalence of Buerger's disease deserves to be redefined in further studies. One may suppose that several cases diagnosed in the past as idiopathic gangrene could have been classified as thromboangiitis obliterans by a trained pathologist.

Under the general term of peripheral vascular diseases there are cases that for the time being will be included into the idiopathic gangrene group. Proper classification needs a diagnostic armamentarium which is still beyond the limited resources available to regional or district hospitals.

Clearly there is a need for different diagnostic categories, because diseases that are accounting for 90% of the total number of amputations in western countries are barely observed in epidemiological studies conducted in African regions.

REFERENCES

- AMIR H, KWESIGABO G, HIRJI K (1992). Comparative study of superficial cancer in Tanzania. *East Afr Med J* **69**, 88-93.
- AWOFESO N (1992). Neoplastic transformation of chronic ulcers in leprosy. *Trop Doc* **22**, 120.
- BARR RD, ROY AD, MILLER JRM (1972). Idiopathic gangrene in African adults. *Br Med J* **4 November**, 273-274.

- BOURNE MH, KLASSEN RA (1987). Congenital annular constricting bands: review of the literature and a case report. *J Pediatr Orthop* **7**, 218-221.
- GELFAND M (1947). Symmetrical gangrene in the African. *Br Med J* **1**, 847-849.
- HUANG S, CLARKE JA (1997). Severe skin loss after meningococcal septicaemia: complications in treatment. *Acta Paediatr* **86**, 1263-1266.
- JONES D, BARNES J, LLOYD-ROBERTS GC (1978). Congenital aplasia and dysplasia of the tibia with intact fibula: classification and management. *J Bone Joint Surg* **60B**, 31-39.
- LIFESO RM, ROONEY RJ, EL-SHAKER M (1990). Post-traumatic squamous-cell carcinoma. *J Bone Joint Surg* **72A**, 12-18.
- LORO A, FRANCESCHI F, MOSHA ECP, SAMWEL J (1990). A survey of amputations at Dodoma Regional Hospital, Tanzania. *Prosthet Orthot Int* **14**, 71-74.
- LORO A, FRANCESCHI F (1998). Maduromycosis: observations on 14 cases. *Atti SERTOT XL*, 119-123.
- MAIMU M (1982). A glossary of animals and snakes of Tanzania. - Tanzania: Tanzania Publishing House.
- OFIAELI RO (1991). Complications of methods of fracture treatment used by traditional healers; a report of three cases necessitating amputation at Ihiala, Nigeria. *Trop Doc* **21**, 182-183.
- ROLFE M (1990). Diabetes mellitus in Africa: part II. *Postgrad Doc Afr* **12**, 125-128.
- STEINER IO, HUTT MSR (1972). Vascular changes in the idiopathic peripheral gangrene of the tropics. *Trop Geogr Med* **24**, 219-225.
- WILSON JN (1991). Iatrogenic gangrene in the third world. *Trop Doc* **21**, 137-138.