

## Clinical note

# Rehabilitation management for a patient with a radical forequarter amputation with chest wall resection.

J. H. B. GEERTZEN\*, H. J. HOEKSTRA\*\*, A. ELZINGA\*\*\* and J. S. RIETMAN\*

\*Department of Rehabilitation, University Hospital, Groningen, The Netherlands

\*\*Department of Surgical Oncology, University Hospital, Groningen, The Netherlands

\*\*\*The Orthopaedic Workshop OIM, Haren, The Netherlands

### Abstract

Since the improvement of surgical oncological operative procedures, anaesthesiology and intensive care facilities, forequarter amputations are being performed with increasing frequency and decreasing morbidity and mortality. This clinical note reports the rehabilitation and prosthetic management of a patient with an extensive forequarter amputation including pneumectomy.

### Introduction

Limb salvage procedures using combined modality therapies are gaining acceptance as a treatment choice in patients with marginal resectable soft tissue or bone sarcomas of the upper limb. For a small group of patients, an interscapulothoracic amputation or a radical forequarter amputation with chest wall resection is the only final surgical treatment with either a curative or a palliative intent (Stafford and Williams, 1958; Mansour and Powell, 1978; Ham *et al.*, 1993). A forequarter amputation is a resection of the chest wall, indicated for primary bone and soft tissue tumours, involving the shoulder girdle, axilla and chest wall, as well as for recurrent breast cancer in the axilla after irradiation (Roth *et al.*, 1984). The purpose of this report is to describe the rehabilitation management focusing on the prosthesis in a patient with an extensive radical forequarter amputation.

### Case report

#### Medical history

A 28-year-old healthy young man known with Recklinghouse disease (neurofibromatosis) presented with pain at his left chest wall. His skin showed several typical "cafe au lait" spots and many little noduli.

In the medical history, the patient complained earlier of pain in his right chest wall. An x-ray of the thorax (the right side) showed some signs of a soft tissue mass. A magnetic resonance imaging (MRI) demonstrated a calcified mass with central necrosis, fixed to the right chest wall. Pre-operatively, lung function was studied using spirometry, and distant metastases were ruled out by means of computer tomography scans of the lungs and a bone scan. The tumour was curative resected "en bloc" with a part of the right chest wall. It appeared to be a malignant Schwannoma.

Half a year later, he had the same complaints of the contralateral chest wall. Again it appeared to be a malignant aggressive Schwannoma which reached far into the thorax. There were no distant metastases. Lung function and vital capacity were good. In an extensive discussion with the patient and his family, concerning the expected quality of life after surgery, a very mutilating but in design, curative operation was performed: a total resection of the tumour including pneumectomy and interthoracoscapular amputation of the left upper limb (Figs. 1 and 2). This procedure was performed knowing that the disease-free median survival period 24 months after surgery would be somewhat more than 40% (Doorn *et al.*, 1995). After consultation with the rehabilitation team, whether it would be possible to fit such a patient with a prosthesis, surgery was planned.

All correspondence to be addressed to J. H. B. Geertzen MD, Department of Rehabilitation, University Hospital Groningen, Hanzeplein 1, Postbox 30.001, The Netherlands. Tel: (+31) 50 3612295. Fax: (+31) 50 3611708.

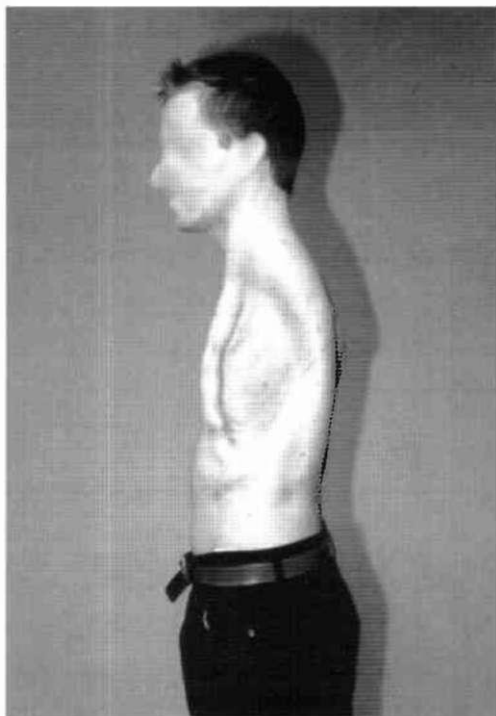


Fig. 1. Side view.

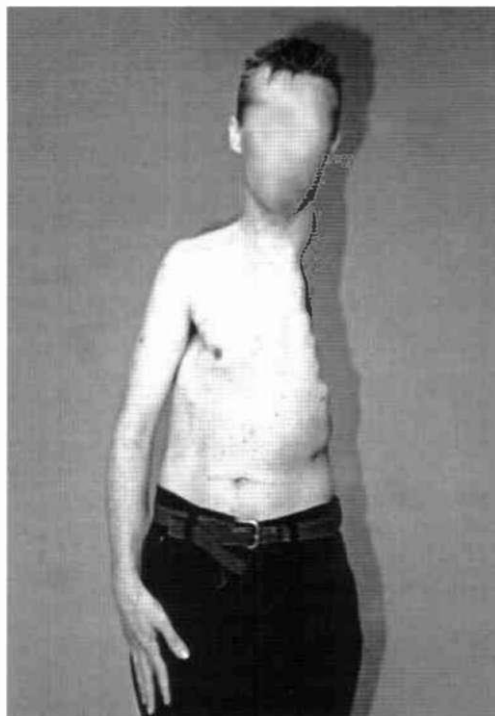


Fig. 2. Front view.

The post-operative course was uncomplicated. Despite the expected complication of a flail chest, his ventilation capacity was sufficient. Histopathological examination revealed total resection of the tumour which had also signs of a sarcoma. The patient was additionally irradiated.

#### *Rehabilitation management*

The first precautions were to start with pre- and post-operative pulmonary physical therapy. Pain management was started and the patient got a first temporary orthosis a few days after operation. The orthosis consisted of a cotton corset with at the left side a protective vitratene perforated (ventilation) cast. The latter to protect the heart which lies just beneath the skin because of the resection of the protective chest wall. A removable shouldereap was moulded also. Immediate postoperative casting was not possible because of the extreme pain of the wounds, so the prosthesis was made with estimated body circumferences. Physical therapy began with mobilization, balance training, and condition training. Fourteen days after operation the patient was able to leave the

hospital. Outpatient clinic rehabilitation continued balance and condition training, and occupational therapy started with one handedness training. Furthermore, little adaptations in his house were provided. A psychologist continued to be an active member of the rehabilitation team. Six weeks after operation the patient was fitted with a definitive prosthesis which included a silicone pad at the skin. This pad was sewn in a cotton corset. This cotton corset was attached to a thin, rigid thermofac harness to protect the vital organs, lung and heart. To fill up the moulded thorax shape a polystyrene foam was used (Fig. 3). In the prosthesis a shoulder shape was moulded. Because of this extensive resection, the imbalance and posture of the patient and the possible force moments, a prosthetic arm was omitted. Later on, the silicon pad had to be removed because this was too adhesive to the skin and skin injuries were the result. As an alternative a soft polyethylene foam layer was used. The prosthesis was fitted to the body with a bandage and it was supported by the sternum and the thoracic vertebrae. The weight of the prosthesis was not more than 300 grammes. In

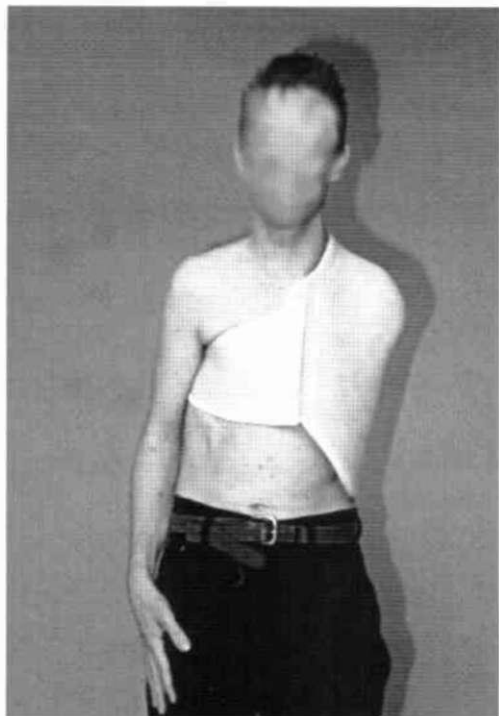


Fig. 3. Patient with prosthesis.

summary this prosthesis had a protective and a cosmetic restoring function. Because of hygienic reasons, the patient got two prostheses. The first month postoperative, the patient had phantom sensations, no phantom pain. After a few weeks phantom pain developed, all his fingers were in a flexed position, and he needed morphine. After two months vocational therapy started.

Nine months after the amputation the patient started to complain over pain in his legs and neck. Additional research revealed several metastases. Palliative therapy was started with irradiation. Unfortunately, one year after the amputation the patient died of multiple metastases.

### Discussion

A radical forequarter amputation with chest wall resection is still a rare amputation. Most of these patients are seen in an university hospital. Literature search did not reveal anything about fitting a prosthesis in such a patient. This was the first patient with such mutilating amputation who was fitted with a prosthesis in the hospital. The only two studies mentioning a prosthesis for this kind of amputation were published more

than 20 years ago (Wurlitzer, 1972; Mansour and Powell, 1978). The descriptions of the prostheses in literature were of a shoulder cap, fitted six weeks after surgery (Wurlitzer, 1972; Mansour and Powell, 1978). However, the mutilation character of those amputations was less.

Although a mechanical arm and hand is the preferred prosthesis for a forequarter amputation patient, for this patient with such an extended amputation and mutilating effect, the prosthesis described earlier was prescribed. A considerable cosmetic improvement was possible by use of a one piece artificial shoulder and breast device. Fitting the prosthesis to the patient's body was difficult. The sternum and vertebrae were chosen as supporting body parts. In this way the prosthesis had to be very light. The expected postoperative flail chest was not a contraindication for wearing the prosthesis. The cosmetic appearance of the prosthesis made a considerable difference in rehabilitating this patient to his family and to society. The highly motivated patient and very understanding family and friends were instrumental in achieving successful rehabilitation following this very major and mutilating operation although the survival period was short.

### Conclusion

Primary therapeutic success after a radical forequarter amputation is dependent on tumour type, grade, completeness of resection, possibilities for reconstruction and deterioration of pulmonary function. Rehabilitation is dependent on the motivation of the patient and the support of the family and rehabilitation team. Fitting a prosthesis described in this case is individually very different and difficult and is a challenge for the team. Primary function of the prosthesis is to protect heart, lung and mediastinum and secondly to give the patient a cosmetic appearance to return to society.

### REFERENCES

- DOORN PF, MOLENAAR WM, BUTER J, HOEKSTRA HJ (1995). Malignant peripheral nerve sheath tumours in patients with and without neurofibromatosis. *Eur J Surg Oncol* **21**, 78-82.
- HAM SJ, HOEKSTRA HJ, SCHRAFFORDT KOOPS H, EISMA WH, OLDHOFF J (1993). The interscapulothoracic amputation of malignant diseases of the upper extremity with a review of the literature. *Eur J Surg Oncol* **19**, 543-548.

MANSOUR KA, POWELL RW (1978). Modified technique for radical transmediastinal forequarter amputation and chest wall resection. *J Thorac Cardiovasc Surg* **76**, 358-363.

ROTH JA, SUGARBAKER PH, BAKER AR (1984). Radical forequarter amputation with chest wall resection. *Ann Thorac Surg* **37**, 423-427.

STAFFORD ES, WILLIAMS GS (1958). Radical ransthoracic forequarter amputation. *Ann Surg* **148**, 699-704.

WURLITZER FP (1972). Improved technic for radical transthoracic forequarter amputation. *Ann Surg* **177**, 467-471.