

Morphological changes during early trans-tibial prosthetic fitting

M. LILJA*, P. HOFFMANN** and T. ÖBERG*

**Department of Biomechanics and Orthopaedic Technology, University College of Health Sciences, Jönköping, Sweden*

***MR-Centre, County Hospital Ryhov, Jönköping, Sweden*

Abstract

Morphological changes in the amputation stump may have serious implications regarding the suspension and fit of the prosthetic socket. In an earlier study (Lilja and Öberg, 1997) the authors have shown that the volume of the trans-tibial amputation stump decreases according to a negative power function after amputation, and that the stump volume does not stabilise until four months after the operation. In the present study, Magnetic Resonance Imaging (MRI) technique was used to examine morphological changes in the amputation stump after trans-tibial amputation in a small number of cases. The authors expected to find a decrease in the cross-sectional area of the stump and of the separate muscles similar to the findings in earlier studies. However, two different patterns were found. The cross-sectional area of the entire stump as well as that of the medial muscle group changed according to the authors' hypothesis, i.e. an initial fast decrease, followed by a more moderate decrease of the area. In the lateral muscle group another pattern was found. After an initial rapid decrease the area increased, sometimes to a magnitude larger than the initial value. After the amputation the lateral muscle group may acquire a new function, contributing to the suspension of the socket. Despite the limited number of patients, this study presents findings which may be important in the clinical fitting of trans-tibial prostheses.

Introduction

Changes in the volume, form and internal structures of the stump may jeopardise prosthetic fitting in the early rehabilitation phase after a trans-tibial amputation.

Several studies have examined postoperative volume changes of amputation stumps, e.g. Lilja and Öberg (1997). However, studies concerning qualitative changes, i.e. specifically which morphological structures change, and to what extent, have not been conducted. Do these changes involve a homogeneous development, or is there a considerable heterogeneity among different tissues and muscle components? A better understanding of these processes may contribute to improved prosthetic fitting during the rehabilitation phase.

After a major amputation, severe traumatic oedema and hematoma occur in the stump, which can be reduced by bandaging and physical activity (Levy, 1977; Manella, 1981; MacLean and Fick, 1994). The stump volume decreases gradually during the early maturation process due to a reduction in postoperative oedema. Lilja and Öberg (1997) have shown that the volume of the stump reduces according to a negative power function, but the question remaining is what are the qualitative and quantitative changes occurring inside the stump? Are there any differences in the amount of atrophy between the gastrocnemius muscle, that continues to engage the knee joint, and the other muscles that do not engage any joint, after the trans-tibial amputation?

To examine the structures inside the human body, Magnetic Resonance Imaging (MRI) is a very effective, but expensive and complex method. Jaegers (1993), in her thesis, has shown the usefulness of MRI in studying the

All correspondence to be addressed to M. Lilja, Department of Biomechanics and Technology, University College of Health Sciences, P.O. Box 1038, S-551 11 Jönköping, Sweden. Tel: +46 36 324769 Fax: +46 36 324762.

morphology of trans-femoral amputation stumps. MRI also provides a non-invasive technique for the study of trans-tibial stump muscles.

The process of muscle atrophy begins immediately postoperatively, and continues simultaneously with a reduction in oedema, (Baumgartner and Langlotz, 1980). When only external stump volume is studied, these components cannot be differentiated. The amount of this atrophy is correlated to physical activity, postoperative bandaging and prosthetic fit (Levy, 1980; Renström *et al.*, 1983).

The two heads of the gastrocnemius muscle originate from the medial and lateral condyles of the femur and for trans-tibial amputees, the distal part of the muscle is attached through myodesis to the tibial end. This changes the function of the gastrocnemius muscle from that of a two joint muscle, to a single joint muscle after the amputation. After the amputation the soleus muscle and the anterior tibial muscle do not affect any joint. Such circumstances may influence the amount and rate of atrophy in the stump.

Several authors have described possibilities of controlling movement and suspension of the prosthesis during motion by contracting the stump muscles (Burgess *et al.*, 1974; Kegel *et al.*, 1981). However, this control depends on the function of the muscles in the trans-tibial stump and the patient's ability to activate and control them.

Kegel *et al.* (1981) have shown that exercise of the stump musculature should be a part of routine physical therapy. The amputees must be able to control fully the musculature during gait. Exercises should include specific training of the gastrocnemius muscle as well as the anterior tibial muscle. As described by Burgess and co-workers (1974), these muscles do increase in volume during the exercise period.

Amputees in the western world today have a very high average age, and amputation is due, in most cases, to peripheral vascular disease with or without the presence of diabetes mellitus. Furthermore, many of these patients are also in poor physical condition (Alaranta *et al.*, 1995; McWhinnie *et al.*, 1994). In an earlier study, Hedberg *et al.* (1989), presented a 50 per cent lower number of muscle fibres in the gastrocnemius muscle in amputated legs compared with non-amputated legs, which is

probably related to the relative inactivity of the amputated leg and to long-standing vascular insufficiency. When a muscle becomes inactive, the muscle fibres begin to degenerate and fat imbibes into the muscle tissue.

The aim of the present study was to describe the morphological changes in trans-tibial stump musculature during the first months after amputation. The hypothesis was that the muscle area decreases due to both atrophy and a reduction in postoperative oedema, and that muscle area reduction follows a similar course to that of stump volume reduction presented in earlier studies (Lilja and Öberg, 1997; Golbranson *et al.*, 1998).

Material and methods

Subjects

Inclusion criteria to join the study were: trans-tibial amputation due to arteriosclerosis, the ability to understand the study design, and consent to participate in the study.

Seven trans-tibial amputees, two women and five men, with a mean age of 69.9 (range 57-80) years were included. One patient was bilaterally amputated at one operation session. Therefore, a total of eight amputation stumps were included in the study. All patients were fitted with traditional patellar-tendon-bearing trans-tibial prostheses, PTB, during the study. The prosthetic fittings did not influence the study. One patient, case 5, was re-amputated to a higher trans-tibial level, between the second and third examination, therefore he was excluded. Cases 6 and 7 were excluded after the first examination due to re-amputation at a higher level, trans-femoral. Case 8 died between the first and second examination. For the final evaluation four amputation stumps remained.

Study design

Three MR examinations were performed on each patient. The first examination was performed during the second week after amputation, the second after six and finally the third examination after 28 weeks. The examinations were performed by a radiologist.

MRI is an exclusive and expensive technique. For this reason the study was designed as a case study.

Magnetic Resonance Imaging

In order to obtain transverse MR images a

Siemens Magnetom 63 SP 4000 with a spin echo technique, T1 weighted, TR/TE 720/20, with a field of view (FOV) 180mm with a 256 x 256 matrix, was used. The slice thickness was 6.0 mm and the distance between the slices 0.5 mm. Images were obtained from the femoral condyle to the distal end of the trans-tibial stump.

Area and circumference analysis

The contour of the stump and the separate muscles on the MR images were manually copied to a transparent paper and then scanned into a computer. The circumference and area were calculated and registered with software, BIMAREA, developed at the authors' department. The anterior tibial muscle and the posterior muscle group, including the medial and lateral heads of the gastrocnemius and the soleus muscle, were identified and registered. Each muscle in the posterior muscle group was also identified and registered.

Transverse MR images were chosen from three different levels of the amputation stump, at 33% of the total stump length, 50% and 66% of the total stump length (Fig. 1). The total length of each amputation stump was recorded at every examination.

Normalisation

All measurement of muscle area and circumference were normalised relative to the first examination, i.e. the first examination was set at 100 per cent.

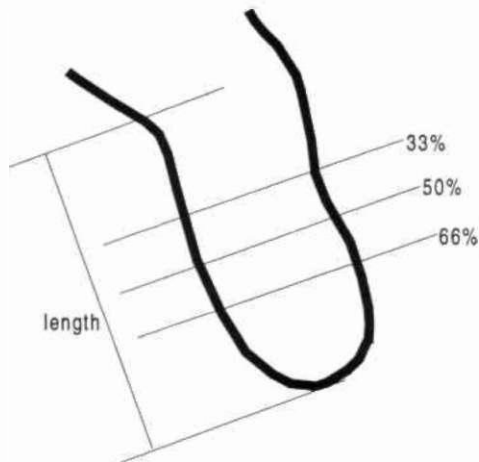


Fig. 1 Different levels for MR images.

Case Histories

Case 1

A 71-year-old, non-smoking male who has had diabetes mellitus for 11 years. He underwent a by-pass operation three years ago and has previously suffered a myocardial infarction. The patient was relatively active and walked without help. He arrived at the hospital with a wound on the lateral side of his right heel. A revision of the wound was performed. Two months later, an orthopaedic surgeon attended to the patient, and calcaneus osteitis was diagnosed. A trans-tibial amputation with a long posterior flap was performed. One month after the amputation, the patient was transferred from the orthopaedic clinic to the geriatric rehabilitation clinic and fitted with a PTB prosthesis. He was subsequently able to walk. Three months after the amputation, the patient was discharged from the hospital.

Case 2

A 63-year-old man, retired farmer, who has had diabetes mellitus for 20 years and a history of heart infarction. The patient was active and walked without any support. He arrived at the hospital with a necrosis on his left big toe. Three months later the entire forefoot was infected. He was treated with antibiotics but with poor results. A trans-tibial amputation with a long posterior flap was performed. One month later he was discharged to his home. He was fitted with a PTB prosthesis, and managed the rehabilitation on his own.

Case 3 and 4 (same patient, different legs)

A 57-year-old woman, retired nurse, with schizophrenia, treated with neuroleptic medicine. She had bilateral venous ulcers for three years, which caused severe pain in both feet. She requested a bilateral amputation several times. The patient could walk, but used a wheelchair because of pain. Bilateral trans-tibial amputations with long posterior flaps were performed. Postoperatively, she suffered severe stump pain and phantom pain, and was referred to a pain clinic. Thereafter, she was treated with slow release ketobemidon. After four months she was transferred to the geriatric rehabilitation clinic and bilaterally fitted with PTB prostheses, but experienced severe stump and phantom pain during training with the prostheses. A few weeks later she was, by her own request, discharged

Table 1. Stump area in per cent at different levels during the study. All figures normalised relative to the first examination.

Level Weeks	Case 1			Case 2			Case 3			Case 4		
	33	50	66	33	50	66	33	50	66	33	50	66
2	100	100	100	100	100	100	100	100	100	100	100	100
6	80	84	79	91	93	98	87	85	86	93	92	88
28	77	73	69	105	109	114	103	96	89	111	104	92

from hospital and declined from participating in gait re-education and prosthetic use.

Results

Changes in total cross-sectional area and circumference

The total cross-sectional area reduced very quickly between the first and second examination in all cases. Between the second and third examination, the area increased slightly in all cases but one. This pattern of change was recorded at all three levels (Table 1). A similar pattern was seen regarding circumference; first a decrease in circumference followed by an increase (Table 2).

The total stump length remained nearly constant during the course of the study (Table 3). A visual evaluation of the MR images showed an increased amount of subcutaneous fat during the study.

Change in cross-sectional area of different muscles (Figs. 2-5)

The individual muscles could only be evaluated at the 33% and 50% levels. At the

66% level the muscle tissue was too deranged to permit an evaluation.

The cross-sectional area of all muscles decreased quickly between the first and second examination at all levels. Between the second and third examination, however, there was a difference between the individual muscles. In most cases, the medial head of the gastrocnemius, the soleus muscle and the triceps surae decreased in area, but the lateral head of the gastrocnemius and the anterior tibial muscle showed an increase.

Discussion

The primary focus of the present study was to examine the progress of the soft tissues under the skin after amputation and subsequent prosthetic fitting. It was found that the cross-sectional area of the total stump, and the separate muscles, decreased according to two different patterns. The total stump, as well as the medial head of the gastrocnemius, the soleus muscle and the whole triceps surae complex reduced their cross-sectional area in an expected manner,

Table 2. Stump circumference in per cent at different levels during the study. All figures normalised relative to the first examination.

Level Weeks	Case 1			Case 2			Case 3			Case 4		
	33	50	66	33	50	66	33	50	66	33	50	66
2	100	100	100	100	100	100	100	100	100	100	100	100
6	90	91	88	96	96	98	94	93	93	97	69	68
28	90	86	82	103	106	110	103	99	95	107	102	97

Table 3. Stump length in centimetres during the study.

Weeks	Case 1	Case 2	Case 3	Case 4
2	12.2	14.9	14.6	15.4
6	11.8	15.2	14.2	14.8
28	11.5	15.2	13.9	13.5

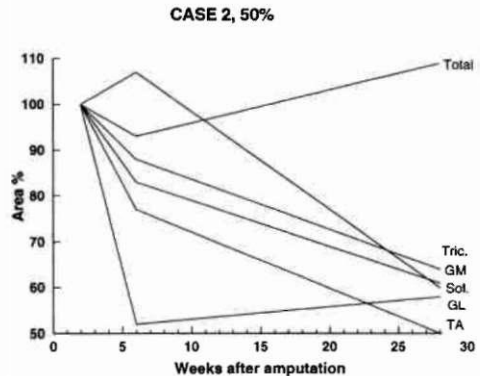
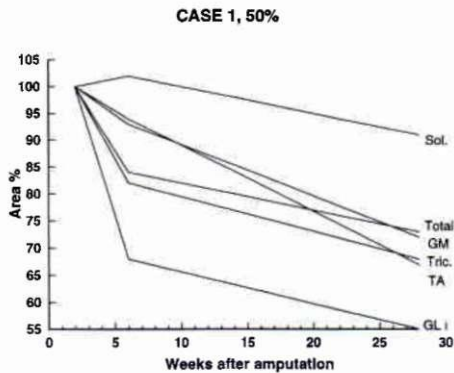
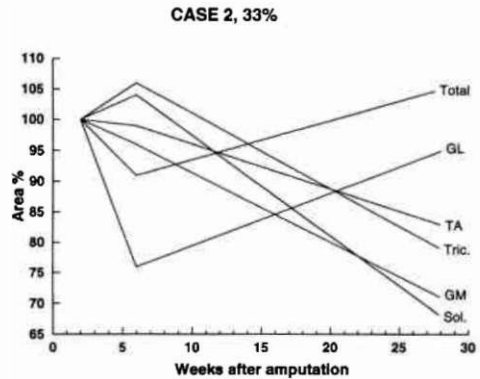
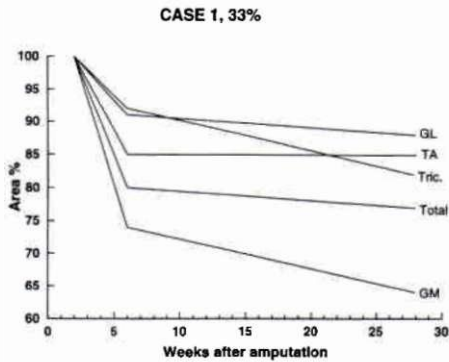


Fig. 2. Area changes in case 1. TA: anterior tibial muscle area, GL: lateral head of gastrocnemius area, GM: medial head of gastrocnemius area, Tric; triceps surae area. Sol: soleus muscle area. Total: stump area.

Fig. 3. Area changes in case 2.

i.e. a relatively rapid initial decrease in area and thereafter a slower decrease between the second and third examination. The lateral head of the gastrocnemius and the anterior tibial muscle (the lateral muscle group), however, showed a different behaviour. These two muscles initially showed a reduction in cross-sectional area between the first and second examination, and thereafter, an increase in area between the second and third examination, to a magnitude that, in some cases, was even larger than the area immediately after surgery. In some cases, the area of the triceps surae increased while the individual muscles decreased. This was due to the increased amount of fat between the muscles but still contained within the triceps surae unit.

The changes in area after amputation can be divided into two different phases, oedema reduction and muscle atrophy. As previously described by several authors, muscle trophy begins immediately after the amputation, and

continues parallel to oedema reduction during rehabilitation (Baumgartner and Langlotz, 1980; Levy, 1980; Renström *et al.*, 1983). Oedema reduction takes place mainly during the first weeks following amputation, i.e. between the first and second examination in the present study. In an earlier study, it was found that the total volume of the stump after a trans-tibial amputation decreased according to a negative power function, with an initial rapid volume reduction and later a more moderate volume reduction (Lilja and Öberg, 1997). The initial changes in volume observed in the present study did correspond to the literature and the authors' hypothesis.

For the medial muscle group the cross-sectional area changed according to this hypothesis, with a fast initial reduction followed by a slow reduction, probably reflecting a more rapid oedema reduction and a slower phase dominated by tissue atrophy. This is in full

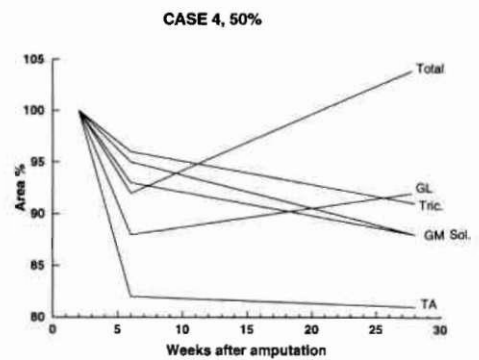
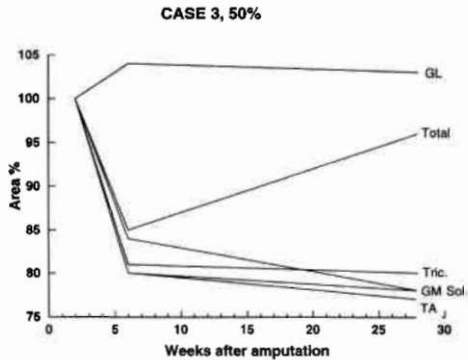
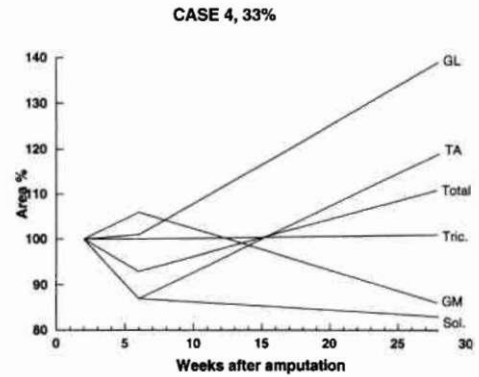
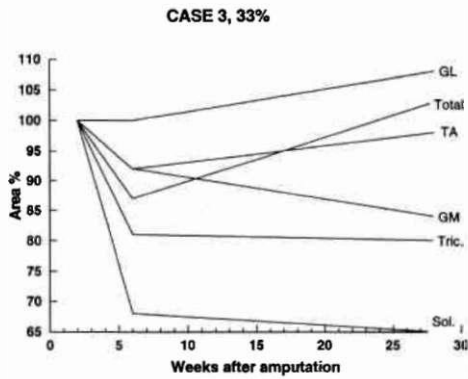


Fig. 4. Area changes in case 3.

Fig. 5. Area changes in case 4.

accordance with our earlier findings (Lilja and Öberg, 1997).

Quite unexpectedly, the lateral muscle group did not reduce in cross-sectional area according to previous studies (Lilja and Öberg, 1997; Golbranson *et al.*, 1988). After the second examination the areas increased, and in some muscles, even to a larger size than the initial value. This behaviour has not been described earlier in the prosthetic literature. However, as one study has shown, the medial and lateral heads of the gastrocnemius muscle, in healthy people, may have different functions (Ericson *et al.*, 1986). Different activity levels were observed in the two heads of the gastrocnemius, during level walking, with about 100 per cent higher EMG amplitude in the medial head compared to the lateral head. No such studies have been found involving amputees. Different activities in the two heads of the gastrocnemius muscle, may explain the different patterns observed. Grevsten and Stålberg (1975) showed that patients walking with a PTB prosthesis have

a different activation pattern of the gastrocnemius muscle compared with healthy subjects. However, they did not differentiate between the two heads of the gastrocnemius muscle, as in the study by Ericson and co-workers (1986).

Trans-tibial amputation in elderly patients – many of them in poor condition, with gangrene and peripheral vascular disease (PVD) – must be classified as major surgery. Due to both the gangrene and the operation itself, the patient enters initially, into a catabolic phase with a breakdown of muscular tissues. Within a few weeks, however, the metabolism normally changes and becomes anabolic and the patient can begin the rehabilitation and the rebuilding of his tissues. This build-up of muscle tissue, together with an increased activity level, may explain the changes in area seen in some of the individual muscles. Hedberg and co-workers (1989) found that, among trans-femoral amputees with advanced arterial insufficiency, the loss of muscle fibres in the gastrocnemius

muscle in the removed leg is about 50 per cent, compared with non-amputees. Inactivity, in combination with ischaemia, may cause the loss of many individual muscle fibres and as Hedberg and co-workers (1989) have stated, the connective tissue components were abundant.

A severe amount of fat imbibition can be seen among all cases in the present study (Fig. 6). This fat imbibition can be a result of advanced arterial insufficiency. No other presentation of fat imbibition among trans-tibial amputees have been found in the literature.

During the first six weeks after an amputation the patient can begin light physical training. After this first phase of rehabilitation the training can become more intense and the patient can start his gait re-education with a temporary/definitive prosthesis (Cutson and Bongiorno, 1996; Breakey, 1997). The physical training, together with an anabolic metabolism can stop the atrophy of activated muscles and may explain the difference in muscle area change between the second and third examination compared with the phase between the first and the second examination among the single joint muscles (except the gastrocnemius lateral head).

After a trans-tibial amputation, the anterior tibial muscle does not engage any joint and can therefore be seen as not involved in any motion. But probably, the anterior tibial muscle obtains new function: contributing to socket suspension (Burgess *et al.*, 1974). During the gait cycle the patient can, through muscle activity, increase the stump volume and thereby increase the pressure between the amputation stump and socket. The increased pressure may prevent stump movement and contribute to improved

suspension. As the patient learns how to activate the lateral muscle group at the correct time during the gait cycle, the prosthetic gait may be improved. The present study indicates a difference between the lateral and the medial muscle group in this respect. Consequently, the lateral muscle group might have adopted a new activity pattern and a new function during prosthetic fitting, i.e. contributing to the suspension of the prosthesis. Such a new activity pattern for the muscles, during prosthetic gait, may also result in hypertrophy due to training, and may explain the differences in area between the two muscle groups.

Due to the exclusive and expensive MRI technique used, the present study had to be designed as a case study. The price for one MR examination was approximately US\$ 530, and despite the limited number of patients, 17 examinations were performed. The inclusion criteria were fairly wide, and more or less all patients with a trans-tibial amputation at the orthopaedic clinic were consecutively included during a six-month period. Therefore, patients with late healing problems could not be excluded before the first examination. Due to this procedure several patients required re-amputation to the same or higher level, during the study. Only four out of eight cases completed the study. Eneroth (1997), in his thesis, found that as many as 20 per cent of all trans-tibial amputees undergo a revision or re-amputation, and that mortality after a major amputation varies between 19-40 per cent within one year after the amputation.

The levels chosen for MR images were located at 33, 50 and 66 per cent of the total length of the stump (from the knee joint to the distal end). The MR images at the 66% level were, in most cases, impossible to interpret due to a severely damaged morphology after operation with the muscles having been trimmed and no clear and identifiable muscle borders visible. Therefore, no cross-sectional areas from the 66% level were calculated. However, other studies on longer amputation stumps may show different patterns of atrophy.

The cases presented in this study were few, and did not permit statistical treatment of the findings. However, the results may indicate important changes in muscle function in the limb after trans-tibial amputation, important for further understanding of socket suspension during prosthetic gait.

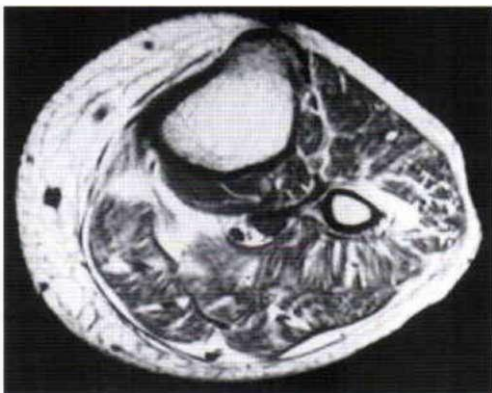


Fig. 6 Transverse MR image of case 4 at 50% level

Conclusion

This study has documented after trans-tibial amputation, severe changes in cross-sectional area of the total trans-tibial stump and of the separate muscles included in the stump. Two different patterns of change were found. The medial muscle group decreased in area according to an initial hypothesis, with a rapid decrease between the first and second examination and a more moderate decrease between the second and third examination. The lateral muscle group decreased as well, between the first and second examination, but increased in area between the second and third examination.

These two different patterns may indicate a new function of the muscles in the lateral muscle group. Activation of the lateral muscle group can be seen as a contributing factor to the suspension and fit of the prosthetic socket. These findings can be of importance for prosthetic fitting, and, together with earlier studies, indicate the importance of well-planned and functionally designed physiotherapy and prosthetic gait re-education.

Acknowledgement

This study was supported by grants from The Swedish Handicap Institute and the Scientific Committee of the Jököping County Council.

REFERENCES

- ALARANTA H, ALARANTA R, POHJOLAINEN T, KÄRKKÄINEN M (1995) Lower limb amputees in Southern Finland. *Prosthet Orthot Int* **19**, 155-158.
- BAUMGARTNER R, LANGLOTZ M (1980). Amputee stump radiology. *Prosthet Orthot Int* **4**, 97-100.
- BREAKEY JW (1997). Body image: the lower limb amputee. *J Prosthet Orthot* **9**, 58-66.
- BURGESS EM (1974). Wound healing. *Bull Prosthet Res* **10**, 109-113.
- CUTSON TM, BONGIORNI DR (1996). Rehabilitation of the lower limb amputee: a brief view. *J Geriatr Soc* **44**, 1388-1393.
- ENEROTH M (1997). Amputation for vascular disease: prognostic factors for healing, long-term outcome and costs. Thesis. -Lund: Lund University.
- ERICSON MO, NISELL R, EKHOJLM J (1986). Quantified electromyography of lower-limb muscles during level walking. *Scand J Rehabil Med* **18**, 159-163.
- GOLBRANSON FL, WIRTA RW, KUNCIR EJ, LIEBER RL, OISHI C (1988). Volume changes occurring in postoperative below-knee residual limbs. *J Rehabil Res Dev* **25**, 11-18.
- GREVSTEN S, STÅLBERG E (1975). Electromyographic study of muscular activity in the amputation stump while walking with PTB- and PTB-suction prosthesis. *Uppsala J Med Sci* **80**, 103-112.
- HEDBERG B, ANQUIST KA, HENRIKSSON-LARSEN K, SJÖSTRÖM M (1989). Fibre loss and distribution in skeletal muscle from patients with severe peripheral arterial insufficiency. *Eur J Vasc Surg* **3**, 315-322.
- JAEGERS S (1993). The morphology and function of the muscles around the hip joint after a unilateral transfemoral amputation. - Den Haag: Cip-Gegvevens Koninklijke Bibliotheek. (ISBN 90-9005982-2).
- KEGEL B, BURGESS EM, STARR TW, DALY WK (1981). Effects of isometric muscle training on residual limb volume, strength, and gait below-knee amputees. *Phys Ther* **61**, 1419-1426.
- LEVY SW (1977). Disabling skin reactions associated with stump edema. *Int J Dermatol* **16**, 122-125.
- LEVY SW (1990). Skin problems of the leg amputee. *Prosthet Orthot Int* **4**, 37-44.
- LILJA M, ÖBERG T (1997) Proper time for definitive trans-tibial prosthetic fitting. *J Prosthet Orthot* **9**, 90-95.
- MACLEAN N, FICK GH (1994). The effect of semirigid dressings on below-knee amputations. *Phys Ther* **74**, 668-673.
- MANELLA KJ (1981). Comparing the effectiveness of elastic bandages and shrinker socks for lower extremity amputees. *Phys Ther* **61**, 334-337.
- MCWHINNIE DL, GORDON AC, COLLIN J, GRAY DW, MORRISON JD (1994). Rehabilitation outcome five years after 100 lower-limb amputations. *Br J Surg* **81**, 1596-1599.
- RENTRÖM P, GRMBY G, MORELLI B, PALMERTZ B (1983). Thigh muscle atrophy in below-knee amputees. *Scand J Rehabil Med (Suppl)* **No.9**, 150-162.