

Clinical comment

Psychological factors leading to amputations in adults

G. A. HUNTER

*Division of Orthopaedic Surgery
Sunnybrook Health Science Centre, Canada*

Abstract

Psychological factors may lead to a small number of amputations in adults. They may be classified as being due to:

1. chronic pain syndrome;
2. artefactualists;
3. self-mutilation;
4. attempted murder.

An understanding of these potential factors will make the amputee clinic team aware of this problem, and help them deal with the rehabilitation of the patient.

Introduction

It is common knowledge that loss of a limb or limbs will lead to psychological problems, including the sequelae of grief or serious illness, i.e., denial, anger, blame, adjustment and acceptance.

Experience over the years, however, has taught the author that there are a number of psychological and environmental factors which may lead to a small number of patients being treated by amputation of a limb or limbs in adults. Hunter *et al.* (1982) reported on "mania operativa; an uncommon, unrecognised cause of limb amputation", and Hunter (1985) discussed in this journal "limb amputation and re-amputation in association with chronic pain syndrome".

With the exception of the S-H-A-F-T syndrome described by Wallace *et al.* (1978), (SAD, HOSTILE, ANXIOUS, FRUSTRATING PATIENTS who tenaciously cling to the Health Care System), there is little information on this topic in the English-

speaking literature relating to amputation surgery.

Informal discussions with colleagues lead to the suspicion that this problem is not uncommon; for this reason, it is emphasised that the amputee clinic team should be made aware of the potential problems, so that they are in a better position to help in the rehabilitation of the patient.

Classification

The author has attempted to classify these psychological factors leading to amputation (and often re-amputation) as they may present to the clinicians concerned with the care of the amputee.

Chronic pain syndrome

A relatively minor soft tissue or bone injury to the hand or foot, but commonly to the knee joint, will be followed by intensive investigations, and multiple surgical procedures, culminating in amputation of the upper or lower limb at increasingly higher levels in an unsuccessful attempt to relieve the patient's pain (Fig. 1).

Soon after the injury, there may be a prolonged and unrecognised period of reflex sympathetic dystrophy, which will contribute to the patient's ongoing disability. The patient may previously have exhibited sociopathic tendencies, and there may be ongoing drug and alcohol-related problems. It is believed that this condition merits a positive diagnosis of mania operativa, i.e. an obsession with pain and disability and the seeking of relief from this pain by repeated surgical procedures, in these cases, amputation and re-amputation of the upper or lower limb.

All correspondence to be addressed to Dr. G. A. Hunter, A-315 Sunnybrook Health Science Centre, 2075 Bayview Avenue, North York, Ontario M4N 3M5, Canada

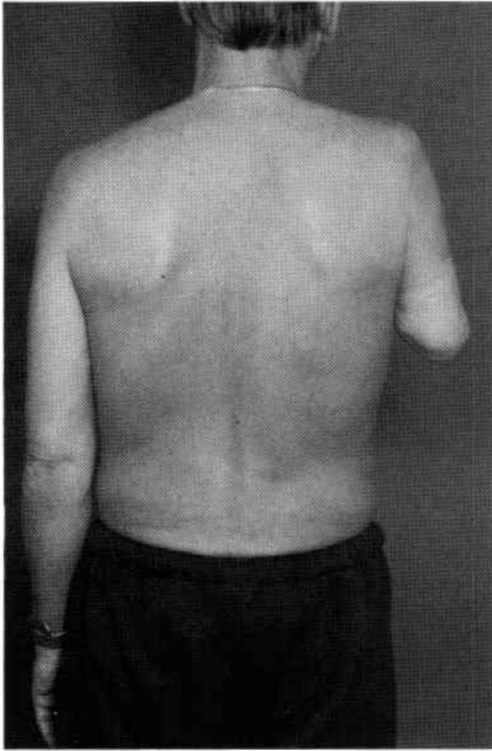


Fig. 1. Above-elbow amputation following minor injury to little finger and leading to multiple reamputations in an attempt to relieve pain.

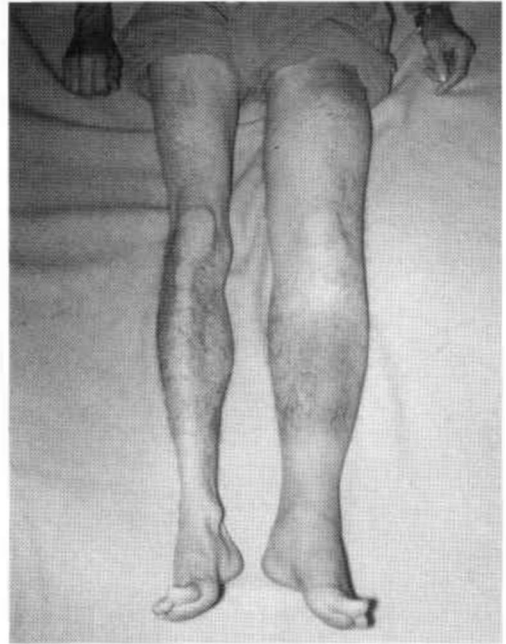


Fig. 2. Self-induced lymphoedema of left leg following use of tight bandages.

Artefactualists

Such patients will present to the clinician requesting an amputation because of sinuses, fistulae and ulcers or surgical incisions which fail to heal with standard measures; self-induced lymphoedema of the arm or leg may be caused by the use of constricting rubber bands, bandages or tourniquets (Fig. 2). The patient and the family usually deny any element of self-inflicted disease.

"Hand clenchers" should also be included in this group because poor hygiene may lead to ulceration, infection of the hand and a request for amputation (Fig. 3). Bayliss (1984) stated that dermatitis artefacta was a major problem, and may be the cause, incomprehensible to the doctor, of the amputation of fingers, a hand or an arm.

Self-mutilation

Examples of self-mutilation seen over the years, include continued smoking, even after the loss of almost four limbs (Fig. 4), neglect of

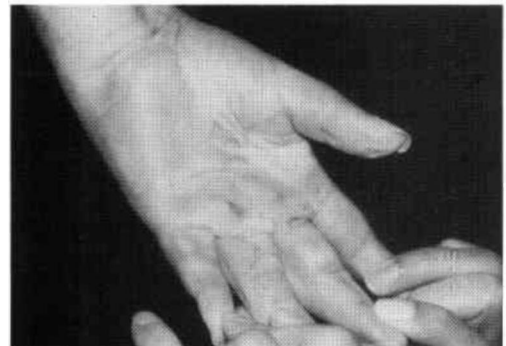
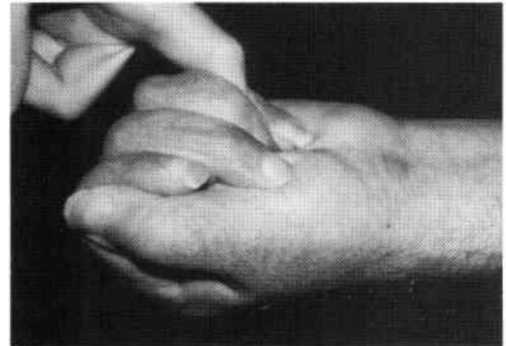
Fig. 3. "Clenched hand" which required general anaesthesia to reveal deformity.

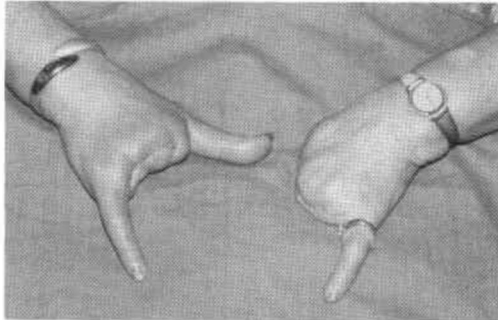
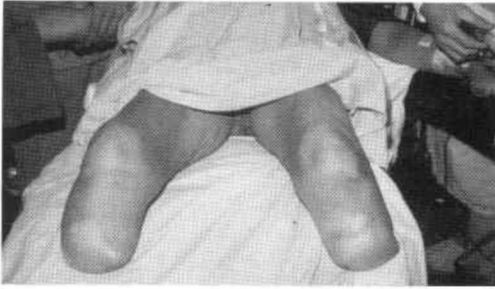

Fig. 4. Heavy smoker with severe peripheral vascular disease.

neuropathic foot ulcers, especially in the diabetic population and inadvertant self-intra-arterial injection of narcotic drugs (Fig. 5).

Alcohol and drugs are often major aetiological factors in motor vehicle accidents, bridge and subway jumping accidents and failed suicide attempts. If lucky, these so-called

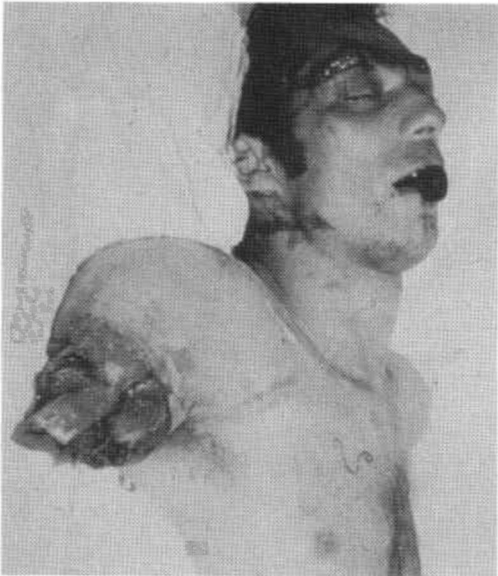

Fig. 5. Loss of arm after self intra-arterial injection of narcotic drugs.

“accidents” result in a survivor, who is an amputee, but who still has pre-existing and ongoing psychological problems.

Over a three year period between 1986 and 1989, 854 patients admitted to the Regional Trauma Unit at Sunnybrook Health Science Centre were examined for evidence of alcohol and drug ingestion. Close to 60% were found to test positive for alcohol and/or other drugs. One year after the accident, the same alcohol-positive group exhibited depression, family stress, anxiety and financial problems (McLellan, 1991: Personal Communication).

The writer has become morbidly suspicious about the relationship between psychological problems and train accidents, resulting in childhood and adult amputations. Shapiro *et al.* (1981) concluded from a review of nine adults who suffered amputation of a limb from a train accident, that the victim must be impaired by drugs, alcohol, medication or by suicidal ideas (Fig. 6).

Attempted murder

We live in a violent society and when combined with easy access to weapons, cultism,

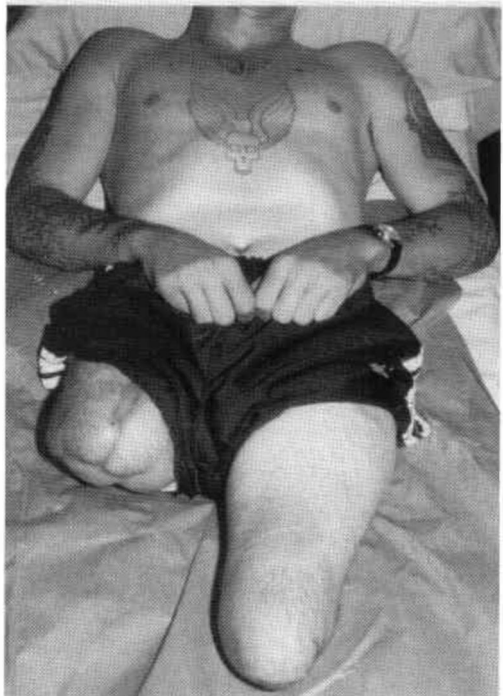


Fig. 6. Result of train accident in a suicidal patient following heavy ingestion of drugs and alcohol.

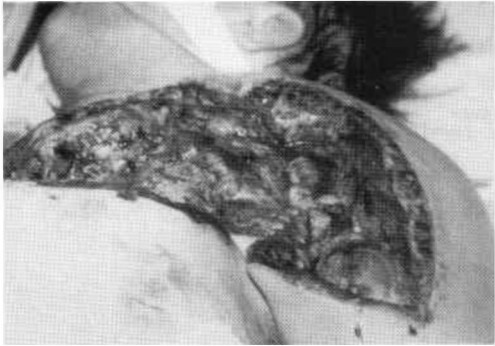

Fig. 7. Shoulder disarticulation resulted from this attempted murder with a shot-gun after a domestic dispute.

ingestion of drugs and/or alcohol and estranged family relationships, amputation of one or more limbs may result (Fig. 7.) The patient may survive the attack but limb amputation after death has been used to avoid recognition of the dead person. For various reasons, the unfortunate patient may ignore the accident or attempt to hide the identity of the assailant.

The significance of the "accident" may not be realised until exposure to the police and the court system forces the amputee clinic team to attempt total rehabilitation of the patient under the most adverse circumstances.

REFERENCES

- BAYLISS RIS (1984). The deceivers (editorial). *Br Med J* **25** February, 583-584.
- HUNTER GA, KENNARD AB (1982). Mania operativa: an uncommon, unrecognized cause of limb amputation. *Can J Surg* **25**, 92-93.
- HUNTER GA (1985). Limb amputation and re-amputation in association with chronic pain syndrome. *Prosthet Orthot Int* **9**, 92-94.
- SHAPIRO D, ROOT BC (1987). Premorbid psychological behaviour in adult train track amputees. In: Proceedings of the International Seminar on Traumatic Amputations, Herzlia Sept 6-11 1987, Israel./edited by Stein H, Steinbach T. - Copenhagen: IPSO. p41
- WALLACE PF, FITZMORRIS CS (1978). The S-H-A-F-T syndrome in the upper extremity. *J Hand Surg* **3**, 492-494.