

## Technical note

# Splinting for CDH—initial impressions of a ‘user-friendly’ alternative

R. N. VILLAR, P. M. SCOTT and A. RONEN

*Department of Orthopaedic Surgery, Addenbrooke's Hospital, Cambridge*

### Abstract

A lightweight, washable, and easily adjusted splint for the congenitally dislocated hip, designed to improve maternal compliance, is described. Observations are currently scientifically uncontrolled, though initial impressions are favourable.

### Introduction

The treatment of congenital dislocation of the hip (CDH) in the newborn is an emotive subject, meeting with as many different ideas as there are surgeons treating it. Some elect to use splintage at an early stage (Fredensborg, 1976; Dunn et al, 1985; Visser, 1985) whilst others adopt a more relaxed approach, feeling that splintage may damage the capital epiphysis (Ilfeld and Makin, 1977) and that many unstable hips may stabilize without any treatment at all (Palmen, 1984). The choice of splints, if splintage is adopted, is diverse in the extreme (Heikkila and Ryoppy, 1984; Klisic et al, 1984; von Rosen, 1962; Sahlstrand et al, 1985; Ramsey et al, 1976; Wiersma 1976), the aim being to maintain the hip in sufficient abduction to prevent redislocation but not so widely abducted that avascular necrosis is the result. The length of time the appliance stays in place can vary from several weeks (Hadlow, 1979) to many months (Dunn, 1985; Ilfeld and Makin, 1977).

The authors have found, over several years of treating the unstable hip in their unit, that maternal compliance is a vital factor governing the success of a splint. A device that is cosmetically ugly, difficult to clean, and inter-

feres with nappy-changing, ensures frequent visits by disgruntled parents to an overloaded clinic. This ‘user-friendly’ abduction splint devised with both mother and baby in mind is therefore presented.

### Description of the device

The splint comprises a semi-circular metal waistband connected to two leg pieces by L-shaped metal bars (Fig. 1). All metal

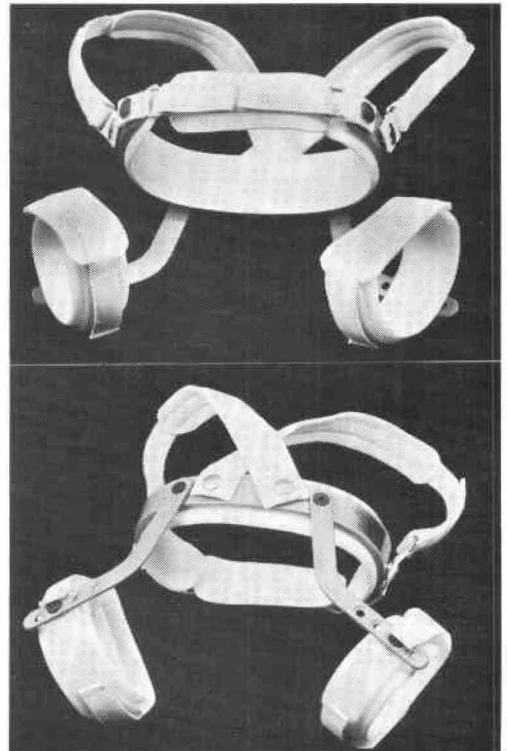


Fig. 1. Top, the abduction splint from the front. Bottom, the abduction splint from behind demonstrating the Allen nut adjustment mechanism.

All correspondence to be addressed to Mr. R. N. Villar, Senior Orthopaedic Registrar, Addenbrooke's Hospital, Hills Road, Cambridge, CB2 2QQ. United Kingdom.

attachments are lined by removable (and washable) liners. Straps are broad to prevent them from cutting into the baby. Each leg piece is connected to the back of the waistband by one Allen nut to allow adjustment to the precise splintage position required. Though the splint is provided in different sizes, all its components are detachable and it is thus possible to adapt any splint to fit a baby of any size. It has been found that babies with large waists do not necessarily have large thighs, and vice versa. Shoulder straps are also available if required. Mothers frequently request a second set of liners to act as a reserve and are now provided with these as routine so that the splint can avoid that much-used appearance that only babies can produce. These is no need to remove the splint if the liners need to be changed and nappy-changing is simple.

The device has now been used for a year with 20 patients completing treatment. All hips remain reduced and no instances of avascular necrosis have been recorded. However, this experience is currently uncontrolled and a longer-term controlled study is underway. At present however, the mothers involved are



Fig. 2. The "occasional cuddle".

understandably enthusiastic that, given the constraints of splintage in the first place, the device is light, comfortable and hygienic, even permitting the occasional cuddle (Fig. 2). On such a basis it is felt that it can be strongly recommended to others as a 'user-friendly' alternative.

#### Acknowledgement

The authors are grateful to Cumbria Orthopaedic Ltd, London, for providing the necessary splints.

#### REFERENCES

- DUNN, P. M., EVANS, R. E., THEARLE, M., GRIFFITHS, H. E., WITHEROW, P. J. (1985). Congenital dislocation of the hip: early and late diagnosis and management compared. *Arch. Dis. Child.* **60**, 407-14.
- FREDENSBORG, N. (1976). The results of early treatment of typical congenital dislocation of the hip in Malmo. *J. Bone Joint Surg.* **58B**, 272-8.
- HADLOW, V. D. (1979). Congenital dislocation of the hip over a ten-year period. *N.Z. Med. J.* **89**, 126-8.
- HEIKKILA, E., RYOPPY, S. (1984). Treatment of congenital dislocation of the hip after neonatal diagnosis. *Acta Orthop. Scand.* **55**, 130-4.
- ILFELD, F. W., MAKIN, M. (1977). Damage to the capital femoral epiphysis due to Frejka pillow treatment. *J. Bone Joint Surg.* **59A**, 654-8.
- KLISIC, P., RAKIC, D., PAJIC, D. (1984). Triple prevention of congenital dislocation of the hip. *J. Pediatr. Orthop.* **4**, 759-61.
- PALMEN, K. (1984). Prevention of congenital dislocation of the hip. The Swedish experience of neonatal hip joint instability. *Acta Orthop. Scand.* **55**, (suppl.), 208, 1-107.
- RAMSEY, P. L., LASSER, S., MACEWEN, G. D. (1976). Congenital dislocation of the hip. *J. Bone Joint S.* **58A**, 1000-4.
- SAHLSTRAND, T., MALMGREN, N., AHLGREN, S. A., HELGASON, H., NILSSON, J. (1985). Management of neonatal hip instability: an analysis of the efficiency in a consistent treatment programme. *J. Pediatr. Orthop.* **5**, 540-5.
- VISSER J. D. (1985). Dynamic splint for treatment of congenital dysplasia of the hip. *J. Pediatr. Orthop.* **5**, 85-8.
- ROSEN, S. VON (1962). Diagnosis and treatment of congenital dislocation of the hip joint in the newborn. *J. Bone Joint Surg.* **44B**, 284-91.
- WIERSMA, J. A. (1976). Use of the Pavlik splint in the treatment of congenital dysplasia and dislocation of the hip in the newborn. *J. Am. Osteopath. Assoc.* **76**, 119-21.