

Abnormal extension of the big toe as a cause of ulceration in diabetic feet

K. LARSEN and P. HOLSTEIN

Steno Memorial Hospital, Gentofte, Copenhagen

Abstract

Relief from external pressure and repetitive stress is a main concept in treating diabetic neuropathic ulcers. Ulcers on the tip of the big toe may be caused by abnormal extension of the big toe, which can be diagnosed only by observing the patient during barefoot walking. A flexor pad underneath the big toe eliminates the phenomenon, but in case of rigidity of the toe, extremely roomy toe boxes must be prescribed. Out of a series of 272 diabetic patients with skin lesions on the feet 18 suffered this phenomenon, in one case with bilateral ulcerations. Fifteen ulcers healed and below the knee amputation had to be carried out in 4 legs due to ischaemia.

Introduction

The degree and duration of the extension of the toes during walking is, like the walking pattern itself, highly individual (Saunders et al, 1953). The authors have observed that problems from the big toe may be ascribed to excessive and constant extension during walking found in some patients. The phenomenon stresses the tip of the toe as it repeatedly bumps against the upper of the shoe. In patients with peripheral neuropathy, e.g. diabetics, there is a high risk of ulceration. In case of occlusive arterial disease, gangrene of the toe may be initiated (Fig. 1, top). A callosity on the tip of the toe or under the rim of the nail indicates the occurrence of stress and will precede ulceration or necrosis of the skin.

The phenomenon of abnormal extension can be diagnosed only by observing the patient during barefoot walking. A normal pattern of walking implies that the big toe is slightly extended during swingphase and at heelstrike.

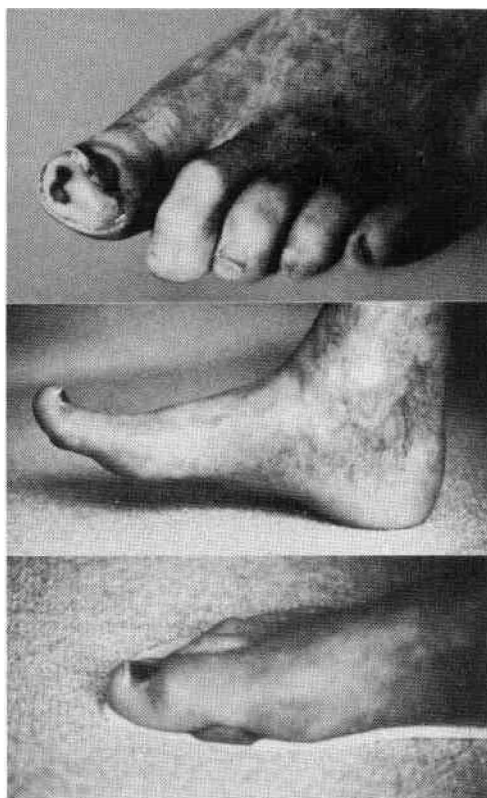


Fig. 1. Top, skin necrosis of the tip of the big toe. Centre, abnormal extension of the big toe at heel strike. Bottom, flexor pad placed underneath the big toe causing flexion of the interphalangeal joint.

Abnormal extension is easily recognized as the big toe is markedly extended during the whole walking cycle. (Fig. 1, centre). The phenomenon is usually bilateral and connected with cavus foot deformity.

Compensation for the abnormality can be provided by hand made shoes with extremely roomy toe-boxes. Another solution is a "flexor-pad" which consists of a soft bar, about 5 to 6 mm in height placed under the first phalanx of

All correspondence to be addressed to Ms. K. Larsen, Kollelevbakken 14, DK-2830, Virum, Denmark.

the big toe and transversely to its longitudinal axis (Fig. 1, bottom). This bar will cause the big toe to be slightly flexed during heel rise and push-off. It is a condition for employing a flexor pad that the flexor hallucis longus muscle and the joints of the hallux are mobile.

Patients and methods

During a 3 years period (01.12.79 to 30.11.82) 272 diabetic patients with skin lesions on the feet were treated. The clinical examination included an evaluation of the foot as regards function of the joints and muscles; the pattern of walking; peripheral neuropathy and arterial supply as well as an examination of the shoes with special attention to the roominess of the toe caps. Eighteen patients (7%) had ulcers on the tip of the big toe, in one case on both feet, caused by abnormal functional extension. The patients were supplied with insoles made from soft materials using functional imprints (Holstein et al, 1976; Larsen et al, 1982). In 13 patients flexor pads were placed underneath the big toes. In three cases hand-made shoes with extremely roomy toe-boxes were prescribed. This treatment was chosen because of hallux rigidus in two of the patients and because of paralysis of the flexor hallucis muscle in the third patient. In the last two patients no local treatment was given because the lesions developed into frank gangrene.

Results

The duration of the treatment period averaged 3 months (range 1 to 10 months) and 15 out of the 19 ulcers healed. In the four other legs a below-knee amputation became necessary. In these cases the systolic ankle and toe pressures demonstrated severe ischaemia. The legs in which the big toe lesions healed were followed up for on average 30 months (range 6 to 47 months). None of the skin lesions on the tip of the big toes recurred. Four patients died and three legs were amputated. The cause of amputation was progressive occlusive arterial disease resulting in heel necrosis in one leg and heel necrosis in combination with gangrene of more than one toe in the other two legs.

Discussion

Abnormal extension of the big toe during walking as a cause of ulceration of the tip of the big toe is not described in current text-books. Reumert (1976) has described abnormal extension as a cause of unguis incarnatus in

non-diabetic patients, and has recommended treatment with a flexor pad as a supplement to nail braces.

In diabetic patients the extension phenomenon is probably related to the presence of peripheral neuropathy. It is well known that weakness of the intrinsic musculature of the foot predisposes to claw-toe deformity (Wagner, 1981). In patients with big toe extension the clinical examination suggests weakness of the peroneal muscles compensated during walking by dorsiflexion of the foot by means of the long extensor muscles, especially the extensor hallucis longus muscle. The subsequent extension of the big toe is then a risk due to the neuropathic sensory loss. The phenomenon is easily overlooked unless observation of barefoot walking is included in the clinical examination. Treatment with the flexor pad, or in case of rigidity with extremely roomy toe caps has proved successful in cases where the blood supply is adequate for healing. In theory there is a risk of pressure ulcer underneath the big toe due to the flexor pad but the authors have not so far encountered such cases.

In the four legs which had to be amputated primarily the pressure lesions developed into gangrene. This demonstrates the risk of the abnormal extension especially in case of ischaemia. The presence of a skin lesion on a diabetic foot always requires a careful analysis of the pathomechanism. Correction for abnormal extension of the big toe must be part of the armamentarium in the relief of intolerable local external pressure and stress to the neuropathic foot.

REFERENCES

- HOLSTEIN, P., LARSEN, K., SAGER, P. (1976). Decompression with the aid of insoles in the treatment of diabetic neuropathic ulcers. *Acta Orthop. Scand.* **47**, 463-468.
- LARSEN, K., CHRISTIANSEN, J. S., EBSKOV, B. (1982). Prevention and treatment of ulcerations of the foot in unilaterally amputated diabetic patients. *Acta Orthop. Scand.* **53**, 481-485.
- REUMERT, L. N. (1976). Unguis incarnatus hallucis. *Fodterapeuten* 124-127.
- SAUNDERS, J. B. de C.M., INMAN, V. T., EBERHARDT, H. D. (1953). The major determinants in normal and pathological gait. *J. Bone Joint Surg.* **35A**, 543-558.
- WAGNER, F. W. JR. (1981). The dysvascular foot: A system for diagnosis and treatment. *Foot and Ankle* **2**, 64-122.