

“Zero-position” functional shoulder orthosis

J. OZAKI and I. KAWAMURA*

*Department of Orthopaedic Surgery, Nara Medical University, *Kawamura Orthopaedic Appliance, Co. Ltd.*

Abstract

The “zero-position” of the shoulder joint described by Saha (1961) is recognized as a mechanical position between scapula and humerus, and the “scapular plane” is widely accepted as a mechanical plane at the shoulder joint. On the basis of biomechanical concepts of the “zero-position” and the “scapular plane”, the authors designed the “zero-position” functional shoulder orthosis. This orthosis has been successfully fitted to more than 75 patients for the postoperative management of rotator cuff injuries, and to 3 patients for the treatment of scapular neck fractures. It is introduced here, together with biomechanical considerations, structure, functional and clinical results.

Introduction

A plaster cast has commonly been used for immobilization in the so-called optimal position of the shoulder joint after operation for rotator cuff injuries. However, it sometimes causes contracture of the shoulder joint and muscle imbalance around the shoulder girdle because, in such cast immobilization, patients cannot exercise their shoulder postoperatively. From this point of view, the authors initially used a “zero-position” plaster cast in the postoperative management of rotator cuff injuries (Ozaki and Nobuhara, 1978). On the other hand, however, some difficulties were found after the removal of the plaster cast in that almost all the patients complained of pain and could not continue with their exercises. This resulted in prolongation of the healing period. It was thought that if a functional shoulder orthosis were adopted it would enable adjustments to be made to the

elevation angle from the “zero-position” step by step, thus producing less pain. This is the reason for the design of this functional shoulder orthosis.

Biomechanical considerations

The shoulder joint consists of the small and shallow scapular glenoid fossa, the large humeral head, and abundant muscles. These structures give the shoulder joint the widest range of motion and the most varied movements of any joint in the human body. Therefore the shoulder mechanism has been an enigma to the anatomist. Codman (1934), and others demonstrated that whether the arm is elevated to the vertical in the saggital, the coronal, or in any other plane, the end result is always the same, and when the arm is elevated to the vertical in the coronal plane, it undergoes an appreciable degree of lateral rotation during the process. According to Johnston (1937), when the arm is raised to the vertical, no matter how many planes it may move through in the process, at the end of the movement the humerus must lie in the “plane of the scapula”. He stated that the “plane of the scapula” is not easy to define, but may be regarded as a plane drawn at right angles to the glenoid cavity through its greatest vertical diameter. On the other hand, Codman (1934) pointed out a very natural position for the human arm when the body is recumbent. In this position, the axis of the humerus is in line with the axis of the spine of the scapula, and the head and neck of the humerus is in the same plane. He called this point a subordinate pivotal position in which the deltoid, the supraspinatus and the infraspinatus are relaxed. It is the most favourable position to encourage physical repair of lesions in and about the tuberosity. However, he never actually used this position for treatment. Saha (1961) has designated this point

All correspondence to be addressed to Dr. J. Ozaki, Department of Orthopaedic Surgery, Nara Medical University, Kashihara, Nara 634, Japan.

as the "zero-position", because muscular rotatory forces acting upon the humerus at this position are almost zero. He stated that this position of stability can be seen in fast-moving quadrupeds. According to Saha's observations, the "zero-position" is at about 155° of elevation from the anatomical position, with the axis of the humerus about 45° anterior to the coronal plane. He used this position in the reduction of fractures of the humerus and dislocations of the shoulder. However, this position had never been used for the postoperative treatment of rotator cuff injuries. In order to define the "plane of the scapula", Ozaki (1980) performed cineradiographic and radiographic studies on normal and disordered shoulders. He demonstrated that the "scapular plane" should be inclined forward at an angle of 30° to 45° to the frontal plane (Fig. 1), and that in the "zero-position", the humerus must be elevated to 150° in the "scapular plane" with individual variations (Fig. 2). On the basis of these biomechanical concepts, the functional shoulder orthosis, introduced in this paper, was designed.

The design of the orthosis

The "zero-position" functional shoulder orthosis is shown in Figure 3. It consists of a pelvic girdle, an upright bar, a transverse cross bar, and an arm. The pelvic girdle is made of 4mm Subortholen plastic sheet.

The length of the upright bar can be changed since the distance from axilla to iliac crest varies according to the angles of elevation of the arm, and can be rotated in the horizontal plane and fixed in any position using two mechanical joints. The distance from axilla to elbow joint and from palm to forearm can be changed as

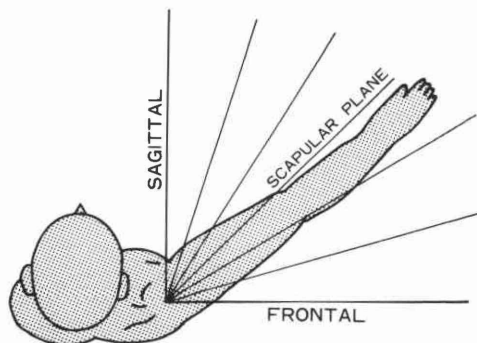


Fig. 1. The "scapular plane".

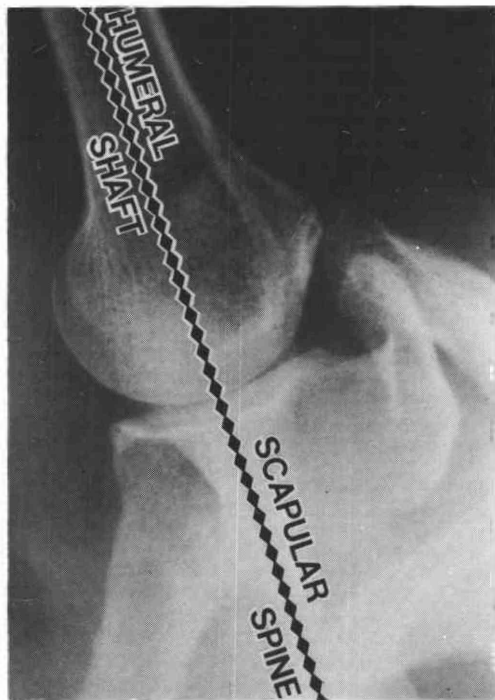


Fig. 2. Radiograph showing the normal shoulder joint in the "zero-position". The "zero-position" is at about 150° of elevation in the "scapular plane", and the axis of the humerus is in line with the axis of the scapular spine.

required. Furthermore, the angle of rotation of the humeral axis and the forearm can be changed easily with the two mechanical joints.

Clinical applications

Postoperative management of rotator cuff injuries

Immediately after the successful repair of a rotator cuff injury, the "zero-position" of the shoulder should be maintained by skin traction while the patient rests in bed (Fig. 4). After three days, a functional shoulder orthosis, which has been made to order preoperatively, is applied to maintain the "zero-position" in the scapular plane. At the beginning of the third postoperative week, the upper limb in the orthosis is extended at 100° abduction in the "scapular plane" and the patient is allowed to start gradual active-assisted abduction exercises of the arm. From the fourth to the sixth week, when the patient is able to perform active elevation in the range of 60° to 150° , the abduction angle of the orthosis can be decreased

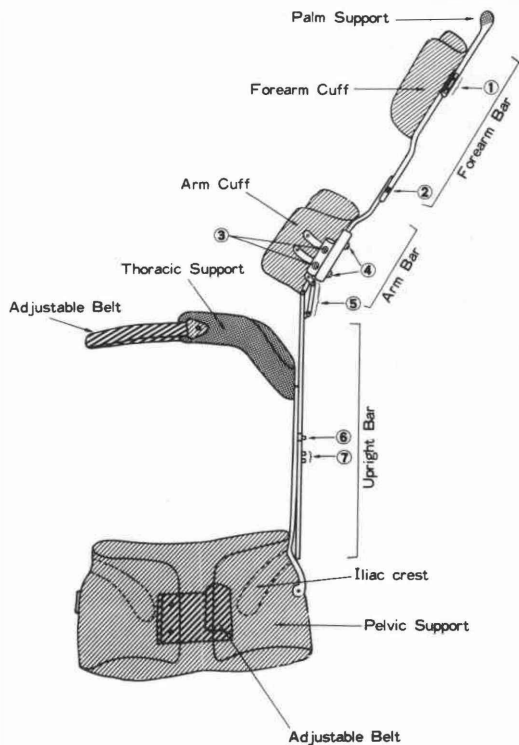
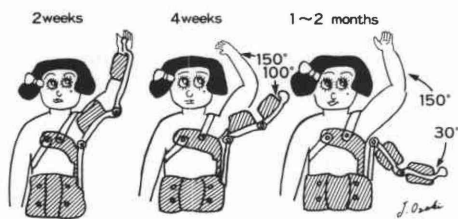
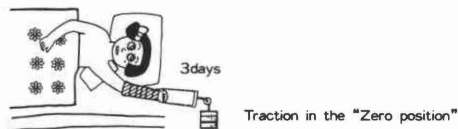


Fig. 3. "Zero-position" functional shoulder orthosis.

gradually to 30°. Mass movement exercise involving circular motion is indicated. Two to three months after surgery, the orthosis is removed. At this point the patient is able to use a full range of elevation, and after three to six

months, the patient will have made maximum recovery.

For the postoperative management of rotator cuff injuries, this orthosis has been fitted to more than 75 patients. As a result of being able gradually to decrease the elevation angle from the "zero-position", pain was reduced compared to that suffered by patients of the plaster cast group in the "zero-position". Early healing and excellent results occurred in almost all cases.



POSTOPERATIVE MANAGEMENT

Fig. 4. Postoperative management of rotator cuff injuries using a "zero-position" functional shoulder orthosis.

Fractures of the scapular neck

Almost all cases of scapular fracture tend to be neglected because of their complications such as haemothorax, pneumothorax, and other associated multiple fractures. Moreover, immobilization of the fracture of the scapular neck has been done with a sling or a Velveau bandage, but this cannot reduce the displaced fracture successfully, and sometimes causes contracture of the shoulder joint. Therefore, on the basis of the scapular mooring muscle network, the authors have been using the "zero-position" in the reduction of scapular neck

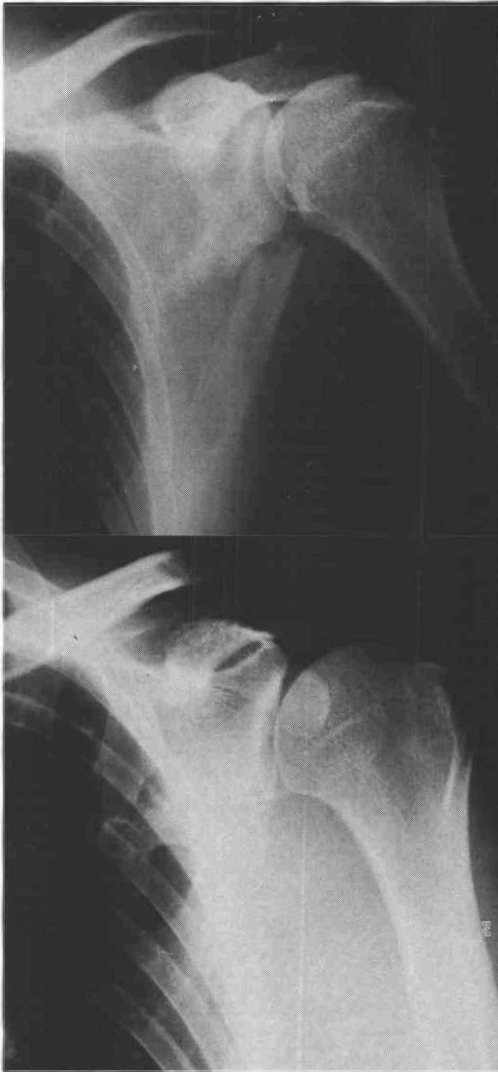

Fig. 5. Top, anteroposterior view shows a fracture of the scapular neck in a 50 year old man. Note the marked angulation of the scapular neck. Bottom, the reduction after 10 weeks in "zero-position" traction and fixation by a functional shoulder orthosis. The result was excellent.

fractures to prevent the consequent shoulder contracture and mooring muscular imbalance.

After the injury, traction in the "zero-position" should be maintained whenever severe complications exist. After relief from the complications, a functional shoulder orthosis is

applied to maintain the "zero-position" in the "scapular plane". From four to six weeks after injury, the elevation angle of the upper limb in the orthosis in the "scapular plane" can be decreased gradually from the "zero-position", and the patient is allowed to start active abduction exercise of the arm. Six to ten weeks after injury, the orthosis is removed, and circular motion exercise is indicated. Three patients have been fitted with this orthosis for the treatment of scapular neck fractures, and their clinical results were excellent. Radiographs of a representative case are presented in Figure 5.

Conclusion

The "zero-position" functional shoulder orthosis has been successfully applied for the postoperative management of rotator cuff injuries and for the treatment of scapular neck fractures. Clinical trials of this orthosis can also be extended to the postoperative management of other shoulder conditions. In the cases of recurrent shoulder dislocation, post-traumatic shoulder dislocation, and inferior and multidirectional instability of the shoulder, this orthosis should not be used to immobilize at the "zero-position". In these cases glenohumeral dislocation may frequently be encountered due to their original glenohumeral instability as in Bankart, or Hill-Sacks lesions, and glenoid dysplasia.

REFERENCES

- CODMAN, E. A. (1934). *The shoulder*. Boston, T. Todd.
- JOHNSTON, T. B. (1937). Movements of the shoulder joint: a plea for the use the "plane of the scapula" as the plane of reference for movements occurring at the humero-scapular joint. *Br. J. Surg.*, **25**, 252-260.
- OZAKI, J., NOBUHARA, K. (1978). Postoperative management of rotator cuff injuries. *Seikeigeka Mook*, **4**, 109-116, (Japanese).
- OZAKI, J. (1980). Shoulder mechanism: a study based on cineradiography and radiography with the arm elevated. *Nippon Seikeigeka Gakkai Zasshi*, **54**, 1679-1692, (Japanese).
- SAHA, A. K. (1961). *Theory of shoulder mechanism: descriptive and applied*. Springfield, C. C. Thomas.