

Operative technique in knee disarticulation

K. JANSEN and J. STEEN JENSEN

Department of Orthopaedic Surgery T-2, Gentofte Hospital, Copenhagen.

Abstract

The operative technique is described in detail. Pitfalls are emphasized and comparisons made with other techniques.

Introduction

Interest in the through-knee (TK) amputation was created during a visit to the headquarters of Col. Maurice Fletcher at the Walter Reed Hospital in Washington DC in 1953, where they were considering a combination with quadricepscine-plasty.

The traditional Spittler approach with a large anterior flap was used in Copenhagen until Kjølbye (1970) suggested the use of two side flaps. In arteriosclerotics this technique provided flaps with a safer blood supply. This technique has been routinely used in Gentofte.

Operative technique

The surgical technique is a minor procedure as little soft tissue is divided. The level is determined essentially by determination of the blood flow, measured by the Holstein technique (Holstein and Lassen 1973) and of course by the clinical findings such as skin or bone disorder or a severe knee joint contracture.

Primarily a circular skin incision (Fig. 1) and preparation of two square flaps are performed. The final trimming of the skin is delayed until wound closure. The patellar tendon, the collateral ligaments and the tendon of the hamstrings are detached. After a broad transverse capsulotomy the joint is widely exposed. Next the cruciate ligaments are divided

at their distal attachments. After division of the posterior capsule, the gastrocnemius are divided 2 cm below joint level in order not to sacrifice the superior genicular artery.

The vessels are ligated at joint level and the tibial and peroneal nerves are isolated, pulled down gently, ligated and divided. The ligature of the nerves in amputation surgery serves to create a circumscribed neuroma, which is easier to identify and handle than dendritic neuromas in cases of re-operation for pain caused by post-amputation neuroma.

After removal of the menisci, the patellar tendon and the hamstring tendons are stitched to the cruciate ligaments and the capsular brim. Proper tension of the sutures is emphasized. The correct placement of the knee cap is of utmost importance as the apex of the patella must never reach below the condylar level (Fig. 2). Ideal positioning leads to a triangular stump end consisting of the two condyles and the apex patellae. The final shaping of the gastrocnemius heads is undertaken to cover the posterior part of the joint cartilage.

An intra-articular suction drain is inserted through a separate incision and the wound is sutured after trimming the skin flaps. Subcutaneous interrupted sutures are

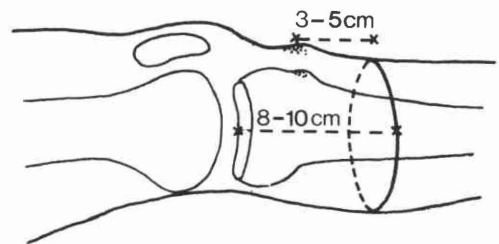


Fig. 1. Circular incision 3-5 cm below tibial tuberosity or 8-10 cm below level of knee joint.

All correspondence to be addressed to Dr. J. Steen Jensen, Department of Orthopaedic Surgery U, Rigshospitalet, University of Copenhagen, DK-2100 Copenhagen Q, Denmark.

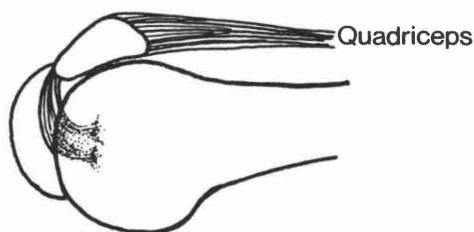


Fig. 2. Lig. patellae sutured to cruciates bringing the apex of the patella level with the femoral condyles.

recommended using an absorbable material such as polyglycol acid. Interrupted atraumatic nylon sutures, or other monofilament non-absorbable materials, are recommended with close adaptation of the skin edges. The wound has to be treated as all other operation wounds. There is no reason for using few, deep interrupted sutures, as the destiny of the wound is dependent on the blood supply.

In vascular cases the skin sutures are removed after three weeks as a rule, but after normal healing in others. The postoperative dressing consists of an elastic bandage or a plaster of Paris, which has to be changed after one week to inspect the wound.

Discussion

The predominant disadvantage of the TK amputation is the cosmesis, as the protruding knee joint of the prosthesis is less acceptable, especially in women.

The advantages, however, greatly exceed the cosmetic problem and are listed in Table 1.

The majority of the advantages are related to the prosthetic fitting procedures as will be described in other papers of this issue. It is, however, well known that weight-bearing stumps lead to better comfort and improved prosthetic fitting. The architecture of the TK stump provides a triangular stump profile thus distributing the pressure at the stump end over a larger area. This reduces the risk of breakdown of the skin over the stump end. In our series of more than 70 TK amputations no late surgery for skin problems was required.

Other techniques have been introduced over

the years, such as the Gritti-Stokes procedure with transplantation of the patella to the resected condular area. The stump end is thus created by the patella and consequently the pressure is distributed over a smaller area.

Another advantage is the perfect muscle balance of the hip and thigh muscles, as no muscular attachment is removed significantly from its original position. This facilitates prosthetic walking, as the quadriceps is not weakened and the hamstrings can still act as hip extensors.

The triangular shape of the bulbous stump also secures the rotational stability of the well fitted prosthesis. This is in contrast to the Mazet procedure, where the femoral condyles are shaped by bone resection for cosmetic reasons alone.

The major surgical advantage of the knee disarticulation is the minor surgical trauma. No bone surgery is performed and synovectomy is not attempted. As no large bleeding areas are left, the postoperative oozing and haematoma formation is reduced. In contrast to the Spittler procedure the technique utilizing side flaps places the scar in the intercondylar area, which is relieved of pressure.

In using the described procedure a few technical problems might be considered. In cases of severe knee contracture the dorsal skin incision should be placed fairly distally in order to facilitate skin closure and the hamstring attachments might be sacrificed. The TK amputation is, however, also superior to the AK amputation in these cases if technically possible. In some cases wound closure might be difficult because of skin tension. This is especially a problem over the prominent medial femoral condyle. In such cases minor resection of the femoral condyle should be undertaken as a pressure necrosis of the skin might otherwise occur leading to secondary AK amputation. The last problem to be mentioned is the postoperatively appearing synovial fistula, which occurred in 6 per cent (4/71) of our series (Jensen et al, 1982). The fistulas were located in the wound between the condyles and always dried out without further surgical treatment within a few months. The appearance of synovial fistula did not postpone the prosthetic fitting as no pressure occurs in this area.

In conclusion, the surgical technique utilizing side flaps and positioning the apex patella level

Table 1. Advantages of through-knee amputations.

weight bearing stump
triangular stump profile
strong lever arm
perfect muscle balance
minor surgical trauma

with the condyles is recommended for TK amputations as the surgical trauma is minimal, the procedure fast and safe and the stump advantageous for prosthetic fitting.

Note

This contribution is based on lecture notes and papers found in Knud Jansen's office after his death on 1 August 1982. The style and choice of words are in accordance with his presentations as are the opinions expressed.

REFERENCES

- HOLSTEIN, P., LASSEN, N. A. (1973). Radioisotope clearance technique for measurement of distal pressure in skin and muscles. *Scand. J. Clin. Lab. Invest.*, **31 Supplement 128**, 143-147.
- JENSEN, J. STEEN, MANDRUP-POULSEN, T., KRASNIK, M. (1982). Through-knee amputations. *Acta Orthop. Scand.* **53**, 463-466.
- KJØLBYE, J. (1970). The surgery of the through-knee amputation. In: Murdoch, G. (ed). *Prosthetic and orthotic practice*. London, E. Arnold. 255-257.