

# A New Approach to the Symes Amputation and Its Prosthesis

Lt. Col. B.P. Mathur  
Brig. C.L. Piplani  
Lt. Gen. M.A. Majid, V.S.M.

## INTRODUCTION

Though Symes amputation has stood the test of time as a surgical technique since Syme described it in 1843, it has always been a problem for the prosthetist to fit a cosmetically appropriate prosthesis to a classical Symes residual limb.

A classical Symes residual limb is bulbous, and too long to facilitate the introduction of a standard SACH foot in the space between the end of the residual limb and the ground in its prosthesis. The prosthesis for such a limb is bulky and consists of a self-suspending socket and foot, with or without an ankle joint. If an ankle joint is to be incorporated, the best substitute that could be incorporated is by means of hinges outside the limb, in turn further increasing the bulkiness around the ankle.

A large bulbous residual limb for end-bearing is almost "an article of faith" with advocates of classical Symes amputation. However, a surgeon's responsibility these days does not end merely with the performance of a successful operation. In addition to the amputee's functional requirements, due consideration has to be given to his aesthetic needs as well. The large ankle

appearance of a conventional Symes prosthesis is unsightly for women and those who may not be able to hide the ankle inside a trouser leg. People in India have slimmer ankles than Europeans, a racial characteristic, and they often do not hide their ankles due to the type of attire they wear.

Faced with these problems, we decided to modify the operation, as well as the prosthesis which was fabricated.

## OPERATION

The modifications we used during the Symes amputation were: a smaller heel flap, the tibia and fibula cut  $\frac{1}{2}$ " above the articular surface, and the heel pad firmly secured to the cut end of the bone by suturing it to the flap of the tibial periosteum.

The incision is made just below the tip of the lateral malleolus and goes across the sole of the foot, below the tip of the medial malleolus (Figure 1). The level of the plantar surface incision should be about  $2\frac{1}{2}$ " in front of the point of the heel. The dorsal part of the incision joining the two malleolar points should be about 1" above the level of the ankle joint.

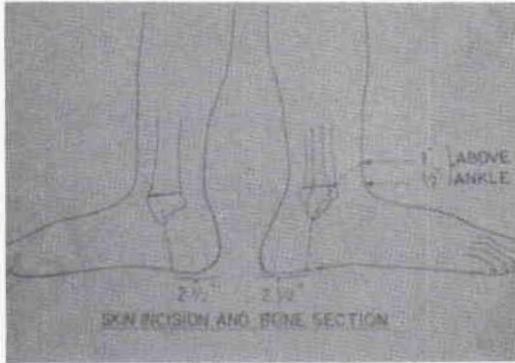


Figure 1. Skin incision and bone section.

The ankle joint is opened, and by plantar flexing the foot, both medial and lateral ligaments are cut from inside. The talus is dislocated away and the calcaneum is dissected out subperiosteally, taking care not to encroach on the fibrofatty tissues of heel pad. The tendoachilles is then divided close to the bone.

Next, the periosteum of tibia is incised at the level of the tibial section and a flap of periosteum is raised upwards. The tibia and fibula are cut  $\frac{1}{2}$ " above the articular surface and the cut ends are smoothed with a file. After haemostasis and sectioning of the posterior tibial nerve at a higher level, the heel flap is carefully centered, and the raised periosteum of tibia is sutured with the heel flap. This important step helps in firmly securing the heel flap under the lower end of the tibia and prevents its displacement or migration later. While suturing the heel flap, the heel skin covers the anterior edge of the cut tibia. This is possible because of the original anterior incision of skin being higher. The resultant residual end is not bulbous, it is just a little wider than the lower leg above and is covered with the thick heel pad meant for weight bearing (Figure 2).

Postoperatively, we give an "elephant boot" after four weeks when the heel pad is firmly fixed to the cut bone end. Weight bearing "sets" the residual limb, and boosts the patients' morale. After another three to four weeks, the fabrication of the prosthesis starts.

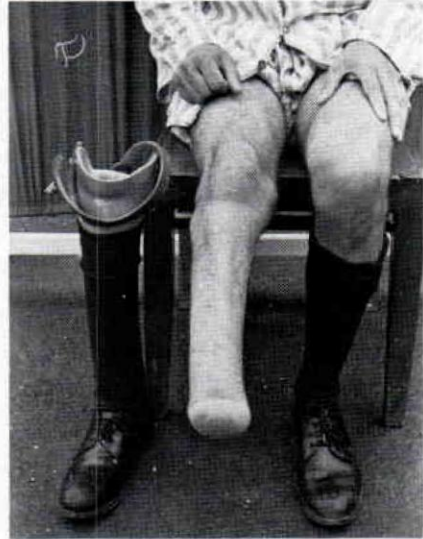

Figure 2. A modified Symes residual limb.

## PROSTHETIC FITTING

The prosthesis for the Symes residual limb that we have fabricated has a plastic socket to which a SACH foot is attached. The socket has no soft liner nor any posterior or medial opening. At its proximal end it has features of a Patellar Tendon Bearing prosthesis. It is, therefore, not a total end-bearing prosthesis, but is partial end-bearing and partial proximal tibia-bearing.

To fabricate the prosthesis, a negative plaster cast is made in the usual manner, but the proximal end is molded as for a Patellar Tendon Bearing prosthesis. On the positive model, apart from the usual build-up on the tibial crest and fibular head, a build-up is also done over the distal third of the leg so that the diameter equals that of the distal end. Generally, only a slight build-up is required to make it nearly cylindrical, because the distal end is not grossly bulbous. On this positive model, a standard plastic lamination is done to create the socket of the prosthesis (Figure 3). The socket thus produced does not have any narrow section at the distal third of the limb so that the residual limb can be easily inserted and removed. The proximal portion of the socket acts as a



Figure 3. Our Symes Prosthesis.

Causative Agents for Amputations		
Causative agent	No. of cases	%
Mine-blast injury	58	54
Crush injury	16	15
Frost-bite	33	31
	107	100

Table 1.

Original Levels of Amputation and Subsequent Modifications		
Original level of amputation	No. of cases	Surgical Procedures carried out
Choparts amputation	46	Modified Symes amputation
Symes amputation	33	Revised modified Symes amputation
Symes amputation	28	Below-knee amputation

Table 2.

P.T.B. prosthesis and the lower end bears partial weight from the distal end.

A SACH foot is attached at the end of the socket, and the prosthesis is finished in the standard manner. The patient wears a long residual limb sock, rather like a stocking, extending up above the patella, and pushes his limb into the prosthesis. A suprapatellar leather strap is used as with the P.T.B. prosthesis to stabilize the prosthesis and act as a suspension.

## CLINICAL MATERIAL

A total of 107 cases of Symes amputation have been surgically managed at this centre, of which 79 cases have had the modified operation. These cases included those done initially at this centre, and

others referred to this centre after surgery which had to be redone, as they were not fit either surgically or from a prosthetic fitting point of view. Table 1 shows the causative agents for those amputations.

The large proportion of mine-blast injury and frost-bite cases seen in this series are because the majority of our patients were soldiers wounded during the 1971 Indo-Pakistan War. Table 2 shows the original level at which amputations had been done initially, and the various surgical procedures carried out thereafter.

Forty-six patients had undergone a Choparts amputation, but since their residual limbs were deformed, painful, and provided neither weight-bearing nor comfortable walking, they were converted into Symes amputation by the described tech-

nique above. Thirty-three patients on whom a classical Symes amputation had already been performed before reporting at this centre had residual limbs which were considered unsuitable for prosthetic fitting for various reasons.

Some of the residual limbs were too bulbous and long, most with projecting malleoli. Others had displaced heel pads, as a result of which the end-bearing area was covered with normal leg skin unsuitable for weight bearing. Others had depressed adherent scars. Some cases were such in which parts of the Talus and Calcaneum were left behind. In some others, due to wound infection, there was wound gaping. All such residual limbs were revised to a Symes amputation.

Twenty-eight cases were in such a state that they could not be salvaged, and thus we had to resort to amputation at a higher level. Some cases presented extensive gangrene of the heel flap, others had extensive loss of heel flap due to uncontrolled soft tissue and bony infection. In some cases, mere disarticulation at the ankle joint was performed without coverage of the terminal end of the residual limb with a heel flap. Some had terminal, adherent, painful scars, and projecting malleoli. All these cases had to be treated by below-knee amputation.

## DISCUSSION

Syme originally devised this operation to provide an end bearing residual limb covered with heel skin containing the pad of fibrofatty tissues. He cut away only the malleoli after disarticulating the ankle. Elmslie (1924) modified the Symes amputation by transecting the tibia and fibula at a higher level to provide a smaller and thinner terminal end of the residual limb. His idea was to give a tapered end which would permit easier fitting of the prosthesis.

But this operation went out of practice because he made the limb too tapered by cutting too high, and by providing too small a heel pad. Thus, the end bearing qualities of the limb were seriously impaired. With the same aim, that is, re-

ducing the bulbous terminal end, Sarmiento, et al. (1966) rounded off the bone end, but this also resulted in reduction of the weight bearing area.

In the operation described here, we have not compromised the basic requirements of the Symes amputation. The only liberty that we have taken is to reduce the bulbous nature of the distal end, to a certain extent, by fashioning a smaller heel flap, and by cutting the bone  $\frac{1}{2}$ " above the tibial articular surface. This produces a residual limb with sufficient space between the end of the limb and the ground for introduction of an ankle joint in the prosthesis.

We did realize that by reducing the bulbous terminal end of the residual limb by our operation, we were reducing the weight bearing area of the residual limb to some extent. We compensated this objection by redistributing the load bearing forces over wider areas of the residual limb by making a prosthesis, partial end-bearing and partial proximal tibia-bearing.

Success of a Symes amputation depends upon a good stable heel pad, which is adherent to the cut surface of the tibia. To achieve stability, methods like strapping the heel pad or transfixing the heel flap with Kirschner wires have been advocated during the post-operative period for about six weeks, or until healing has fixed it to the lower end of the tibia. It is common knowledge that if post-operative supervision is neglected, the heel flap may be pushed out of place by the dressings and may get displaced over the tibia, resulting in impairment of end-bearing properties. If the heel flap is loosely attached, on weight bearing it is easily displaced to one side or the other, resulting in a wobbly or unstable heel flap. Migration of the heel flap due to pull of the Tendo-achilles is also commonly encountered.

In our technique, no post-operative fixation of the heel pad is employed. Suturing of the heel flap lined with periosteum to the periosteal flap of the tibia results in rapid and firm adherence to the cut surfaces of tibia and fibula. The only care taken is that, before suturing the heel

flap, it is carefully centered over the lower cut ends of the bones, and retained in place by ordinary conventional dressings. Suturing of the heel flap to the tough periosteal flap of tibia does not permit its displacement and, moreover, sometimes new bone forms from the tibial periosteal flap and periosteal lining of the heel flap, resulting in very firm fixation. Because of rapid fixation with this technique, weight bearing is started four weeks post-operatively.

The standard prosthesis for the classical Symes residual limb is made of molded leather, to which the foot is fixed by metal uprights. The appearance of this prosthesis with its thick ankle, uprights, and prominent laces is not satisfactory.

Development of a plastic lamination process enabled our prosthetists to design a light and durable plastic Symes prosthesis. The problem of introducing the bulbous bulky end of the residual limb through the narrower lower third portion of the socket was solved by cutting a posterior window as in the Canadian style prosthesis, or a medial window, as that of the New York University model. These prostheses, however, retained the objectionable bulky ankles, in addition to the inherent weakness of the structure at the window site. To retain window flaps, straps and buckles are employed, which further spoil the appearance of the limb.

Later, to overcome these structural defects, a closed prosthesis with an expandable inner liner had been devised (Sarmiento, 1966; Eckhardt, 1970). The inner liner was made of Kemblo rubber and Silastic foam (Romano, et al., 1972; Le Blanc, 1971; Eckhardt, 1970) which permits the bulbous end of the residual limb to go through the narrow section by expanding it. The lower third portion of this prosthesis is as wide as the distal end, giving the prosthesis a fat leg and ankle appearance. An important objection to inner liners is that in a tropical climate, it becomes uncomfortably hot, leading to excessive perspiration.

Another difficulty faced in making a plastic socket prosthesis for a classical Symes residual limb is how to fit the foot

at the end of the shin. The commonly used SACH foot needs at least 2½" of space between the end of the socket and the ground.

The classical Symes residual limb does not usually have that much clearance, and thus the prosthesis becomes too long. This is compensated either by raising the heel of the shoe of the sound leg, which looks unsightly, or by hollowing out the keel of the SACH foot, which destroys the cushioning effect of the SACH heel and may also alter the gait pattern.

In the prosthesis made at the Centre (Figure 4), most of the objectionable features described above could be overcome because of our surgical technique. The residual limb created with this technique provides sufficient clearance for a foot with its ankle to be fitted at the end of the socket. Since the end of the residual limb is not bulky, and is only slightly bigger in circumference than that of the lower third portion of the leg, a more cosmetically appealing prosthesis can be fabricated. The hard socket without a window and a liner does not pose either a problem of structural weakness or of excessive perspiration in a hot climate. The finished prosthesis is also light in weight and durable.

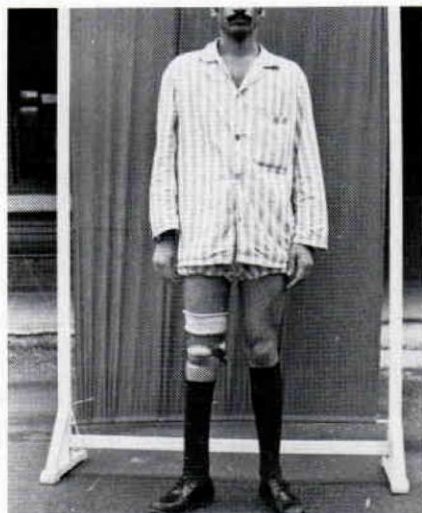


Figure 4. A Symes amputee with prosthesis.

In order to compensate for the slightly reduced end-bearing area of the residual limb, we extended the socket upwards and made it similar to a Patellar Tendon Bearing type, thus distributing some weight bearing through the proximal portion of the socket. At a rough estimate, by asking patients their subjective feeling, the weight transmitted through the end is about 75 percent, and through the proximal portion, about 25 percent.

Since this prosthesis is not self-suspending, a supra-patellar strap is provided, which provides suspension and restricts piston action. Because of the PTB type proximal portion, rotation of the residual limb within the socket is also eliminated.

The socket of the prosthesis remains in contact with the residual limb at its end and nearly the entire proximal two-thirds. Thus, proprioceptive quality is not lost. The small contact gap between the distal third and the corresponding socket wall has not been found to cause any edema of that portion of the residual limb in our series, contrary to expectations of advocates of the expandable inner liner, and total contact.

However, when indicated to achieve total contact, we advise the patient to wear a cylindrical section of sock over the narrow portion of the leg followed by the long residual limb sock on top of it. No edema of the residual limb has been noted, probably because of the usual habit of our Indian patients to remove their prostheses when not in use.

The patients operated on and fitted by our technique have been followed up for the past ten years. The residual limbs have been found healthy with good end-bearing qualities. All of them could bear weight on it, and walk indoors in an emergency without any prosthesis. No shifting or migration of the heel flap has been encountered. The patients are highly satisfied with their prosthesis both from its functional and esthetic point of view.

## SUMMARY

The classical Symes amputation is a good operation, but due to the resultant bulky distal end, there are some difficulties in fitting a prosthesis. To overcome the difficulties, the surgical technique has been modified, and a functional, cosmetic prosthesis was fabricated.

The surgical technique provides a less bulbous distal end with sufficient clearance from the distal end to the floor, to enable fabrication and fitting of a cosmetically acceptable prosthesis.

Of the 107 cases of Symes amputation which were treated, 79 had the above operation and prosthesis with very satisfactory results.

## AUTHORS

Lt. Col. B.P. Mathur is a classified specialist in surgery and Deputy Commandant of the Artificial Limb Center, Pune-40, India.

Brig. C.L. Piplani is a consultant in surgery at the Army Hospital in New Delhi, Cantt-10, India.

Lt. Gen. M.A. Majid, V.S.M., is the Chief Consultant in Surgery for the Ministry of Defense in New Delhi, India.

## REFERENCES

<sup>1</sup>Eckhardt, Arthur, L. and Harold Enneberg, "The use of a Silastic liner in the Symes prosthesis," *Inter-Clinic Inform. Bull.*, 1970, 9:6: 1-4.

<sup>2</sup>Elmslie, R.C., "In Carson's Modern Operative Surgery," 1st Edition, Cassel & Co., London, Vol. I, Section on amputations, 1924, p. 132.

<sup>3</sup>Le Blanc, M.A., "Elastic Liner type of Symes prosthesis: Basic procedure & Variations," *Artificial Limbs*, 1971, 15:1: 22-26.

<sup>4</sup>Romano, R.L., Joseph H. Zettl, and Ernest M. Burgess, "The Symes Amputation: A New Prosthetic Approach," *Inter-Clinic Inform. Bull.*, 1972, XI:4: 1-9.

<sup>5</sup>Sarmiento, Augusto, Raymond E. Gilmor, Jr., and Allan Finnieston, "A New Surgical-Prosthetic Approach to Symes Amp.—A preliminary report," *Artificial Limbs*, 1966, 10:1: 52-56.

<sup>6</sup>Syme, J., "On amputation at the ankle joint," *London and Edinburgh Monthly Journal of Medical Science*, Vol. 3, No. XXVI, 1843, p. 93.