

New Orthosis for Treatment of Hemiplegic Shoulder Subluxation

Joseph Brudny, M.D.

INTRODUCTION

Hemiplegia, resulting from stroke, head trauma or cerebral palsy, constitutes the leading cause of chronic disability and financial hardship in the United States. Over 500,000 new cases of stroke are reported each year, and at least one-third of these patients are wage earners. Effective rehabilitation of motor deficits related to brain insults is obviously an important problem facing health professionals.

Ambulation in hemiplegia usually depends on stability of the foot and ankle. In this respect, the orthotic contribution of restoring mobility in hemiplegic patients is a most significant one. The ankle-foot orthosis (AFO) stabilizes the weight-bearing part of the lower limb and makes ambulation possible, in up to three out of four patients.

In stark contrast, only one out of five hemiplegic patients ends up having any use of the upper limb, frequently because of loss of shoulder function. The function of the shoulder joint is to precisely position the arm in space in order to allow self-care and manipulation of the environment by the forearm and hand.¹ When shoulder subluxation, present in more than one-third of hemiplegic patients, complicates the course, the recovery rate drops to zero as a rule.

HEMIPLEGIC SHOULDER SUBLUXATION

The subluxation of the shoulder in hemiplegia is due to a decrease of cerebral control over the patterned and coordinated interaction of muscles controlling the position and movement of the scapula and humerus, with the result that spastic muscles tilt the scapula laterally and paretic muscles contribute to unseating of the humeral head from the glenoid fossa. Pain and reflexive spread of spasticity invariably result from attempted movement, and the recovery of shoulder function lags behind that of the elbow and wrist.²

Conventional therapy is usually of little use. Most patients, therefore, are advised to wear a shoulder sling, which, in fact, does not reduce the subluxation nor relieve pain and, if anything, perpetuates the limb's pathological synergy position.³

The Functional Shoulder Orthosis (FSO),[†] described in this article is a product of years of clinical and orthotic research. In radical contrast to available alternatives, the FSO reduces shoulder subluxation, eliminates pain, prevents spreading of spasticity, places the arm in a phy-

[†]Camp International, Inc.
109 W. Washington Street, Box 89
Jackson, Michigan 49201

biological position of function (abduction, flexion, and external rotation), and allows freedom of motion of forearm, wrist, and hand, with an opportunity for their re-training.

FUNCTIONAL SHOULDER ORTHOSIS

The FSO is made of modular parts, which interact dynamically with each other.

A stainless steel ball-and-socket joint (not unlike the glenohumeral joint) is externally interposed between the chest and arm and is attached to the torso by a comfortable and sturdy foundation of pelvic and thoracic bands and uprights. A grooved steel rod threads into the ball and is similar in its role to that of the humeral shaft in man. The ball can be made mobile in the socket, giving the humeral rod a range of motion comparable to that of the humerus. The ball can also be locked in any position with the humeral rod assuming

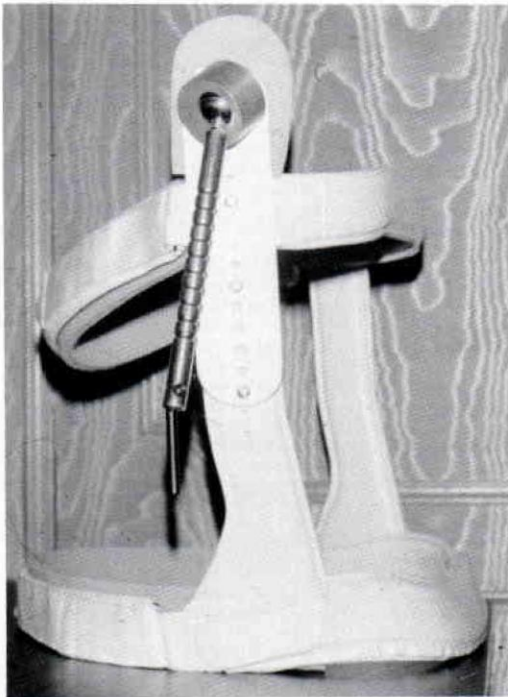

Figure 1. The ball-and-socket joint of the Functional Shoulder Orthosis, with humeral rod.

the desired degree of flexion, abduction or extension (Figure 1).

A pair of cuffs, humeral and forearm, attach to the limb above and below the elbow, respectively. These are connected by medial and lateral hinged bars forming an orthotic elbow joint with options of full or partial range of motion or stability at any desired angle. An aluminum block attached to the humeral cuff moves vertically over the humeral rod and also rotates around it, completing the assembly of the FSO (Figure 2).

When the elbow joint of the orthosis is prevented from extending beyond 150° by a stop lock, and the block is selectively elevated on the rod and fixed by a locking bolt in one of its grooves, a constant pressure is exerted against the upper ulna by the forearm cuff. This pressure, transferred axially to the humerus, repositions the humeral head into the glenoid fossa. The locking bolt, when further tightened in the selected groove, will stabilize the arm at any desired degree of rotation (Figure 3).

The orthosis is completely modular in design, is available in different sizes, and its fit and assembly by the orthotist are simple and minimally time consuming.

STUDY OF USEFULNESS OF THE FSO

The FSO, in its various prototype and final stages, was tested on eight chronic hemiplegic patients with unilateral, non-functional upper limbs with shoulder subluxation. All of the patients reached a limit in their conventional physical therapy program, and all were discharged with advice to wear a shoulder sling permanently.

Their ages ranged from 40 to 69. Five were men and three were women. Five patients were afflicted on the right side and three on the left. The duration of their illness ranged from one and one-half years to four and one-half years. The degree of shoulder subluxation in a standing position ranged from 22mm to 8mm, as determined by palpation and, in some, by X-rays. All patients had pain and exhibited

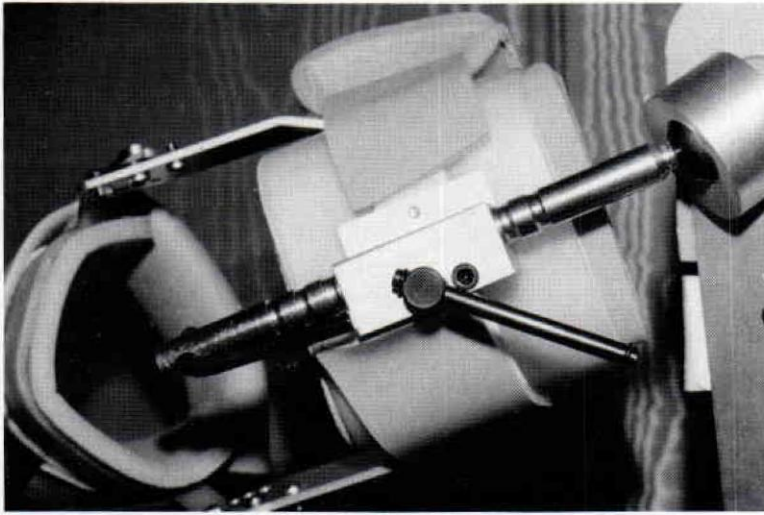


Figure 2. Hinged forearm and humeral cuffs are attached to a block which moves vertically over the humeral rod and also rotates around it.

spasticity with synergies and no voluntary control.

With the FSO in place, the reduction of subluxation was immediate and complete, and provided total relief from pain, with prompt lessening of spasticity induced flexion synergies. Such response, in all patients, allowed a course of neuromuscular re-education, or training of the patient for volitional control over dysfunctional muscles.⁴

The first phase of training was conducted in the office and was usually augmented by sensory EMG feedback from attempted or evolving movement.⁵ Over a course averaging 20 treatments of 30 to 45 minutes each—given twice a week—all patients developed the ability to flex and extend the forearm in a coordinated fashion, with extension aided by the forearm cuff counter-pressure. They also learned to relax volitionally the spastic wrist and finger flexors. Two left hemiplegics with marked perceptual motor difficulties and poor motivation declined further training.

The remaining six patients were provided with the FSO and continued its use as a training aid at home with no further sensory augmentation. Their spouses or aides received a brief office demonstration of proper FSO fitting and were instructed regarding the extent and duration of a daily self-executed exercise program at home. This phase of training lasted four months

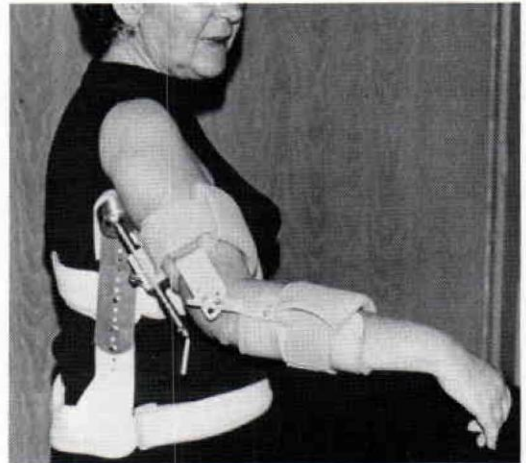


Figure 3. The humeral head is maintained in glenoid fossa by pressure exerted against upper ulna by forearm cuff and transferred axially to the humerus.

on the average, with the patients being followed-up in the physician's office at monthly intervals.

RESULTS

One patient with left hemiplegia did not progress beyond the initial stage and discontinued the training. Two patients with right hemiplegia developed bulk, power, and response to volition in previously paretic muscles of the shoulder girdle. This led to elimination of shoulder subluxation with the ability to flex and abduct the arm

without the use of an orthosis. They also retained the ability to flex, extend, pronate and supinate the forearm, and one acquired the ability for prehension and release of variously sized and shaped objects. Three patients with right hemiplegia who were not able to achieve control of the shoulder without wearing the FSO similarly learned acquisition and release of objects with full forearm mobility. These three patients have continued using the orthosis daily for a number of bimanual activities of daily living, not possible otherwise. The therapeutic usefulness of the FSO can be best illustrated by the response of one of these patients.

CASE HISTORY

Mary M., age 51, a right handed registered nurse, was first seen two years after onset of right hemiplegia and global aphasia caused by cerebral hemorrhage.

She received three months of physical therapy in a hospital affiliated with a medical school and returned home capable of mobility with assistance of a lower limb orthosis and cane. Her totally non-functional upper limb with subluxation of shoulder was placed in a sling, and she was advised to use it permanently. In the next six months, there was return of speech and comprehension, but no change in the status of the upper limb, despite continuing physical therapy.

On initial examination, marked subluxation at the right shoulder was noted (Figure 4). The hemiparetic-spastic motor deficits were evident by atrophy of limb muscles, increased DTR's, flexion of fingers, presence of cortical thumb, and clonus of the wrist. Superficial sensation to touch and pinprick was decreased distally, but position sense was well preserved, including the wrist and fingers.

X-rays of her right shoulder confirmed the extent of subluxation and at the same time demonstrated the downward rotation of the glenoid fossa contributing to the subluxation mechanism (Figure 5).

Pain at the shoulder was constant, limiting her attempts at any isolated voluntary

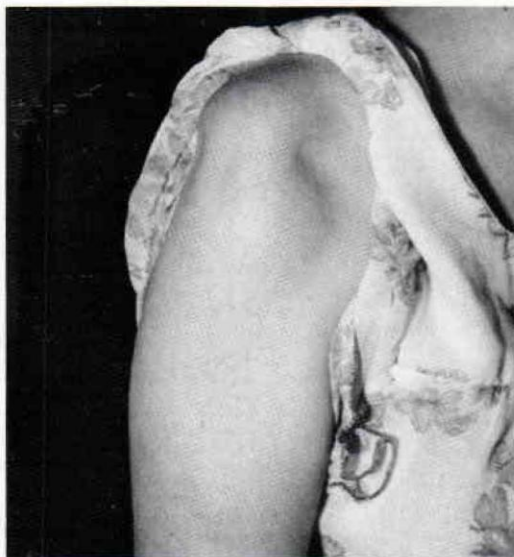

Figure 4. Considerable shoulder subluxation in hemiplegic patient.

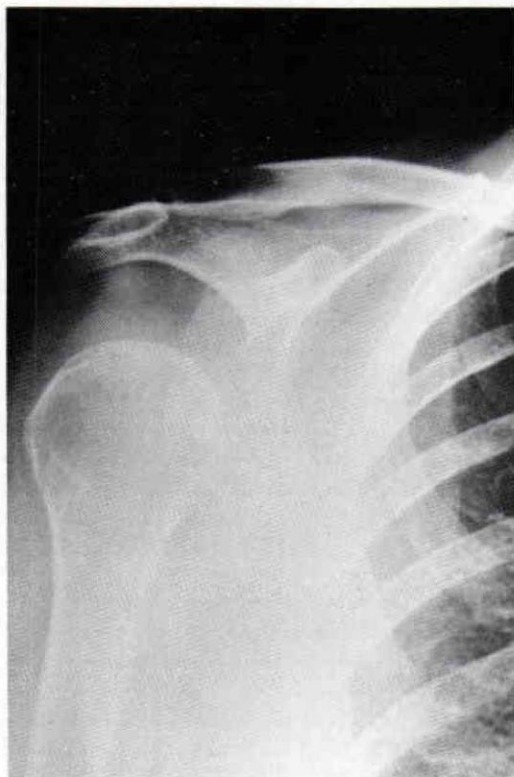


Figure 5. X-ray of patient in upright position demonstrates the degree of shoulder subluxation.

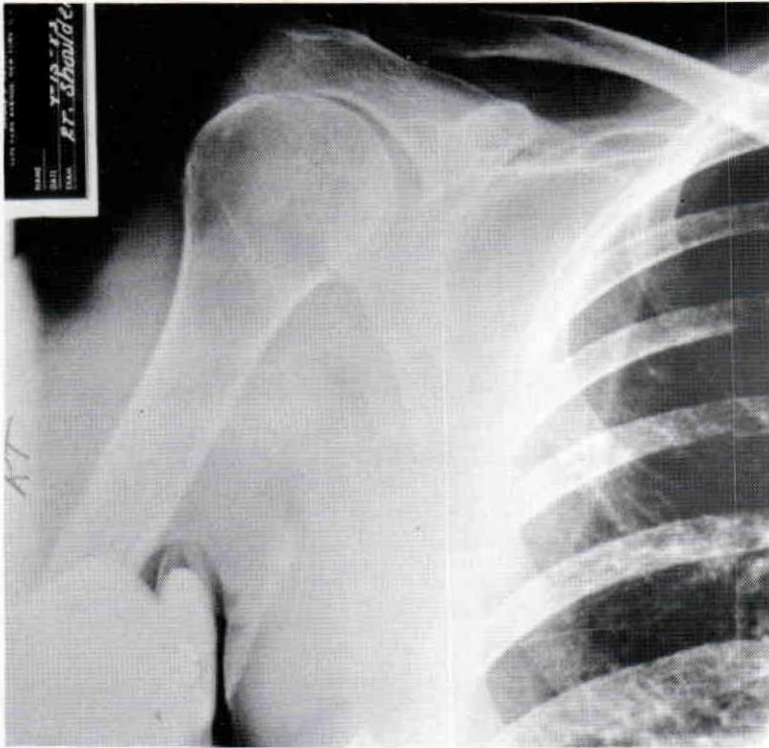


Figure 6. Same patient with FSO attached demonstrates complete reduction of shoulder subluxation.

movement. However, when a prototype of the FSO was attached, pain was instantly eliminated and subluxation was reduced (Figure 6).

During the very first session, with the aid of the FSO, Mary was able to show fairly isolated voluntary flexion of the forearm, with marked decrease of reflexive spasticity in the entire limb.

After initial course of training in the office she continued using the FSO during the four month home phase of training and then as a permanent aid in activities of daily living. She learned rapid and fully coordinated flexion and extension of her forearm, with spatio-temporal facilitation and inhibition of the agonist-antagonist muscle interaction, as documented by multi-channel EMG recordings. Supination and pronation of the forearm have become functional.

She learned volitional relaxation of finger and wrist flexors and combined such with dorsiflexion of the wrist for functional two- and/or three-point tenodesis pinch. This allowed her to acquire and release

spherical, cubic, and cylindrical objects in a functional manner, including foot items, so that she could feed herself with her right hand (Figure 7).

With the FSO, she carries out bimanual activities that add to her independence as a homemaker; for example, she is able to slice vegetables (Figure 8), and pick up and carry bimanually various objects, such as pots and pans (Figure 9). In performing these motor tasks, she demonstrates individual joint movement with coordination, and thus could be rated as stage VI on the Brunnstrom Scale, while upon initial examination she was rated as stage II, showing spasticity with synergies and no voluntary control (Brunnstrom, 1970).⁶

BENEFITS OBTAINED FROM USE OF A FSO

Based on the outcome of this preliminary study, certain conclusions seem evident:

- The reduction of shoulder subluxation immediately eliminates pain and the

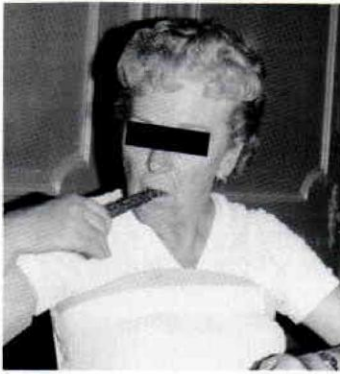

Figure 7. Patient with FSO in place is capable of increased independence in activities of daily living, for example, feeding herself.

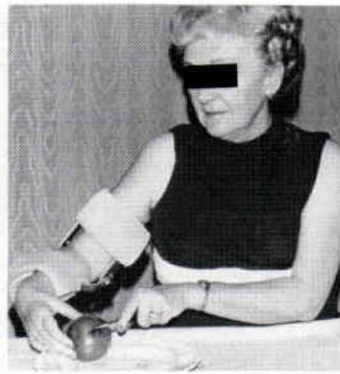

Figure 8. Bimanual activities such as slicing vegetables are possible with aid of the Functional Shoulder Orthosis.

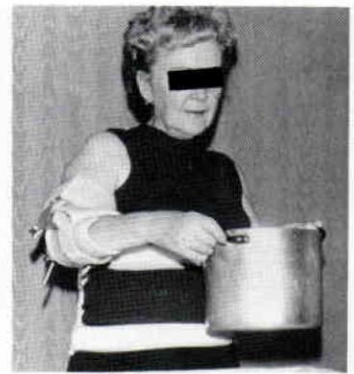

Figure 9. Bimanual lifting and carrying of large and heavy objects, such as pots, is possible with aid of the Functional Shoulder Orthosis.

spread of reflexive muscles' spasticity on attempted movement, providing comfort to the patient.

- The physiological positioning of the arm in abduction, flexion and, usually, external rotation, promotes stretching and elongation of spastic muscles of the scapula and arm and gradually decreases their detrimental activity while at the same time prevents elongation and further weakening of the paretic and unresponsive muscle groups. In time, the latter may become more responsive and functional, reversing the very mechanism of subluxation and causing its reduction.

- The elimination of pain and the spread of spasticity offer an opportunity for acquisition of voluntary movement of the limb. The patient can concentrate first on facilitation and inhibition of a key agonist muscle activity such as biceps, with acquisition of its motor control. In time, the patient can learn to coordinate simultaneously, in an orderly manner, the facilitation and inhibition of agonist-antagonist muscles, such as biceps and triceps.

- The physiological position of the upper limb, with freedom to pronate, supinate, flex, and extend the forearm, helped some of the patients to concentrate on and master more peripheral functions such as the volitional relaxation of spastic fingers and wrist flexors with simultane-

ous volitional wrist dorsiflexion. The result of this was a crude, wrist tenodesis controlled, ability to acquire objects. In one patient, finger extension and thumb abduction, adduction, and opposition were also achieved, offering more skilled prehension and more rapid release.

- The use of an FSO at home over extended time periods stresses the concept of self-help, offering to the patient the opportunity of many of hundreds of thousands of proper movement repetitions, which are essential for repatterning of movement to occur.

- In many patients, the Functional Shoulder Orthosis as a training device may be needed for an extensive time, but eventually discontinued at some point. In others, its more permanent use (comparable to that of the ankle-foot orthosis) is acceptable, considering the benefit of functional use of forearm, wrist, and hand, and bimanual activities, which would not otherwise be possible. The acceptance of the FSO, including the cosmetic aspect, was uniform, and no skin pressure was noted even with prolonged wear of the device.

- Success derived from use of an FSO seemed to be directly related to motivational drive, ability to handle information, the involvement of the dominant limb, independent ambulation, and a supportive environment.

• The FSO offers an opportunity to materially alter the non-functional status of upper limb in many patients with hemiplegic shoulder subluxation. With proper patient selection, professional supervision, family education, and orthotic support, the numbers of such patients can be considerable, while the psychological and socioeconomic benefits are most gratifying.

OTHER USES FOR THE FSO

Loss of shoulder function is of serious consequences in any illness or injury and limits the use of the entire limb, resulting more often than not in permanent disability of the afflicted individual.⁷ The FSO can, therefore, also be a valuable aid where traumatic, inflammatory, and degenerative diseases have affected the shoulder joint and temporarily compromised its crucial function of self-care and control of environment. The Functional Shoulder Orthosis can be used in conservative treatment of postsurgical phase of fractures of humeral neck and head, rotator cuff tears, and posterior shoulder dislocations; in incomplete brachial plexus lesions (C5, C6); in frozen shoulder and shoulder/hand syndromes; and in the postsurgical phase of total shoulder joint replacement. With the shoulder securely stabilized and the arm kept in a physiological position of function, the forearm and hand can be used functionally during the often lengthy period of the needed shoulder immobilization.

CONCLUSION

Orthotists have historically played a unique role in interacting between professionals (physicians, physical and occupational therapists) and patients, often educating the former while always serving the best interests of the latter.

Concerning the hemiplegic patient, orthotists have contributed significantly to restoring the main function of the lower limb, i.e. mobility. The introduction of the Functional Shoulder Orthosis has opened up a vast area of new orthotic input towards a more meaningful rehabilitation of the upper hemiplegic extremity as well.

REFERENCES

- ¹Codman, E.A., *The Shoulder*, Thomas Todd, Boston, 1936.
- ²Caillet, R., *The Shoulder in Hemiplegia*, F.A. Davis, Philadelphia, 1980.
- ³Hurd, M. "Shoulder sling for hemiplegia: Friend or foe?" *Arch. Phys. Med. Rehabil.*, 1975, 55:519-522.
- ⁴Kottke, F.J., "Neurophysiologic therapy for stroke," *Stroke and its Rehabilitation*, Licht, S. (Eds.) Waverly Press, Baltimore, 1975.
- ⁵Brudny, J., Korein, J., Grynbaum, B.B., Belandres, P. and Gianutsos, J., "Helping hemiparetics to help themselves Sensory feedback therapy," *JAMA*, 1979, 241:814-818.
- ⁶Brunnstrom, S., *Movement therapy in hemiplegia: A neurophysiological approach*, Harper and Row, New York, 1970.
- ⁷U.S. Dept. of Labor, International Assoc. of Compensation Boards: *Bulletin*, 167, 1952, Washington, D.C.

AUTHOR

Dr. Joseph Brudny is Clinical Associate Professor of Rehabilitation Medicine at New York University School of Medicine and in private practice of rehabilitation medicine.

ACKNOWLEDGMENT

The illustrations, courtesy of Camp International, Inc., were obtained with their consent.