

Distal Femur Rotation-Plasty Prosthesis

William F. Sinclair, C.P.O.

Gerhard E. Maale, M.D.

Dempsey S. Springfield, M.D.

INTRODUCTION

The distal femoral rotation-plasty procedure as first described by Borggreve¹ in 1930, was performed for functional improvement of congenitally shortened limbs. The procedure substitutes a functional ankle which is externally rotated 180 degrees, for a resected knee in the involved extremity.

Although popularized by Van Ness in the 1950's, recent interest has been renewed in the procedure for the surgical treatment of osteogenic sarcoma of the distal femur in children.^{4,5,7} The rotation-plasty in treatment of this disease can be justified in patients in whom a wide margin can be achieved for Stage IIA and IIB lesions,^{2,6} where an above knee amputation or a knee arthrodesis had been the only other practical alternatives. Surprisingly good functional results have been achieved in spite of the unusual cosmetic position of the foot as it is substituted for a knee.

The design of the prosthesis for distal femoral rotation-plasty has several special considerations needed to be addressed, which differentiate it from the standard below-knee prosthesis. The ankle joint has more planes of motion than the knee. It allows for between 25° and 75° flexion-extension at the mortise articulation and 20° of inversion and 5° of eversion at the subtalar joint. This increased motion created by eversion and inversion, that causes varus/valgus instability, results when the

ankle is substituted as the knee. The intertarsal and tarsal motion also increases this instability. It is because of this increased motion causing instability when the foot and ankle are substituted for the knee, that the incorporation of mechanical joints with uprights to control medial/lateral motions of the foot and ankle are necessary in the design of the distal femur rotation-plasty prosthesis.

CASE REPORT

T.W. was an 11 year old white male who presented with a three-month history of knee pain. X-rays revealed a radiodense lesion of the distal femur. Staging studies demonstrated an extracompartmental lesion not involving the popliteal neurovascular bundle. After an incisional biopsy revealed a high-grade osteogenic sarcoma, it was elected to perform a wide resection for local control of the disease. A distal femur rotation-plasty was performed for reconstruction of the extremity.² The reconstructed femur (the proximal femur plus the distal tibia) was made so it would be two cm. shorter than the projected length of the normal femur at the cessation of growth. Upon completion of the extra articular resection leaving the posterior neurovascular bundle intact, the tibia was externally rotated 180° and attached to the femur with a compression plate. The wound was closed in the usual fashion and the patient was started on intensive physical therapy, where he underwent a pro-

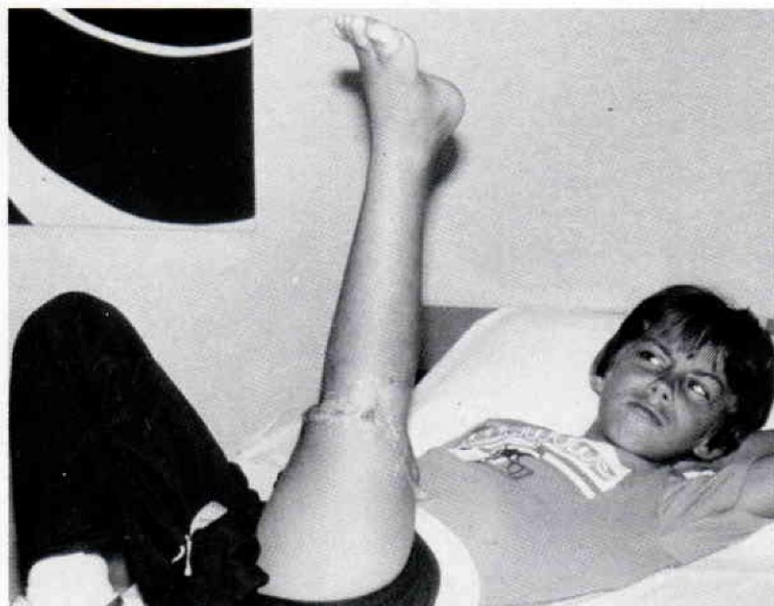

Figure 1. The distal Femur Rotation-Plasty showing foot rotated 180° to act as knee for prosthesis.

gram similar to those designed for muscle transfers. At the end of four weeks, the patient's wound was well healed and he was able to extend his newly formed knee (the ankle). At that time, he was ready for prosthetic fitting (Figure 1).

To date, three patients have undergone the above procedure at the University of Florida Shands Teaching Hospital. One of these cases had a lesion similar to the case just described. The other patient had an extra-articular resection after receiving induction chemotherapy for a Ewing's Sarcoma.

MEASUREMENT AND CASTING

After careful length measurements were taken from the patient's rotated medial malleolus to the floor with the pelvis level, a negative mold was taken extending from the ischial tuberosity to encase the entire foot. This negative mold was then filled with plaster to form a positive mold (Figure 2). Proximally, the positive mold was modified to provide a quadrilateral shape. This positive mold was then used to shape some polypropylene uprights with a quad-

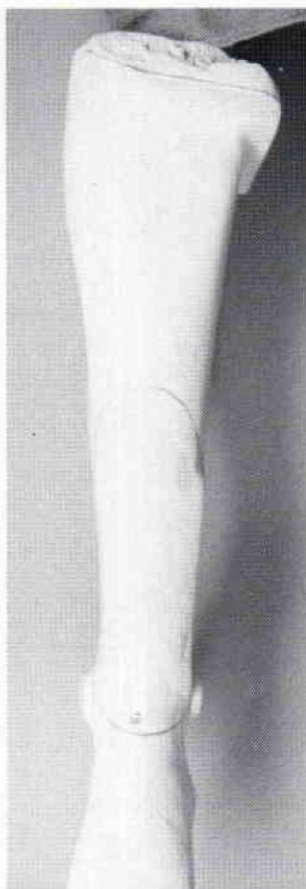


Figure 2. Positive model showing ankle joint and quadrilateral brim proximally.




Figure 3. Completed prosthesis showing anterior opening and ankle section attached to foam block.

ilateral socket for the patient's final prosthesis.

FABRICATION

Because of its light weight and low friction coefficient, polypropylene was used as the material forming proximal and distal sockets, as well as a single axis lap joint at the center of the anatomic rotated ankle joint (Figure 3). Polyurethane foam and plywood were the materials selected to be used as the attachment block for the S.A.C.H. foot. The foot socket was bench aligned in maximum plantar flexion. Initial placement of the S.A.C.H. foot was



Figure 4A. Lateral view of Rotation-Plasty prosthesis, trial fitting.

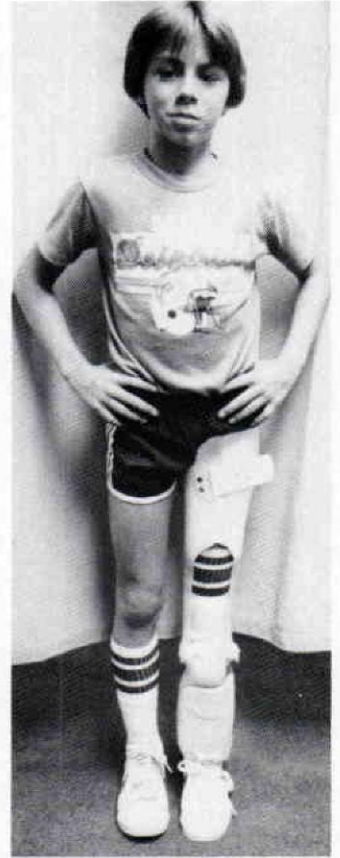


Figure 4B. Anterior view of Rotation-Plasty prosthesis, trial fitting.

moved anteriorly approximately $\frac{1}{2}$ " to create a greater extension force (plantar flexion force) on the rotated ankle for the newly formed knee (Figures 4A and B). After completion of dynamic alignment, the polyurethane calf section was shaped down and laminated with plastic resin (Figures 5A and B).

The standard quadrilateral socket was used until evidence of the bony union was seen on radiographs at the anastomosis site between the femur and tibia. At this time, the quadrilateral socket was cut down, and only a short thigh cuff remained to control any varus/valgus instability of the newly formed knee that could be created by unwanted inversion/eversion of the foot.

Shortly after the completion of physical therapy, the patients are able to quickly discard all auxiliary aids and return to prior



Figure 5A. (left) Anterior view of completed prosthesis.

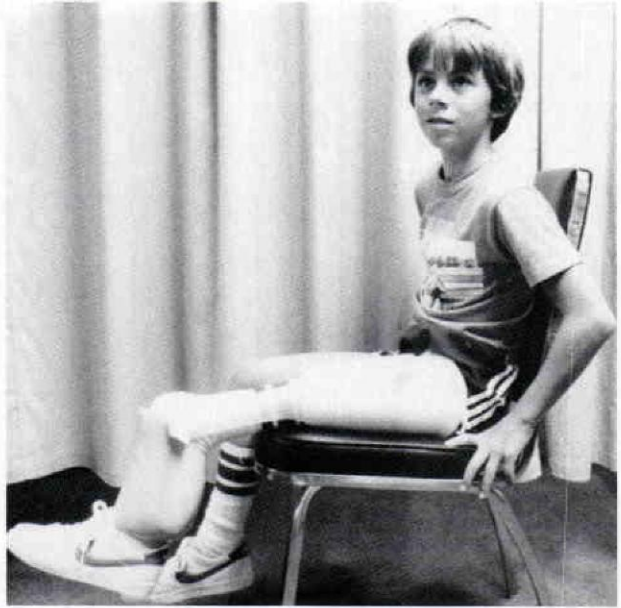

Figure 5B. (above) Lateral view showing flexion capability at the newly formed knee joint.

activities, which include basketball and running sports.

SUMMARY

The surgical rationale for the distal femur rotation-plasty procedure is that it provides the patient with a newly-formed knee created by a rotated foot and ankle that can functionally be fitted with a non-standard type of end bearing below-knee amputation prosthesis. This prosthesis when compared to the standard below-knee amputation prosthesis has the added advantage of being end bearing. Because of this end bearing nature of this prosthesis, the children are able to engage in prior sport activities, which include sports where running is involved.

With the aid of an ischial weight bearing quadrilateral socket, immediate gait training can begin. The children are

quickly able to discard all auxiliary aids and with bony healing, the socket can be trimmed to allow for a lighter prosthesis. Even with the lighter prosthesis, there is still control of unwanted varus/valgus instability of the newly formed "knee."

AUTHORS

Mr. Sinclair is with McCluney's Orthopedic and Prosthetic Services, 1309 N.W. Fifth Avenue, Gainesville, Florida; Dr. Maale is an Assistant Professor of Orthopaedics at Texas Tech University, Lubbock, Texas; Dr. Springfield is an Associate Professor of Orthopaedics at the University of Florida, Gainesville, Florida.

REFERENCES

- ¹Borggreve, "Kniegelenksetzt Durch Das in der Beinlangasche un 180° Geduchte Fugseleuk," *Arch. Orthop. Unfall. Chir.*, 28: 175-178, 1930.
- ²Enneking, W.F.; Spanier, S.S.; and Goodman, M.A., "Current Concepts Review: The Surgical Staging of Musculoskeletal Sarcomas," *J. Bone and Joint Surg.*, 62-A: 1027-1030, 1980.
- ³Frankel, V.H., and Nordin, M., *Basic Biomechanics of the Skeletal System*, Lea and Febiger, Philadelphia, pp. 179-191, 1980.
- ⁴Kotz, R., and Salzer, M., "Rotation-Plasty for Childhood Osteosarcoma of the Distal Part of the Femur," *J. Bone and Joint Surg.*, 64-A: 959-969, 1982.
- ⁵Salzer, M.; Knahr, K.; and Kristen, H., "Treatment of Osteosarcoma of the Distal Femur by Rotation-Plasty," *Arch. Orthop. and Traumatol. Surg.*, 99: 131-136, 1981.
- ⁶Simon, M.A., and Enneking, W.F., "The Management of Soft Tissue Sarcomas of the Extremities," *J. Bone and Joint Surg.*, 58-A: 317-327, 1976.
- ⁷Van Ness, C.P., "Rotation-Plasty for Congenital Defects of the Femur Making Use of the Ankle of the Shortened Limb to Control the Knee Joint of a Prosthesis," *J. Bone and Joint Surg.*, 32-B: 12-16, 1950.