

Use of the Anterior Floor Reaction Orthosis in Patients with Cerebral Palsy

Edwin D. Harrington, M.D.
Robert S. Lin, C.O.
James R. Gage, M.D.

INTRODUCTION

The knee joint that is unstable in the sagittal plane can be controlled by using one of three types of orthoses: knee, knee-ankle-foot, or anterior floor reaction orthosis. If the ankle mortise is unaffected, a knee orthosis alone, with a mechanical locking mechanism, can effectively guard against inadvertent knee flexion. There are many designs of knee orthoses that will accomplish this as long as suspension can be achieved and tolerated. This form of ambulation with locked knees lends for a rigid, energy-inefficient gait pattern.

This same gait pattern is demonstrated when the patient with an unstable extremity uses the knee-ankle-foot orthosis and drop lock mechanism. Although the KAFO solves the suspension problem and controls an unstable ankle mortise, it still offers an energy-inefficient gait pattern, interferes with balance mechanisms, and is heavier than the knee orthosis.

In patients with cerebral palsy, labored gait associated with excessive knee flexion in stance phase has presented the orthopaedist and orthotist with significant difficulties in treatment. Crouch gait commences with overactivity of the hamstrings, which increases knee flexion, and thus requires large increases in quadriceps

force to stabilize the knee² (Figure 1). Calcaneus deformity, a known complication of overlengthened heelcords following tendo-Achilles lengthenings, also significantly adds to further progression of crouch gait. Reasons cited for this complication include overcorrection, failure to protect the heelcords postoperatively, and lengthening of the tendo-Achilles when significant hip and knee-flexion deformities remain uncorrected (Figure 2).

THE SALTIEL ANKLE-FOOT ORTHOSIS

In June 1969, Jimmy Saltiel described an ankle foot orthosis which was designed to stabilize the paralyzed limb without limiting knee movement. The brace extended only as high as the knee joint and was constructed from a reinforced laminate polyester plastic. He stated, "Even a totally paralyzed knee is usually stable in the AP or sagittal direction when in full extension."¹ This principle involves harnessing the floor reaction and directing it to the anterior aspect of the distal shank, thus stabilizing the joint in extension. The brace acts as a first-class lever and the plantar-flexed attitude at the ankle utilizes the fulcrum established by the distal trimline of

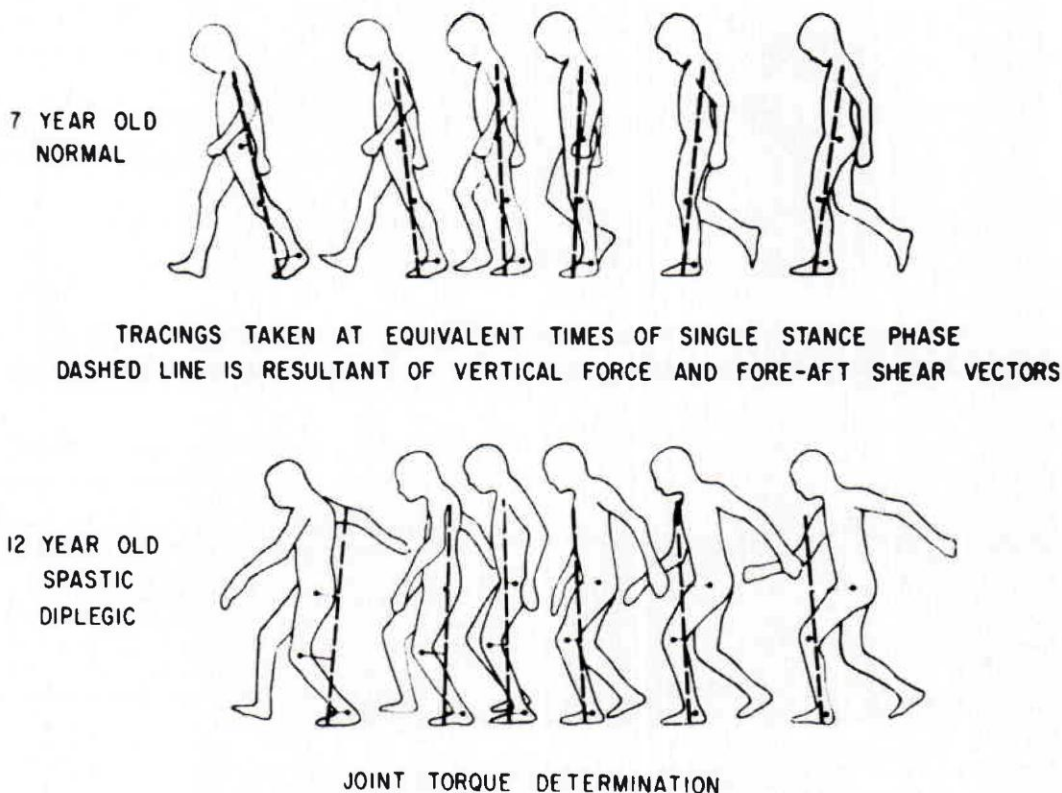


Figure 1: Line of application of floor reaction force. Contrast the line of application of the floor reaction force in the two children. Excessive arm swing and trunk movements of the patient with spastic diplegia cause early anterior shear and anterior alignment of the line of application of floor reaction force. Flexion torque of the hip is excessively high in early stance, necessitating straining action of the gluteus maximus. Knee flexion torque is normal initially but progresses to pathologically high levels in late stance, necessitating straining action of the quadriceps femoris. (From Sutherland, D.H. and Cooper L., "The Pathomechanics of Progressive Crouch Gait in Spastic Diplegia," *Orthop Clin. N. Am.*, 9(1):150, 1978. Reproduced with permission.)

the footplate at the metatarsal heads (Figure 3).

The Saltiel ankle foot orthosis employs the plantarflexion-knee extension couple seen in normal gait. At heel strike in the gait cycle, the quadriceps is eccentrically contracting to control knee flexion, thereby allowing for smooth deceleration. This continues until the center of mass passes in front of the knee, at which time there is cessation of firing of the quadriceps. From that point on in the gait cycle, knee extension is caused by the plantarflexion-knee extension couple under the control of the eccentrically contracting triceps surae.

This, in addition to the rigid immobilization of the ankle mortise, enables the transference of the floor reaction to the front of the knee resulting in a biomechanic assistance of knee extension.

With increased plantarflexion at the ankle, the moment is increased (Figure 4). With residual knee flexion contractures of ten degrees or more, the floor reaction passes at or behind the knee, thus greatly reducing the knee extension moment to a point where an actual flexion moment is generated once hamstring contractures exceed about fifteen degrees.



Figure 2: A typical crouch gait pattern in cerebral palsy. Note the effect of the overlengthened heel cord resulting in the calcaneus deformity.

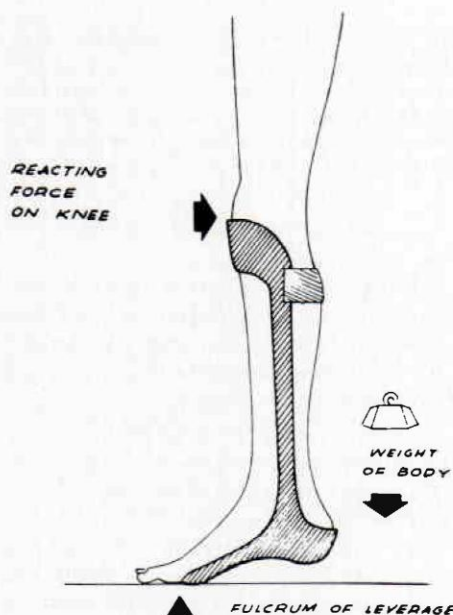


Figure 3: The Saltiel ankle foot orthosis. (From, Saltiel, J., "A one-piece laminated knee locking short leg brace," *Orthot. Pros.*, 23:7, June 1969.)

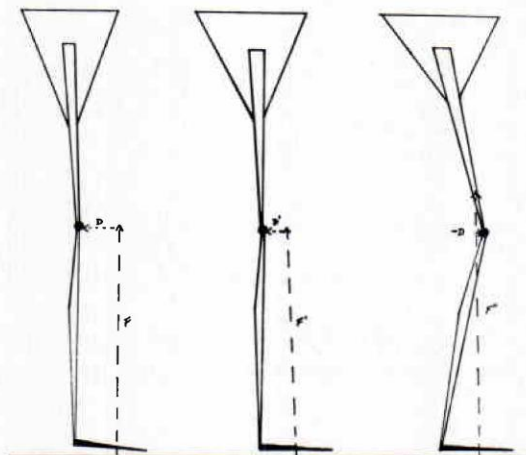


Figure 4: Biomechanics of the anterior floor reaction orthosis.

A. Shows ten degrees of plantarflexion. The more plantarflexion the ankle is set in, the greater the knee extension moment.

B. In neutral position note the reduction of D^1 resulting in the reduction of the extension moment.

C. Shows 15 degrees of dorsiflexion. At 15 degrees of dorsiflexion or greater, the ground reaction force passes behind the knee resulting in the generation of a flexion moment.

The Saltiel type ankle foot orthosis is very effective with the unilaterally involved paralytic limb that readily achieves full knee extension and is stable mediolaterally. This orthosis was originally developed for use with the post-polio lower limb and did, in many cases, preclude the need for a knee ankle foot orthosis. It should be noted, however, that this particular design cannot be applied bilaterally without significant dependence on auxiliary walking aids to improve balance. This is because with bilateral fixed equinus of the orthoses, the center of gravity is forced behind the base of support with resultant loss of balance.³

Because of these limitations and because many cerebral palsy patients require bilateral application, we modified the Saltiel design to use with these children. The principal differences in design include a shorter proximal trimline and an angulation at the ankle which we determine for each patient.

The purpose of this paper is to review the use of the anterior floor reaction orthosis in patients with cerebral palsy and, by doing so, to outline the prerequisites and specifications for prescription.

CLINICAL APPLICATION

The charts of 11 patients were reviewed. Eight patients had had clinical examinations only, and three had also been evaluated by computerized gait analysis in the Gait Analysis Laboratory at Newington Children's Hospital. Nine patients had bilateral anterior floor reaction orthoses and two used the orthosis unilaterally. The average age at delivery of the orthosis was 10.5 years (range 3.9 years to 16.2 years). Prior to using the anterior floor reaction orthosis, five of the 11 patients had used bilateral polypropylene knee-ankle-foot orthoses with drop lock knee mechanisms; one had used a double upright conventional KAFO; two had used standard polypropylene solid-ankle AFOs; and one patient had used a standard double-upright conventional AFO. In two patients who had not used orthoses preoperatively, floor reaction orthoses were prescribed immediately following bilateral release of flexion contractures at the hips, knees, and ankles.

Length of use of the anterior floor reaction orthoses ranged from five to 52 months (mean: 17 months). In patients in which the orthoses were discontinued, the main reasons were: outgrowing the orthosis, improved function, and additional surgical procedures.

The degree at which the ankle was set varied. Fourteen of the orthoses were set at five degrees dorsiflexion, five orthoses to five degrees plantarflexion, and one to ten degrees plantarflexion.

Eight of the 11 patients required hamstring releases at or before the start of treatment with the anterior floor reaction orthosis (two of these releases were repeat procedures). The other three patients were cast for knee flexion contractures before they used the orthosis, one of whom required surgery after the serial casting. It should be noted that before any of these 11

cerebral palsy patients could use the orthosis, they required elongation of hamstrings either by surgical release or by serial casting.

Ambulation Status with the Orthosis

Eight of the 11 patients are still using the orthosis effectively and three no longer need orthotic management. Eight patients are community ambulators and three are household ambulators. Four of the community ambulators use Lofstrand crutches; one, a quad-cane; one, Bobath poles; and one requires no walking aids. The community ambulators use the auxiliary walking aids mainly for balance, whereas the household ambulators use the aids to assist with gait progression.

Selection of Foot-Shank Angle

The degree of dorsiflexion or plantarflexion at the ankle of the orthosis is a compromise between the size of the extension moment generated at the knee and the smoothness of forward progression. Theoretically, when the orthosis is set in plantarflexion, the extension moment is maximal but the forward progression is at least partially blocked. If the knee extension moment is too great before the center of mass passes in front of the knee axis, overall forward progression halts. When the orthosis is set in slight dorsiflexion, more time is allowed for the center of mass to proceed in front of the knee axis before the maximal knee-extension moment is exerted by the floor reaction orthosis. While this is desirable, there is a reduction of the extension force generated as well as a delay in the harnessing of the floor reaction during the course of the gait cycle and, hence, more quadriceps strength is required. Because of these factors, it is imperative to set the ankle mortise at the most appropriate angle within the orthosis in order to achieve optimum function. This must be individualized from patient to patient since it depends on a number of factors such as whether the orthosis is bilateral, the quadriceps strength, and the maximum knee extension possible.

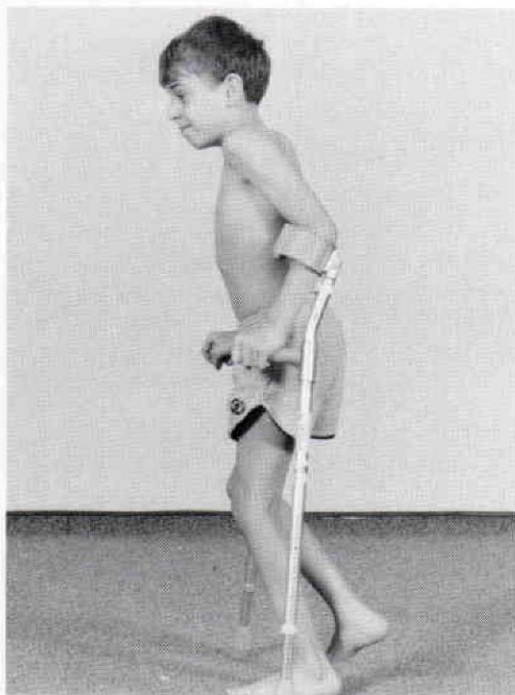


Figure 5: M.C., six weeks postoperatively. Note the dependence on forearm crutches.

Case Report

The effects of the orthosis on gait parameters can best be demonstrated by showing the results of computerized gait analysis in the following patient.

M.C., an 11 year-old male with spastic diplegia, was presented with hip flexion contractures, bilateral knee flexion contractures, and equinus deformities of both feet. At stance he demonstrated severe contractures of hip flexors, hamstrings, and triceps surae. He underwent bilateral psoas and adductor releases, bilateral varus derotation osteotomies, bilateral hamstring lengthenings, and bilateral Baker tendo-Achilles lengthenings.

Six weeks postoperatively, after casting and physical therapy, his gait revealed weakened quadriceps and beginning crouch gait (Figure 5). He was fitted with bilateral floor reaction orthoses which immediately improved his gait.

Computerized gait analysis was performed preoperatively and ten weeks postoperatively with and without the orthoses. Postoperatively, the lateral stick figures

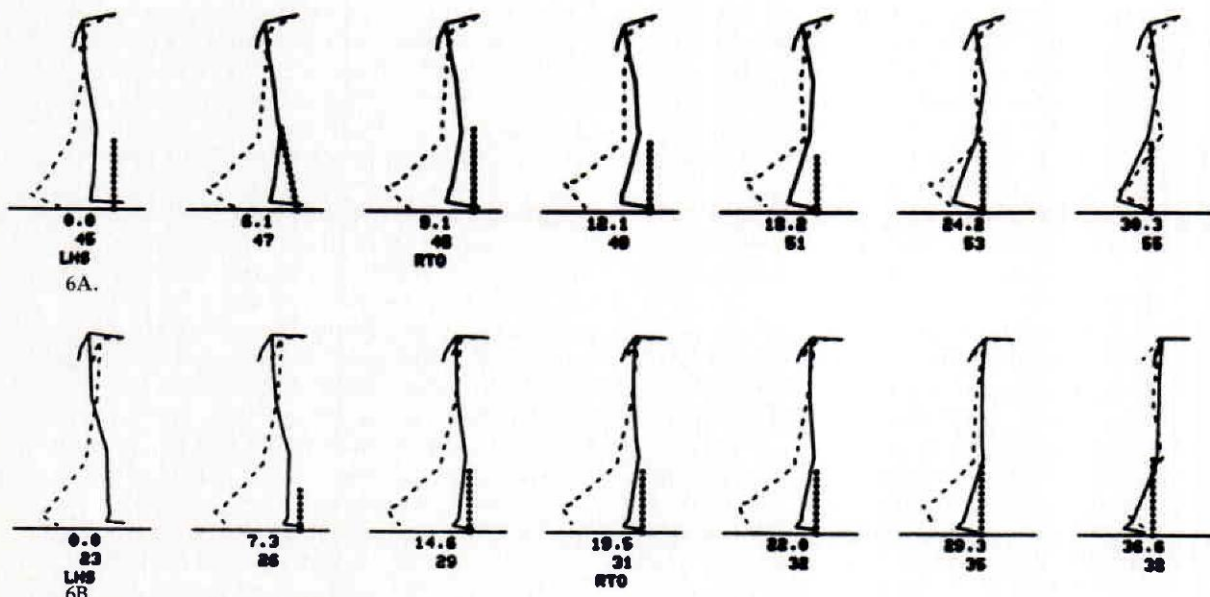


Figure 6: Stick figures of M.C., ten weeks postoperatively.

A. Lateral stick figures from a gait analysis run without anterior floor reaction orthoses. Note where the floor reaction falls relative to the knee axis.

B. Lateral stick figures from a gait analysis run with anterior floor reaction orthoses. Note the improved extension moment generated at the knee as a result of floor reaction passing more anterior to the anatomical knee.

Linear Measurements

	Right Side			Left Side		
	11/11/82			11/11/82		
	Preop.	Postop. Braces	Postop. No Braces	Preop.	Postop. Braces	Postop. No Braces
Single Stance (%)	34.48	31.25	23.08	34.48	34.47	26.83
Step Length (cm)	37.30	39.70	37.80	44.60	48.40	41.20
Walking Velocity (cms/sec)	83.55	78.41	53.89	83.55	78.41	53.89

Estimated External Work of Walking (joules/kg/meter)

11/11/82		
Preop.	Postop. Braces	Postop. No Braces
1.118	0.485	0.479

Table 1. Comparison of data from gait analyses of M.C.

demonstrated that the floor reaction force remained anterior to the orthosis and the knee joint axis throughout stance (Figures 6A and 6B).

As shown in Table 1, his linear measurements improved significantly when he used the anterior floor reaction orthoses. Since the single stance time increased when he used the orthoses, he had more limb support and stability (Figure 7). Step lengths also increased significantly with the orthoses, as did his walking velocity. The estimated external work of walking remained approximately the same with and without the orthoses but because of the increased walking velocity when the braces were worn, his gait appeared to be more efficient (Table 1).

In summary, for this patient:

1. Single support time improved with the orthoses.
2. Stride length and walking velocity improved.
3. Energy consumption remained unchanged.
4. Knee flexion was still slightly more than desired and it was postulated at

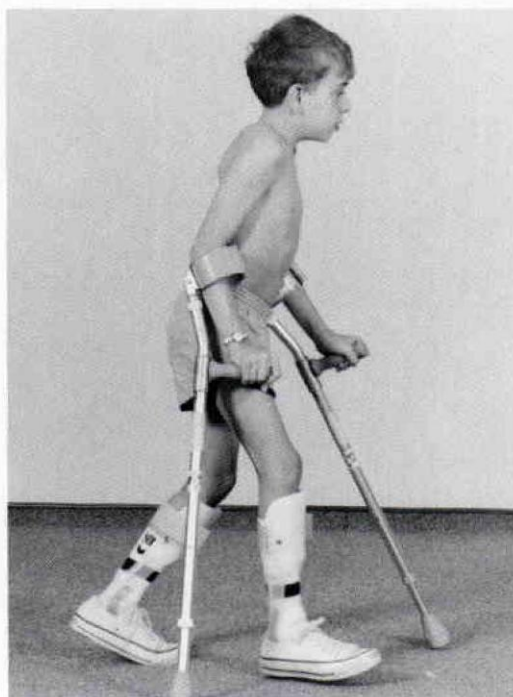


Figure 7: M.C., ten weeks postoperatively, exhibits much less dependence on forearm crutches. With the orthoses, crutches are used only to assist in balance.

this point that this patient might perform better if the orthoses were set in slightly more plantarflexion.

TECHNICAL CONSIDERATIONS

While it is virtually impossible to eliminate the elastic component of the standard orthotic materials, it should be noted that this elasticity must be reduced to a minimum. In order to harness the floor reaction and transfer it to the anterior aspect of the distal shank, a very rigid ankle is imperative. The reinforced lamination of the Saliel orthosis can be adequately duplicated with the use of $\frac{3}{16}$ -inch polypropylene, carbon composite reinforcements, and corrugations strategically placed. These materials offer a less time consuming fabrication procedure without compromising structural integrity or function (Figure 8A-8C).

In pediatric application, special consideration must be given to patellar derange-

ment as a result of absorbing the floor reaction directly on the patella. Because of this, at Newington Children's Hospital we have modified the anterior proximal trimline to end at the distal tubercle, thus not traversing the anatomical knee joint or encompassing the patella. While this trimline does reduce the effective length of the lever arm in the application of the posteriorly directed forces, this compromise is quite acceptable as there is sufficient transference of the floor reaction to achieve knee extension.

Fabrication

Cast modification of the positive mold follows standard procedures with buildups on all bony prominences, including the crest of the tibia and the tibial tubercle. In addition, the periphery of the trimlines is built up following the line of progression (Figures 9A & 9B).

Once plasterwork is completed, the positive mold is prepared for vacuum

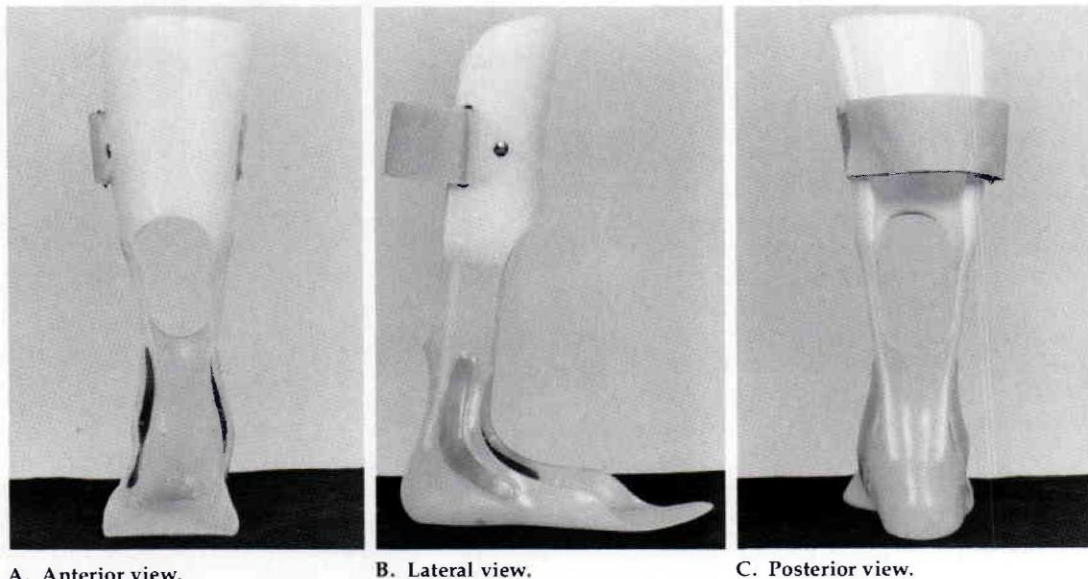
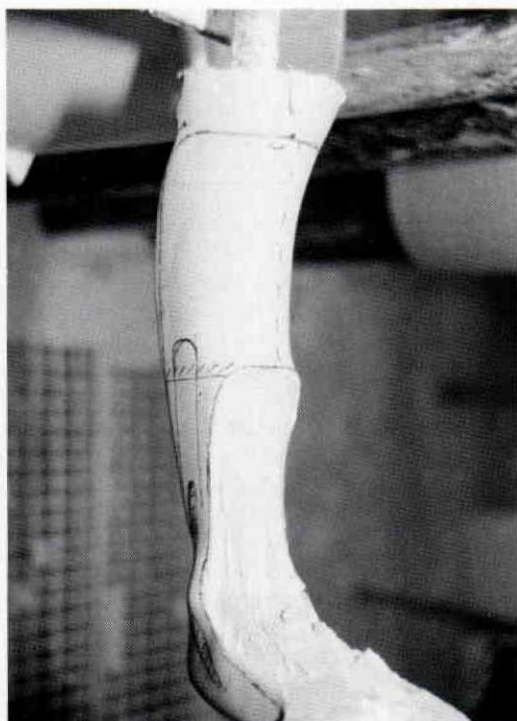


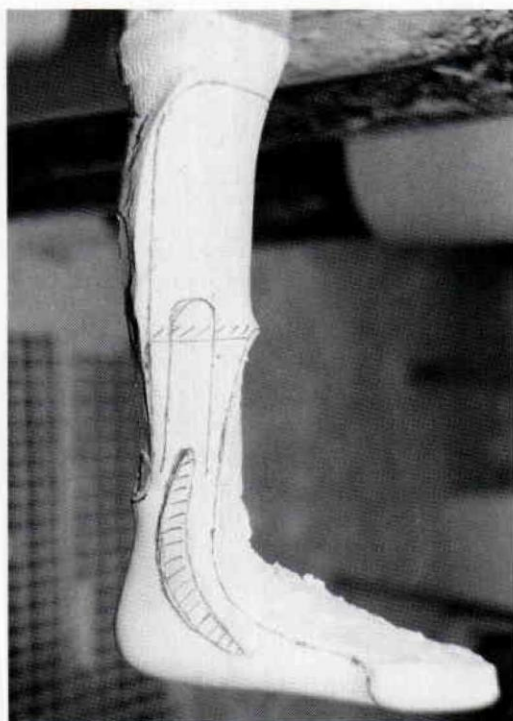
Figure 8: Finished orthosis.



9A.

Figure 9: A modified positive model of an anterior floor reaction orthosis.

A. Model is ready for lay-up of carbon composite reinforcements and rope for corrugation.



9B.

B. The horizontal line with the diagonal lines immediately above denotes the distal border of the plastazote padding.

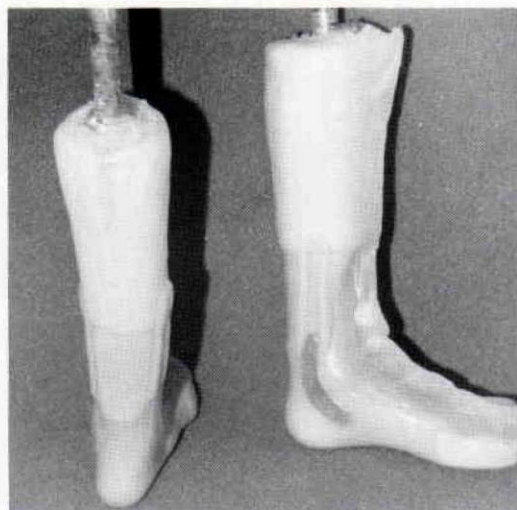


Figure 10: The orthosis molded with the seam kept as straight as possible anteriorly.

molding of polypropylene by securing the carbon composite reinforcements, rope, and Plastazote[™] on the cast. Vacuum molding of the polypropylene is done with the heel of the cast facing up, with careful consideration given to obtaining a straight seam anteriorly (Figure 10). This seam enables removal of the orthosis from the cast and must be reinforced afterwards by welding polypropylene rods to the anterior aspect of the orthosis, covering the seam and extending peripherally.

Distal trimline of the footplate extends to the end of the toes. This increases the floor lever arm and enables maintenance of fit for a longer period of time. This modified design has enabled us to achieve optimum clinical results while still taking into account those factors that are unique to treating children.

SUMMARY

It was observed that by using anterior floor reaction orthoses in patients with cerebral palsy, crouch gait was greatly reduced or eliminated. Computerized gait analyses revealed improvement in endurance, ease of ambulation, and increased linear measurements in the three patients who had pre- and postoperative gait analyses. Since the start of treatment with this orthosis, the number of patients with cerebral palsy using the orthosis has increased and results have been similar to those described in the case report. This success is contingent on the prerequisites that need to be met when considering an individual for brace treatment. These prerequisites include:

1. Absence of knee or hip flexion contractures exceeding ten degrees.
2. Careful determination of the angle to which the ankle mortise is set within the orthosis in order to optimize forward progression of the weight line at mid-stance while still maintaining an adequate knee extension moment.
3. Presence of some trunk balance and/or the ability to use auxiliary walking aids in the event of diminished trunk balance.
4. Presence of a minimum of Grade three quadriceps strength.
5. Whether or not the orthosis is unilateral or bilateral. If the weight line is placed behind the base of support, bilateral application makes balance virtually impossible. However, the

same posterior placement of the weight line is tolerated if only one extremity is involved.

When these prerequisites and specifications were met, the anterior floor reaction orthosis proved to be more successful than its predecessor, the KAFO, in the treatment of unstable lower extremities in patients with cerebral palsy. The anterior floor reaction orthosis has also been used successfully in patients with other diagnoses such as myelomeningocele, muscle disease, and poliomyelitis. Thus, the patient's clinical picture is more important than the actual diagnosis in determining whether or not to prescribe this particular orthotic design. Following the careful determination of candidacy in the patient with crouch gait, the anterior floor reaction orthosis can provide improved stability and minimize componentry, weight, and bulk.

NOTES

¹Saltiel, Jimmy, "A One-Piece Laminated Knee Locking Short Leg Brace," *Orthotics and Prosthetics*, 23:68-75, June 1969.

²Sutherland, D.H., and Cooper, L., "The Pathomechanics of progressive Crouch Gait in Spastic Diplegia," *Orthop. Clin. N. Am.*, 9(1):143-154, 1978.

³Perry, Jacquelin, "Kinesiology of Lower Extremity Bracing," *Clin. Orthop.*, 102:18-31, July-Aug., 1974.

AUTHORS

The authors are affiliated with the Departments of Orthopaedic Surgery and Orthotics and Prosthetics at the Newington Children's Hospital, in Newington, Connecticut. Send reprint requests to: R.S. Lin, C.O., Department of Orthotics and Prosthetics, Newington Children's Hospital, Newington, CT 06111.