

Femoral Immobilizer

CHARLES H. PRITHAM¹
MELVIN L. STILLS²

During the past ten years orthotics has come to play a role in the treatment of selected patients with fractures of the femur. Fundamentally, the fracture orthosis is used when fractures occur in the mid-third and distal one-third of the femur of non-obese patients after initial healing and alignment has been assured by other means. In addition to use by itself, it can be used for external support of such means of internal fixation as intramedullary rodding or compression plating. The orthosis is not primarily a weight-bearing device, but rather a system that provides stabilization by containing the soft tissues of the thigh in a cylinder. Thus, a measure of weight can be borne through the soft tissues of the thigh.

Various forms of femoral fracture orthoses have been described, Sarmiento (4) being the most widely publicized. The system used by Sarmiento consists of an Orthoplast[®] thigh gauntlet molded and sealed in place, polycentric knee joints, calf cuff, and heel cup or shoe attachment. Variations of this basic device have been described. Of particular interest is the work of Mooney et al (2, 3) which includes a prefabricated polypropylene thigh gauntlet (or femoral immobilizer) to be used with roller traction, and with or without polycentric polypropylene

knee joints and distal components. The use of a femoral immobilizer by itself has been described by others as well (1), and most frequently used as a very late form of treatment to a healing fracture that needs a measure of support with minimum encumbrance to the patient.

In essence, when the fracture orthosis is not to be a weight-bearing orthosis and when adequate suspension and stabilization can be gained by the immobilizer itself, the knee joints, side members, and other distal attachments can be eliminated with obvious advantages.

Femoral immobilizers have been constructed of various materials in the past by orthotists, therapists, and others, and prefabricated devices are readily available. However, very little has been published in the way of guidelines for the fabrication and fitting of such a device. This article is offered in an attempt to fill this gap.

The foregoing discussion is not intended to be considered as a definitive rationale for the use of such a device, but rather as a general discussion of the theory behind its development and use. Nor is there any wish to claim credit for the development of the device. The intent is solely to describe how we go about fabricating it. The decision to use an immobilizer is to be made by the orthopaedic

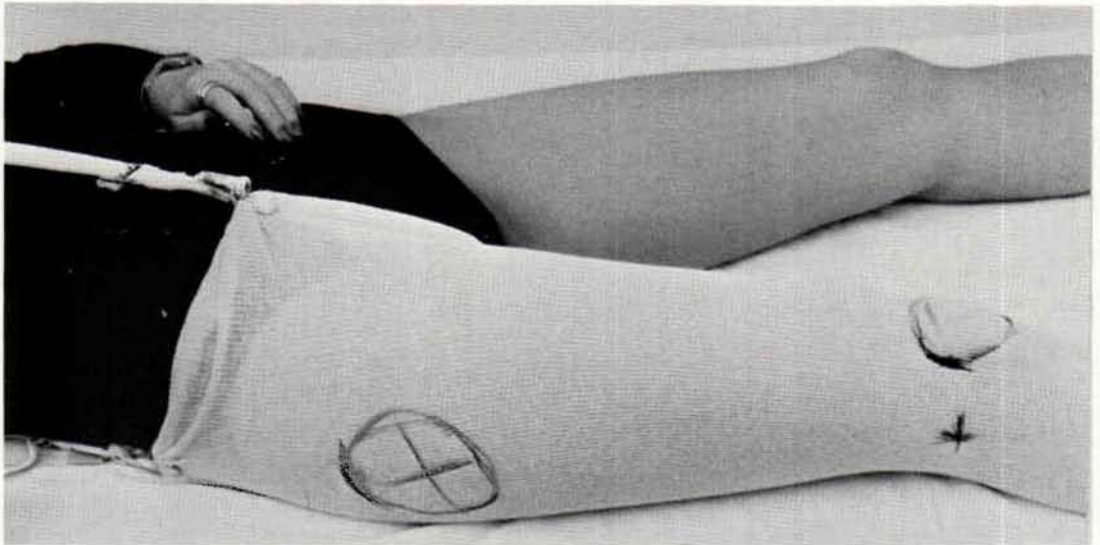


Fig. 1. Lateral view of the patient showing stockinet in place and indelible pencil marks indicating areas where modification of the positive model will be needed.

surgeon on an individual basis in light of his prior experience and knowledge of the literature.

Fabrication

In general, the cast is taken in the same fashion as described in Lower-Limb Or-

thotics (5) for the thigh portion of a knee-ankle-foot orthosis. Cotton stockinet is applied to the thigh and a tube or strip is secured in place to facilitate removal of the cast later. Indelible pencil (Figs. 1 and 2) is used to mark the following landmarks:

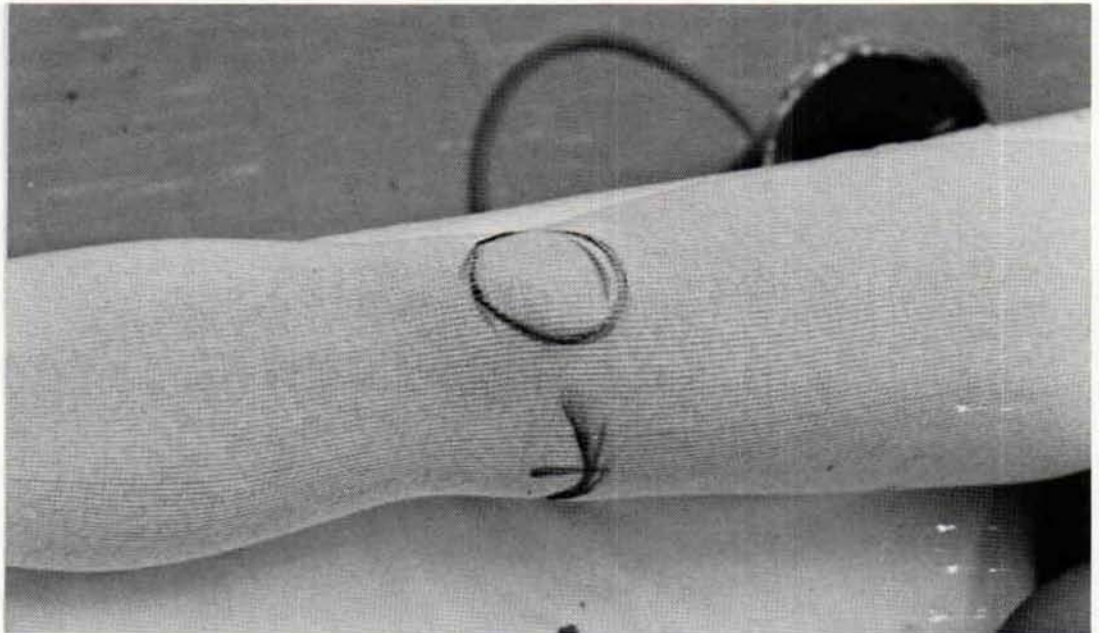


Fig. 2. Medial view showing indelible pencil marks about the patella and adductor tubercle.

1. Patella
2. Adductor tubercle
3. Lateral femoral condyle (when necessary)
4. Adductor longus tendon (when desired)
5. Ischial tuberosity
6. Greater trochanter
7. Fracture site and any skin lesions that require padding or special treatment.

Any dressings should be in place under the stockinet so that due allowance is made for them.

While the assistant holds the limb in an adducted position clear of the couch, the orthotist wraps the thigh with elastic plaster-of-Paris bandage starting from above the knee and proceeding proximally to above the previously marked landmarks. Care should be taken to accentuate the contours about the knee for proper suspension and stabilization. The cast is

reinforced, if desired, with rigid plaster-of-Paris bandage, and while it cures the contours of the quadrilateral brim are molded as described in the manual (5). Once set, the cast (Fig. 3) is removed (Fig. 4), sealed, and filled with bulk plaster to provide the positive model (Fig. 5).

In modifying the positive model sufficient material must be removed to provide for the development of adequate overall tension and for the contours proximal to the adductor tubercle and patella for suspension and stabilization (Figs. 5, 6, 7). The ischial seat of the quadrilateral brim should be within a half-inch of the ischial tuberosity with the medial brim somewhat lower so that the brim will provide rotary stabilization with comfort, and therefore it is not necessary to modify this area as extensively as is the case for a prosthesis or weight-bearing orthosis. Adequate clearance and a flared edge must be provided to the distal posterior

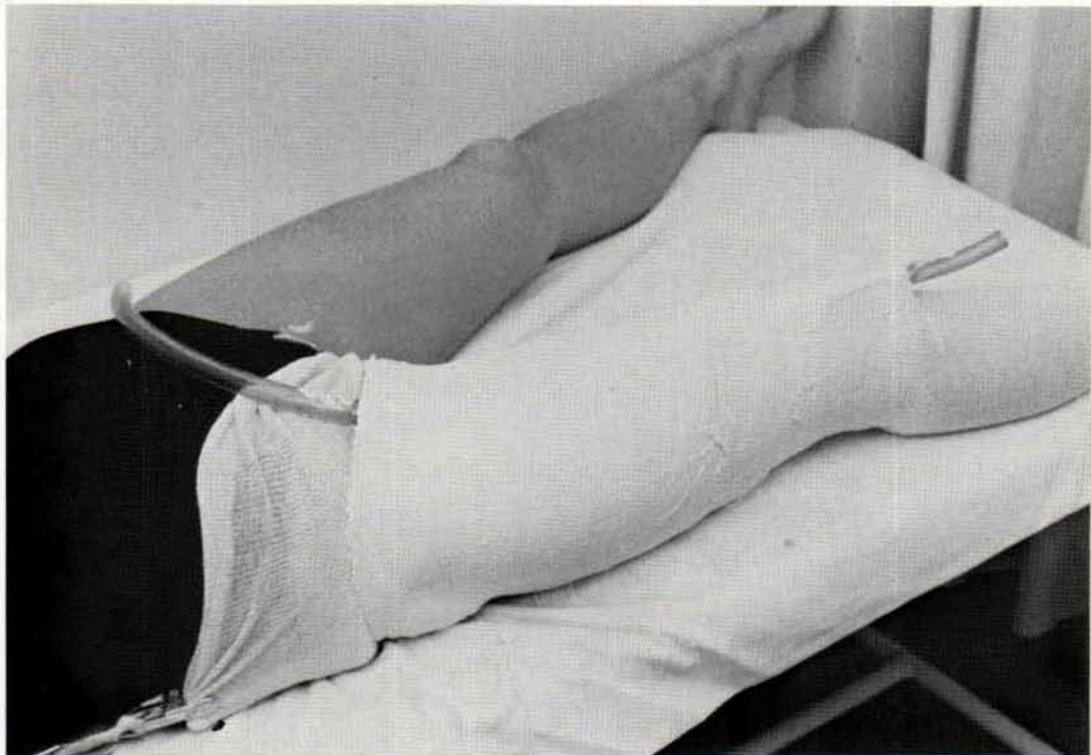


Fig. 3. Lateral view of the completed cast showing plastic tube in place.

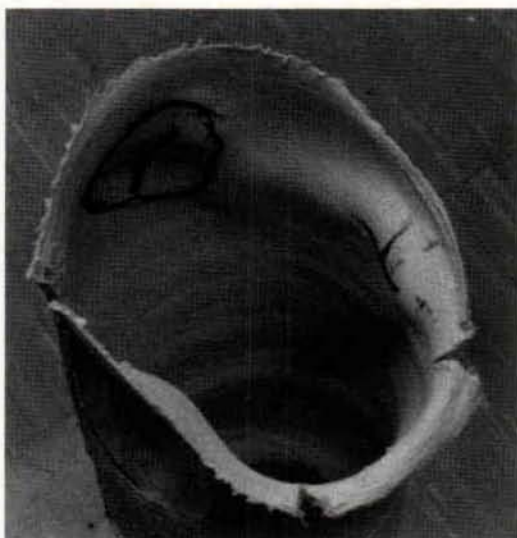


Fig. 4. Proximal brim of the cast after it has been removed from the patient. Anterior and posterior corners have been split to facilitate formation of the medial wall.

edge for flexion of the knee. Relief is added for the adductor tubercle and other sensitive areas.

The anterior tongue (Fig. 8) is vacuum-formed first from $\frac{1}{8}$ -in. thick polypropylene or polyethylene, and, when cool, trimmed to the mid-lines medially and laterally. The posterior section (Fig. 9) is then vacuum-formed over it from $\frac{3}{16}$ -in. thick polypropylene, although polyethylene can be used, if desired. When necessary, any portion or all of the orthosis can be padded with polyethylene foam, although it will add substantially to the bulk of the device and will feel warmer to the patient. The posterior section is trimmed medially along a line extending distally from the antero-medial corner, and laterally along a line over the rectus femoris. Proximally, the line of the quadrilateral brim is followed. Distally the trim starts along the proximal edge of the patella, extends distally on either side down over the femoral condyles, and proximally in the posterior area for clearance during knee flexion.

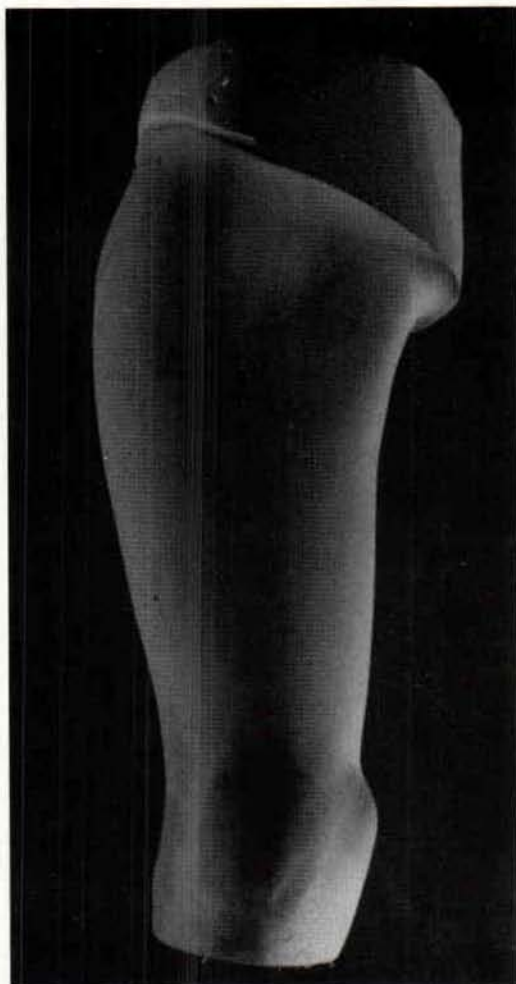


Fig. 5. Anterior view of the modified positive model. A quadrilateral brim has been formed and the adductor tubercle emphasized by removal of material proximal to it.

The tongue is secured inside the posterior section with "rapid-rivets" and four or more Velcro straps and narrow loops are added for closure. The rivets that are used to fasten on the narrow loops or straps can be used also to secure the tongue in place. For best results, the tongue should be fastened in place medially with the opening lateral, and the narrow loops should be medial as well so

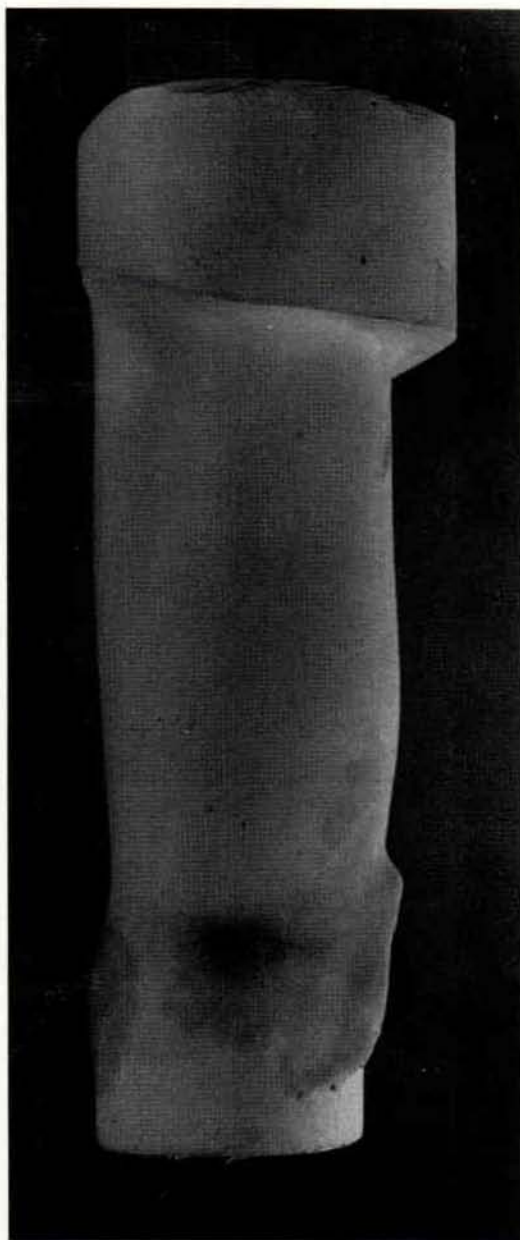


Fig. 6. Medial view showing the posterior proximal seat and the posterior distal flare.

that the free ends of the straps do not irritate the other leg. The distal-most strap should be placed immediately above the patella to insure proper suspension (Figs. 10 and 11).

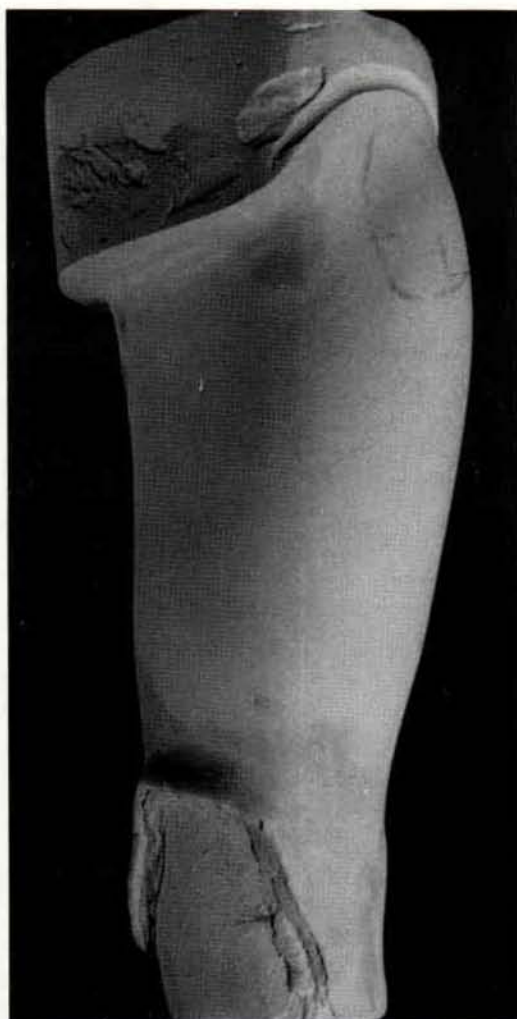


Fig. 7. Lateral view showing the posterior proximal seat and the posterior distal flare.

Before donning the device a barrier stocking is applied over the skin and any dressings present. To prevent skin maceration, the stocking should be changed daily. The distal-most strap should be fastened first while the orthosis is distracted proximally so as to make certain that the device properly settles in place proximal to the adductor tubercle. Considerable tension is needed on this strap with relatively less on the more proximal straps, which should be fastened in order from distal to proximal. Once in place

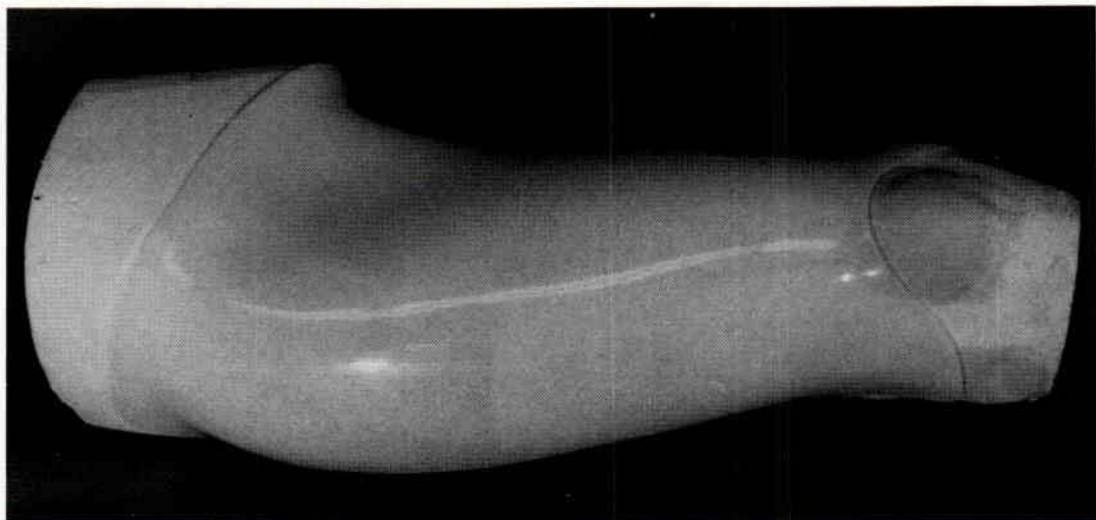

Fig. 8. The anterior section of the orthosis on the model.

the orthosis should be checked for adequate clearance during hip and knee flexion and for comfort medially. Any necessary changes obviously should be made.

There should be no discernible motion between the device and the patient's skin, and the orthosis should not impinge on the adductor tubercle when pulled distally.

The patient and attendants should be instructed on proper donning of the orthosis. It should be emphasized that if discomfort about the adductor tubercle occurs the orthosis is undoubtedly too loose, and should be removed and reapplied in a more proximal location using proper tension on the straps. When sufficient shrinkage takes place with time, the

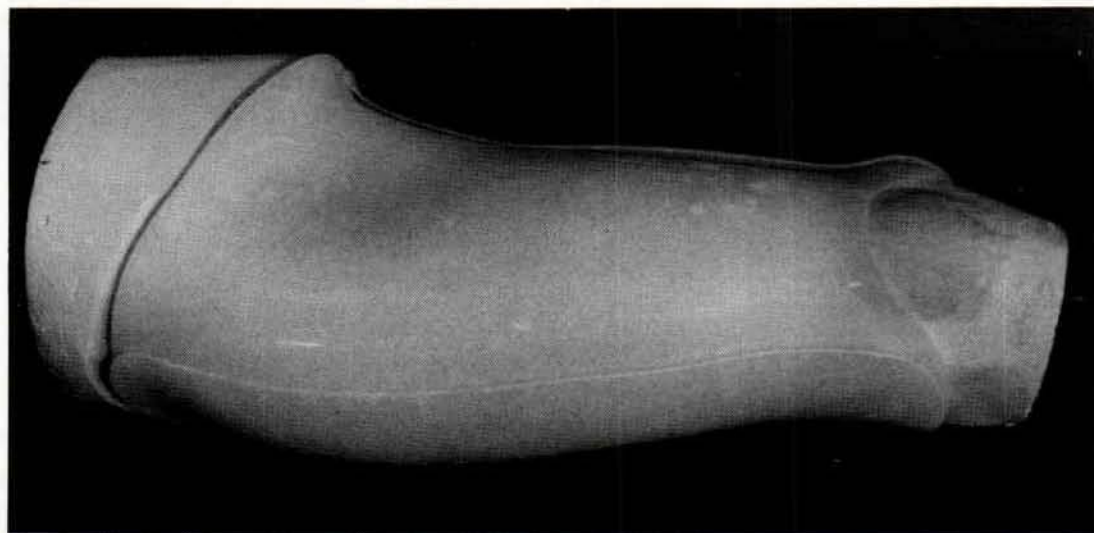


Fig. 9. The anterior and posterior sections of the orthosis on the model.

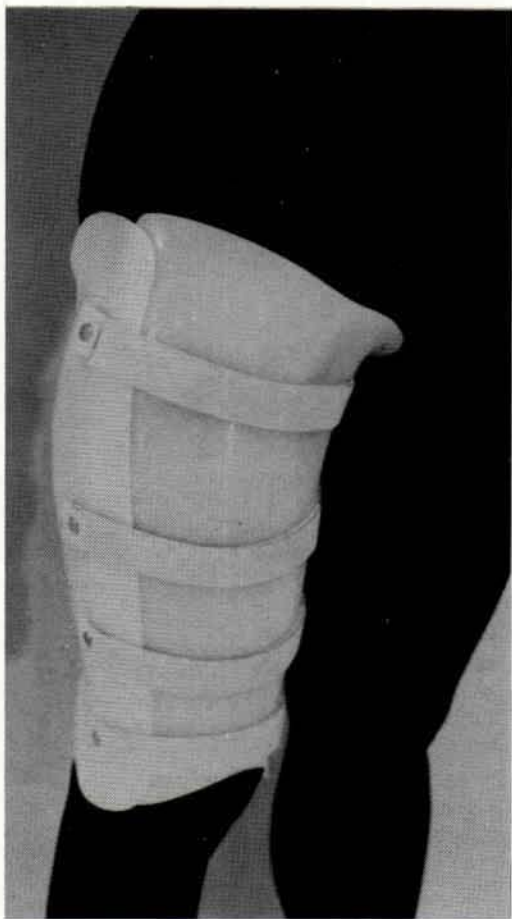

Fig. 10. Antero-lateral view of the completed orthosis on the patient. Note placement of the distal most strap.

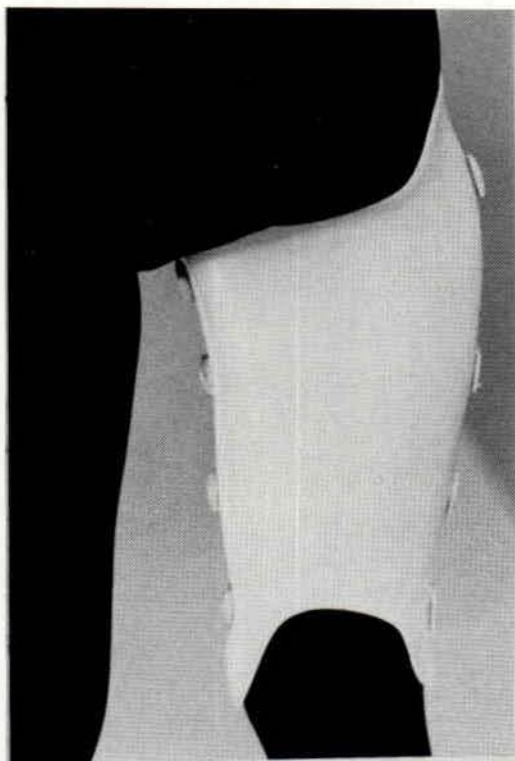


Fig. 11. Posterior view of the completed orthosis on the patient.

tongue can be removed and refitted to close the anterior-posterior diameter.

Summary

Instructions for the construction and donning of a femoral immobilizer are given, as well as some brief guidelines for the rationale underlying its use.

Footnotes

¹Director Prosthetic-Orthotic Laboratory, Rehabilitation Engineering Center, Moss Rehabilitation Hospital.

²Division of Orthopedics, University of Texas Health Science Center at Dallas, Dallas, Texas.

References

- (1) Crotwell, W.A.: *The Thigh-lacer: "Ambulatory non-operative treatment of femoral shaft fractures."* *Journal of Bone and Joint Surgery*, 60-A, No. 1, 112-117, Jan. 1978.
- (2) Lesin, B.E., Vert Mooney, and M.E. Ashby: "Cast-Bracing for fractures of the femur, A preliminary report of a modified device." *Journal of Bone and Joint Surgery*, 59-A, No. 7, pp. 917-923, Oct. 1977.
- (3) Mooney, V., G. Irons, and M. Quigley: "An adjustable plastic thigh section and knee joints for femoral fracture orthoses." *Orthotics and Prosthetics*, 30:3-8, Sept. 1976.
- (4) Sarmiento, Augusto, and William Sinclair: "Fracture orthoses" Chapter 12 in *Atlas of Orthotics, Biomechanical Principles and Application*, pp. 245-254, American Academy of Orthopaedic Surgeons, C.V. Mosby Co., Publishers, St. Louis, Missouri, 1975.
- (5) Wilson, A. Bennett, Jr., David Condie, Charles H. Pritham, and Melvin Stills: *Lower-limb orthotics: a manual*. First Edition, Rehabilitation Engineering Center, Moss Rehabilitation Hospital, Temple University, Drexel University, 1978.