

Orthotic Management of Thoraco-Lumbar Spine Fractures with a "Total-Contact" TLSO

EDWARD P. VAN HANSWYK, C.O.¹

HANSEN A. YUAN, M.D.²

WAYNE A. ECKHARDT, M.D.³

This paper reports the experiences with a "total-contact" plastic TLSO (thoracic-lumbar spinal orthosis) for management of unstable thoraco-lumbar spine fractures at the Upstate Medical Center in Syracuse, New York. The custom fabricated bivalve design, although not original in itself, incorporates a number of orthotic management techniques that, when viewed collectively, develop an original orthotics management concept.

Spinal Orthotics

Over the years, spinal orthotics has consisted mainly of the various designs handed down from the late 19th century. The names Knight, Taylor, and McCausland are all associated with various spinal orthoses describing a specific design advocated by these famous physicians. The advantages of these designs are dependent upon the particular area, or the degree of area encompassed by the device.

The particular design, no matter what material it was made of, still provides the same two force system: 1) a three-point pressure system reducing or limiting motion in a direction, and 2) the increase in intra-abdominal hydraulic pressures to limit weight forces on the vertebrae.

These designs were in general use and

acceptance until the extensive Norton-Brown study of 1957 documented the limited effect these orthoses have on certain areas of the spine. In fact, Norton and Brown showed that the longer devices actually increased motion in some areas of the spine, including the lumbar area (1).

THORACO-LUMBAR SPINE INJURIES

The thoraco-lumbar junction marks an area of transition of characteristics of the spine from the stiff thoracic region to the more mobile lumbar region. Injury to this region is quite common. When a force is applied to the upper body, the flexible lumbar spine is in a susceptible region between two relatively more stable segments.

The injury can range from a stable soft tissue injury, to complete spinal column disruption with fracture, dislocation, and instability. The T₁₂ to L₂ region accounts for approximately 50 percent of all vertebral body fractures, and 40 percent of all spinal cord injuries occur in this region.

In the case of spinal fracture, including both the stable and unstable types, the orthotic force systems available, as pointed out by the Norton-Brown study, do

not provide the degree of stabilization required in all cases.

The critical point here is the stable/unstable nature of the injury.

STABLE SPINE FRACTURE

In most stable spine fractures, the purpose of the orthotic management effort is to relieve pain and discomfort, and at the same time allow healing.

The stable types of thoraco-lumbar spine fractures include: 1) vertebral body compression fractures; 2) isolated pars defect and spinous process fracture; and 3) transverse process fractures.

The stable category of thoraco-lumbar spine fractures from an orthotic point of view require limitation of gross motion in one plane only.

The anterior body compression fracture (Fig. 1) is usually caused by sudden

vertical stress of hyperflexion, accompanied by lateral motion resulting in the compression of the vertebral body. Extreme violence is not necessary for this type of injury. It can occur when jumping on feet or buttocks.

A vertebral body compression fracture of up to 50 percent is basically stable with no immediate threat to the spinal cord, and a Jewett hyperextension orthosis is generally used to limit flexion and to prevent further vertebral stress, to allow healing, and to reduce pain accompanied by flexion.

The spinous process fracture and the isolated pars defect are usually caused by sudden hyper-extension motion or a striking blow.

The transverse process fracture (Fig. 2) often results from a sudden wrenching motion or a blow.

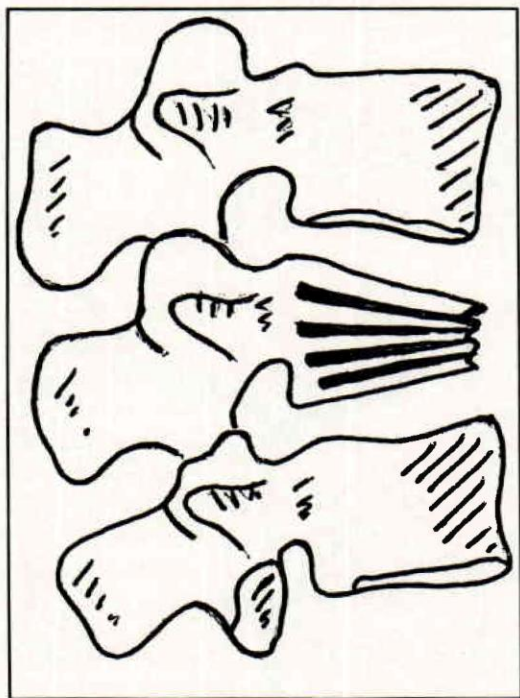


Fig. 1. Diagram of a compression fracture.

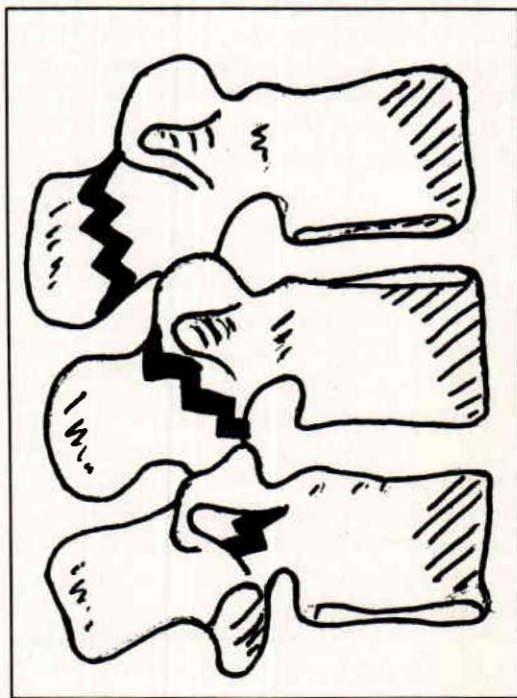


Fig. 2. Diagrams spinous process, pars defect, and transverse process fractures.

Orthotic management with a McCausland chairback or Taylor orthosis, limiting hyperextension, is usually required for the spinous process fracture. Only symptomatic support for the transverse process fracture is necessary, either by a corset or simply bed rest for a few days until comfort is regained.

Overall, there is a general willingness to use the conventional orthosis for these relatively safe injuries.

UNSTABLE SPINE FRACTURES

It is the unstable spine fracture (re: the involvement of the posterior elements and the danger of involvement or compromise to the spinal cord), that causes a major concern. The orthotic management of the unstable spine requires a surety of support. However, it is in the unstable category that conventional orthoses are most inadequate.

The unstable type of thoraco-lumbar spine fractures include the fracture dislocation, severe ligamentous disruption with dislocation, and the "Chance" type fracture.

The fracture dislocation (Fig. 3), with or without neurological involvement, is caused by violent hyperflexion or hyperextension accompanied by rotation, and is almost always treated surgically with open reduction and internal fixation by a Harrington rod, Muerrig-Williams plate or other instrumentation.

This type of fracture is extremely unstable and care must be taken to eliminate motion in all planes. The danger to the spinal cord is obvious and if neurological involvement is not apparent initially, special care must be taken to avoid cord damage.

The "Chance" type, or seat belt fracture, is characterized by the fracture line completely through the vertebra (Fig. 4). Although no gross dislocation is present, the anterior body and posterior elements are involved. The "Chance" fracture,

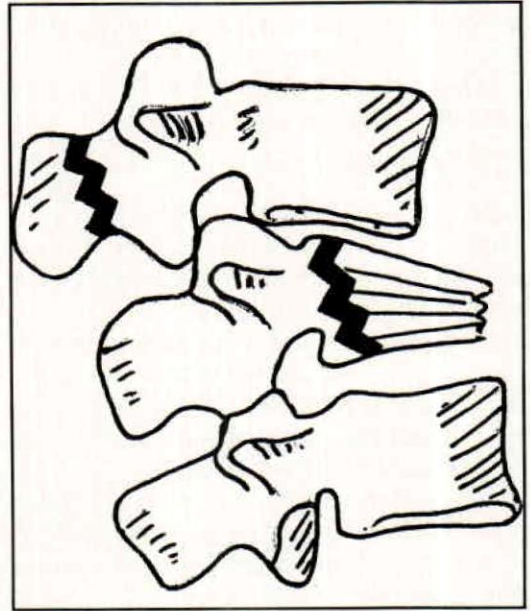


Fig. 3. Diagram of a fracture dislocation.

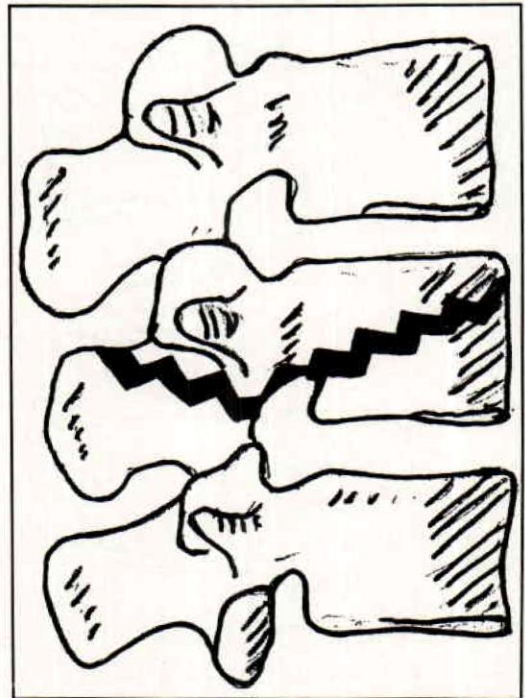


Fig. 4. Diagram of a "Chance" fracture.

usually in the thoraco-lumbar region, is caused by a violent hyperflexion from a vertical force accompanied by a horizontal force. The "Chance" fracture is also unstable. It presents a danger to the spinal cord, and therefore care must be taken to limit motion in all planes.

With no neurological involvement present, internal fixation is not necessary and the "Chance" fracture can be managed conservatively with limitation of motion and unweighting.

At University Medical Center, interest in the orthotic management of the unstable thoraco-lumbar spine fracture, including both the postoperative, internally fixed, fracture dislocation type, and the "Chance" type, led to the development and use of the "total-contact" plastic TLSO.

Orthotic Principles of "Total-Contact" Plastic TLSO

The availability of the thermoplastic material, polypropylene, led to its use in the fabrication of the "total-contact" plastic TLSO incorporating a number of concepts. Added to an expanded use and understanding of the common three-point force concept, and the increases in intra-abdominal pressures were the repositioning of spinal segments; the inductive force, or response of the body's righting reflex as an adjunct to the three-point force system; and distraction, especially costal distraction to aid in the intracavity pressure stabilizing effect.

Repositioning Spinal Segments

The repositioning or flexion of the lumbar segments of the spine is a case in point. Norton and Brown showed that a spinal orthosis of general design with pelvic band and paraspinal uprights, well fitted around the pelvis and to the general contours of the lumbar lordosis when standing, became poorly fitted and offered no support or restriction when

bending or sitting (Fig. 5). The natural tilt of the pelvis was altered with the release of the hip flexors, changing the angle of the lumbar posture, and causing poor alignment of the orthosis.

To overcome this orthotic shortcoming, a reduction of the lumbar lordosis is necessary. By repositioning the lumbar spine and reducing the lumbar lordosis in neutral, or when standing, the change in pelvic tilt to the bending and sitting position is negated, and, therefore, does not affect the fit or stabilizing effect of the orthosis.

The total-contact concept of using plastic molded to a repositioned plaster form allows maintenance of the reduced lordotic posture in the orthosis more so than with the conventional orthotic design.

The reduction of the lumbar lordosis also offsets the center of gravity in the sagittal plane, resulting in a natural righting reflex in extension. This reflex is used to augment the three-point force system of orthotic support (2).

Distraction

A usable distractive force on the spine has been demonstrated by Blount with the Milwaukee CTLSO (3). With the total-contact concept of TLSO, the plastic shape molded over a plaster model reflecting an elevated rib cage combined with the reduced or extended lumbar spine, results in a distraction between the lower thoracic and lumbar spine as an adjunct to intracavity pressure and unweighting. With this understanding, a casting procedure was devised.

Plaster Cast Procedure

A plaster cast model, reflecting the pelvis tilted posteriorly, reduced lumbar lordosis, and elevation of the rib cage, is used to mold the plastic total-contact orthosis. The body repositioning required to obtain the plaster cast necessary to

form the plastic orthosis must be tempered by the limitation of movement suggested by the injury.

The unstable fracture, either "Chance" type or postoperative (internally fixed) fracture dislocations, must be treated with special care. The patient confined to bed or Foster frame must be maintained in the horizontal, unweighted position when a cast is taken or an orthosis is fitted.

The cast must be taken with the patient in either a supine position on a Risser table, or in a two-stage supine/prone position on a Foster frame or in bed. The conditions and restrictions placed on patient motion and equipment availability, may dictate the method chosen.

When the Risser table method is used,

the cast is taken in a regular circular-wrap manner and bivalved for removal.

The supine/prone casting method, when necessary, is done in two stages. The positioning of the patient in the reduced lordotic posture with hips and knees in flexion is necessary where casting on the frame or bed (Fig. 6).

The patient is rolled or flipped, care being taken to maintain the flexion at hips and the position of the knees, and the opposite side of the cast is applied (Fig. 7).

Plastic Molding

After conventional cast preparation, the plastic is molded in a two-stage procedure, creating a "clam shell" or bivalved opening with overlapping sides for

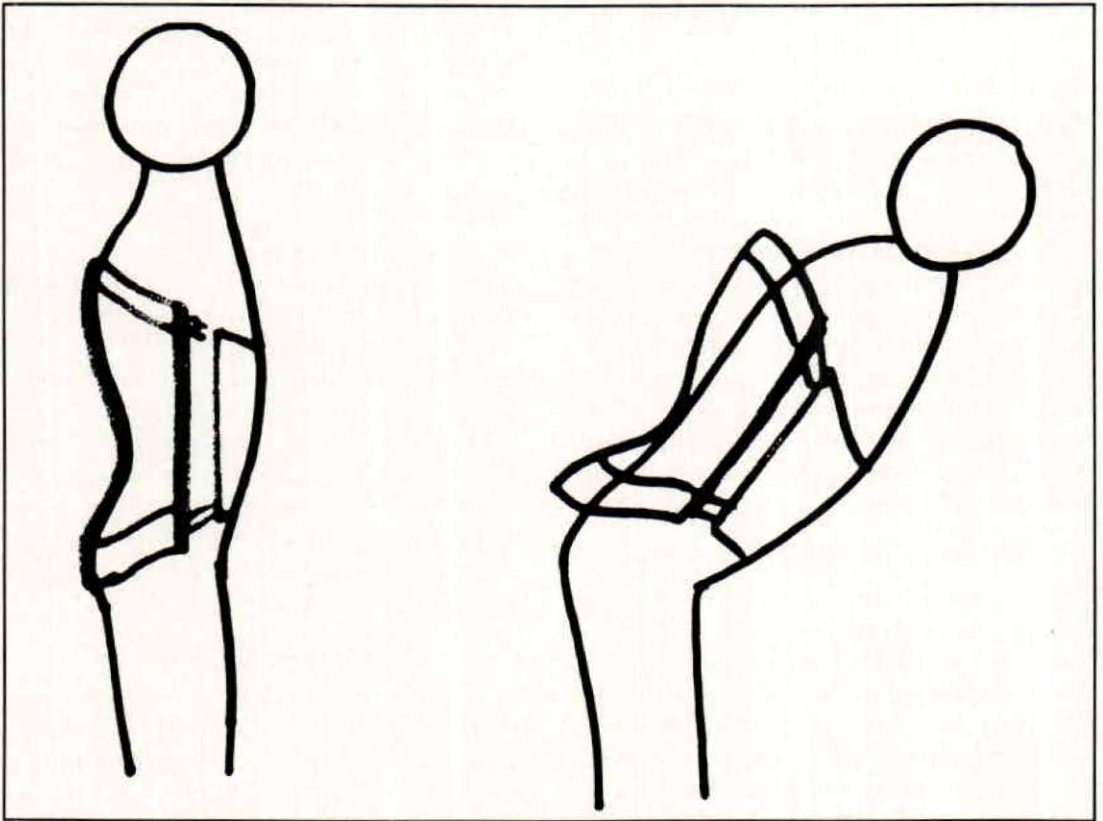


Fig. 5. Diagram showing deficiencies of conventional spinal orthosis as described by Norton and Brown (1).

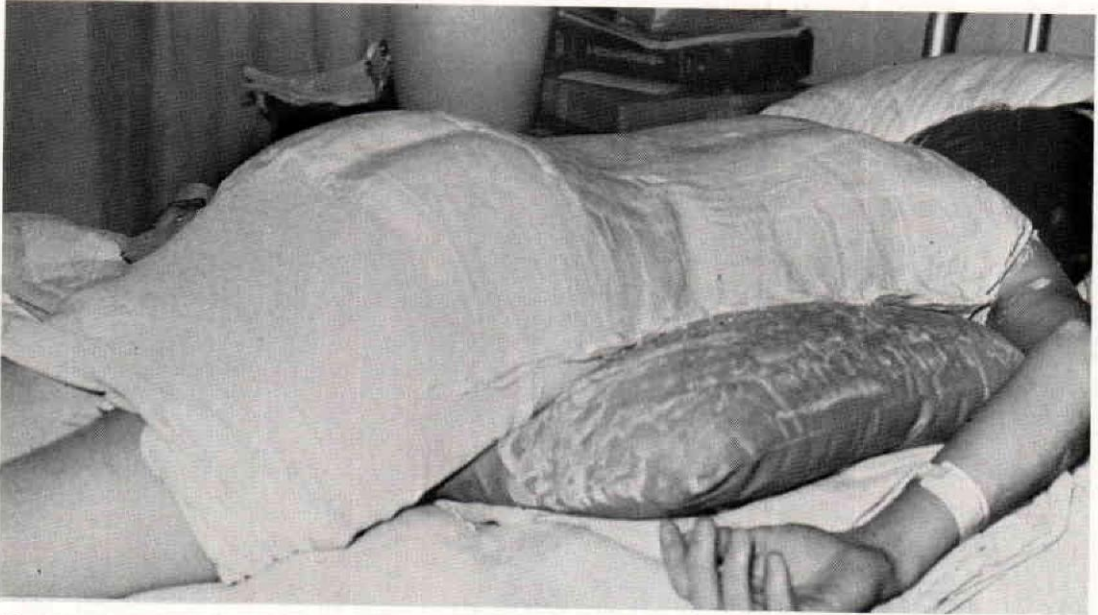


Fig. 6. For casting the patient is placed in a reduced lordotic posture with hips and knees flexed.

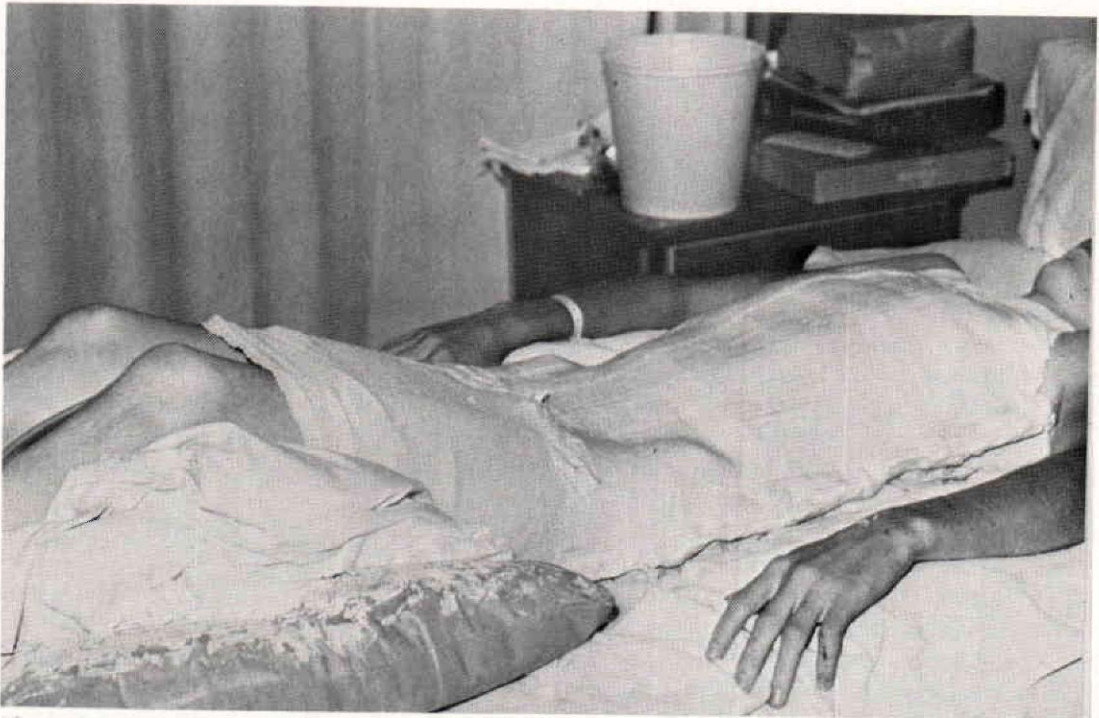

Fig. 7. For the second stage of casting, the patient is rolled into a supine position. The flexion of the hips and knees is maintained.

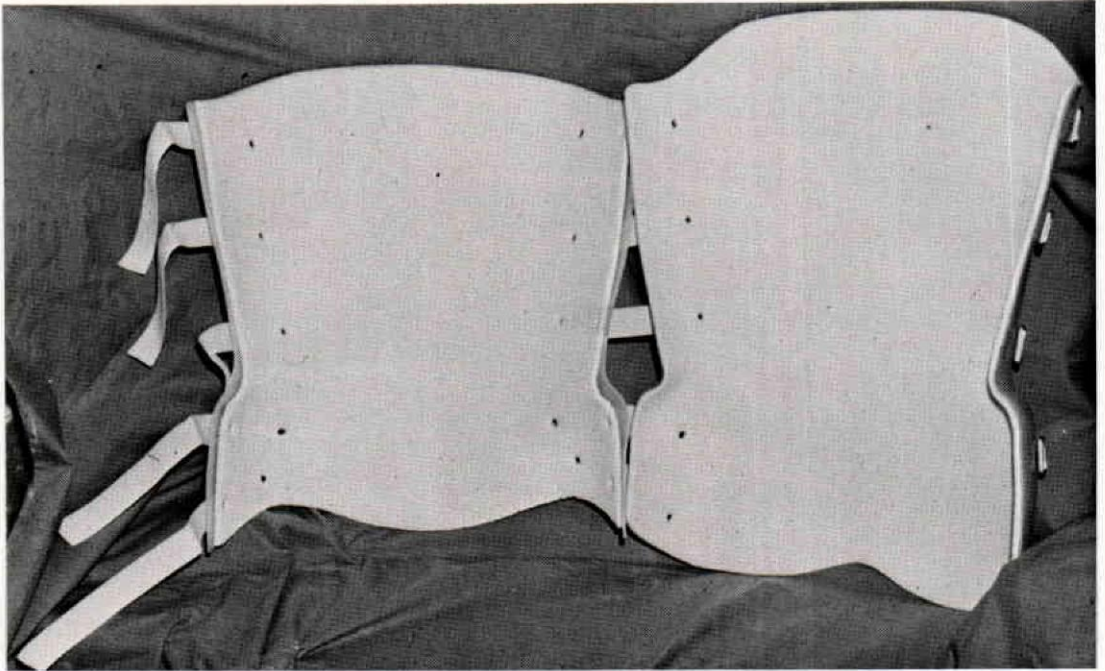


Fig. 8. The total-contact TLSO in the open position.

adjustability.

Pelite foam padding is used inside the jacket with reinforced areas posteriorly at the PSIS and anteriorly at the ASIS and iliac crests. Both halves are connected with Velcro and hook closures for adjustability and secure positioning (Fig. 8).

Plastic Trim

The total-contact plastic TLSO extends from the axilla level of the thorax, superiorly, to the pelvis, inferiorly, allowing flexion of the hips (Fig. 9). The superior trimlines determined by the level of involvement can be reinforced also with shoulder straps to provide stability up to the T₈ level. The molded pelvic section, with reduced lordosis and added support and stability, influences reduced motion to L₃ (see Case 1, presented below).

This total-contact concept also proved advantageous for use with neurologically involved patients. The use of the Jewett

hyperextension orthosis to prevent flexion in a patient with reduced sensation in the lower torso presented problems. When sitting, the lack of sensation and proprioception caused flexion to occur over the entire lumbo-sacral-hip joint area and resulted in an unacceptable degree of pressure on the lower abdomen.

The limited area covered by the Jewett pad contributed to this excessive pressure.

With the total-contact device, the stabilizing force is distributed over the entire lower pelvic area, and the flexion can occur at the hip only (Fig. 10).

Rehabilitation and Nursing Advantages

The total-contact TLSO has the following advantages when used to manage the unstable spine fracture.

1. The orthosis is applied by a supine/prone roll and does not necessitate exces-

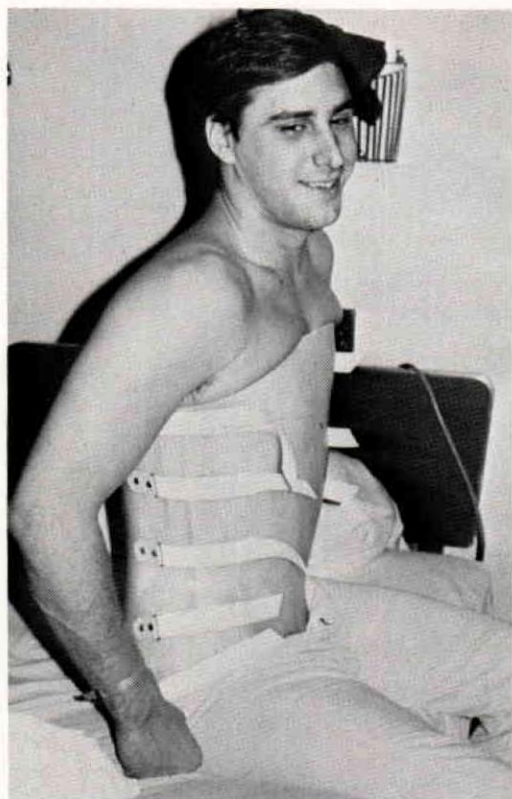


Fig. 9. The total-contact TLSO in position on patient.

sive movement by the patient or motion of the spine. Since the total-contact orthosis follows the body contours so closely, the "guess" in positioning on the patient is lessened.

2. The orthosis can be worn while in bed. Since the posterior section is contoured smoothly to the patient's body and padded with foam to relieve pressure areas, it can be worn while lying supine without the creation of excessive pressure points.

3. Early postoperative or posttrauma rehabilitation and resumption of activities of daily living is an advantage. For the period during which the natural stabilization is occurring, the limitation of motion by the orthosis allows early activity and discharge.

Results

Case Study Number 1

An example of the stability offered by the total contact TLSO is presented with this case study.

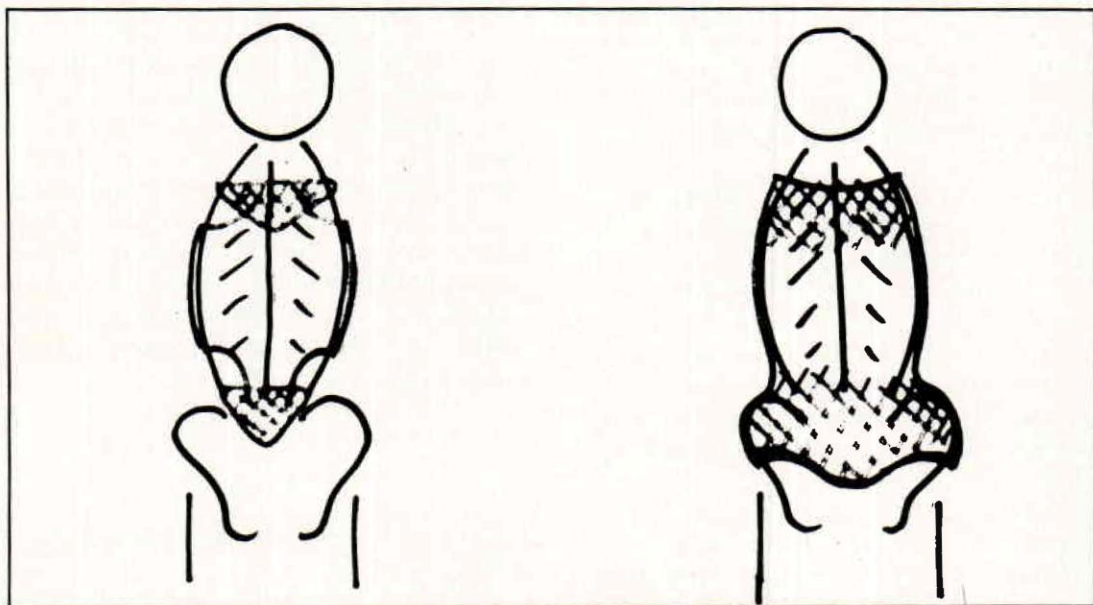


Fig. 10. Diagram showing differences between the Jewett spinal orthosis and the total-contact TLSO orthosis.

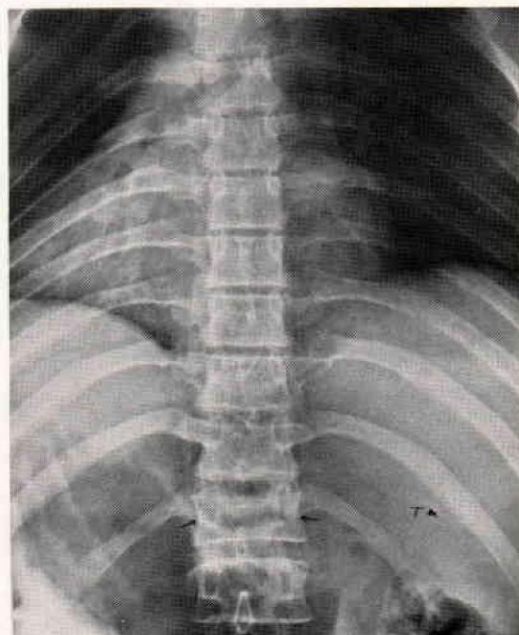


Fig. 11. Initial A-P X-Ray view of Case No. 1.

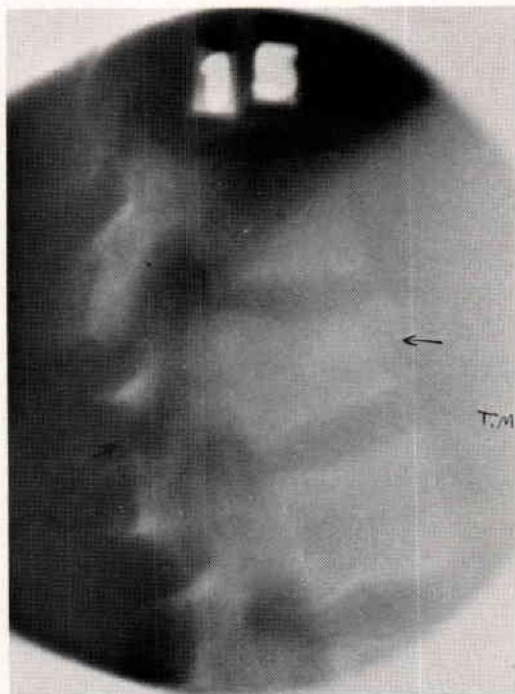


Fig. 12. The lateral tomogram of Case No. 1.

This patient presented with a neurologically intact "Chance" fracture of T₁₂.

The initial A-P X-ray view (Fig. 11) shows the fracture line through T₁₂.

The lateral tomogram (Fig. 12) shows the anterior body and posterior element involvement.

In order to demonstrate the effectiveness of the support and limitation provided by the total-contact TLSO, a series of flexion and extension films were obtained.

Figure 13 is a standing lateral view in neutral in the total-contact TLSO.

Figure 14 is a standing lateral view in forward flexion in the total-contact TLSO.

Figure 15 is a standing lateral view in extension in the total-contact TLSO.

These views were measured. No appreciable motion between T₈ and L₂ was demonstrated.

Conclusion

The "total contact" concepts of:

1. repositioning of the lumbar spine.
2. thoraco-lumbar distraction
3. distribution of force pressures

have been demonstrated relative to support of certain unstable spine fractures.

The "total-contact" TLSO can be applied and worn while maintaining respect for patient immobilization and unweighting. Overall, it has proven to be a worthwhile tool in the management of thoraco-lumbar spine fractures.

Footnotes

¹Director of Orthotics, SUNY, Upstate Medical Center, Syracuse, New York.

²Assistant Professor, Department of Orthopedic Surgery, SUNY, Upstate Medical Center, Syracuse, New York.

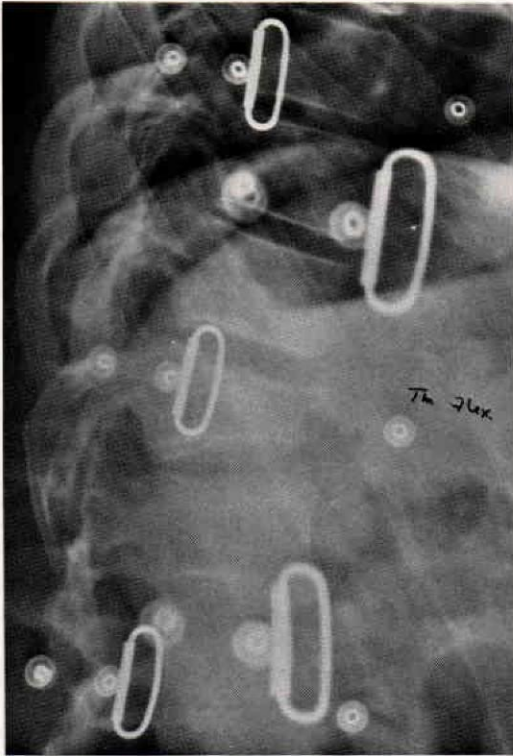


Fig. 13. Standing lateral X-Ray view of Case No. 1 in neutral total-contact TLSO.

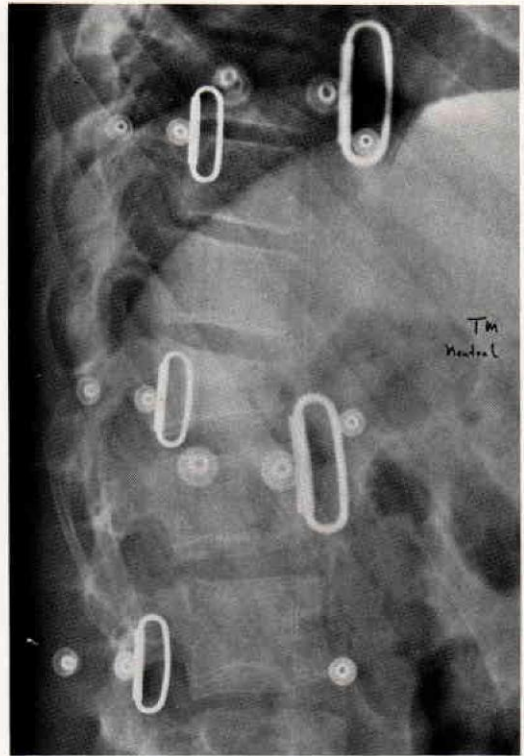


Fig. 14. Standing lateral X-Ray view of Case No. 1 in forward flexion in TLSO.

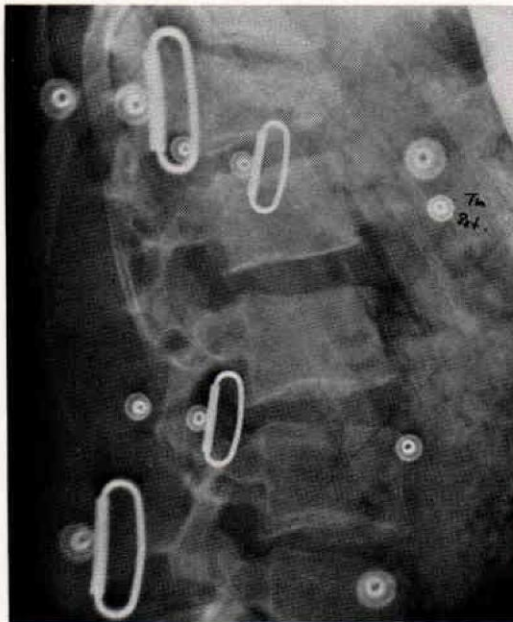

Fig. 15. Standing lateral X-Ray view of Case No. 1 in extension in total-contact TLSO.

*Orthopedic Resident, Department of Orthopedic Surgery, SUNY, Upstate Medical Center, Syracuse, New York.

References

- (1) Norton, P.L. and Brown, T., "The immobilizing efficiency of back braces—their effect on the posture and motion of the lumbo-sacral spine," *J. Bone and Joint Surgery*, 39A:111-139, January 1957.
- (2) Van Hanswyk, E.P. and Bunnell, W.P., "The orthotic management of lumbar lordosis and the relationship to the treatment of thoraco-lumbar scoliosis and juvenile kyphosis," *Orthotics and Prosthetics*, Vol. 32, No. 2, pp. 27-34, June 1978.
- (3) Blount, W.P., "Non operative treatment of scoliosis with the Milwaukee brace," *Manitoba Medical Review*, 45: pp 478-480, October 1965.