

## AN ADJUSTABLE PLASTIC THIGH SECTION AND KNEE JOINTS FOR FEMORAL-FRACTURE ORTHOSES

Vert Mooney, M.D.<sup>1</sup>, George Irons, C.P.O.<sup>1</sup>  
Michael Quigley, C.P.O.<sup>1</sup>

The terms "fracture orthosis" or "cast brace" are used to describe a device that provides circumferential support to a segment of a fractured limb while allowing mobility of nearby joints, and thus early functional ambulation.

Fracture orthoses were first mentioned in the literature in 1855, in Henry H. Smith's article entitled "On the Treatment of Ununited Fractures by Means of Artificial Limbs" (8). Delbert recommended the use of a spring loaded fracture orthosis around 1900, but the use of these devices for fracture treatment was not considered seriously until 1961, when Dehne (2) introduced the concept of ambulatory treatment for tibial fractures. The work of Sarmiento (5, 6) and Brown (1) was reported a few years later, and by 1970 the concept was extended to fracture treatment of the distal femur (4, 7).

In the 1970 article (4) we stated, "It is essential, we believe, that the cast brace be a total contact device which is applied as far proximal as possible on the thigh and is suspended so that there is no opportunity for distal displacement." Total contact is desirable in order to effectively enclose the tissues to prevent them from expanding when axial loading is applied to the bone and to offer additional stability by allowing the muscles to work against the firm enclosure.

The timing of ambulatory care for femoral fractures is a medical judgment and varies widely, based on the experience and attitude of the clinician relative to the purpose and function of ambulatory care. Many factors, such as the degree of bone comminution, shortening which occurs out of traction, inherent stability of the fracture site, and other associated injuries which limit ambulation, interweave so that no specific rule can be outlined as to timing of application. The fracture orthosis may even be used as an auxiliary support

system for fractures which already have internal fixation by either rod or plate but for various reasons are not sufficiently stabilized by the fixation.

There were various problems associated with application of the previously described technique (Fig. 1) (4, 7). Total contact was lost when thigh atrophy occurred, often necessitating a cast change. Proper placement of the metal knee joints and shaping of the joint uprights caused problems when an orthotist was not available. Another disadvantage arose in the use of a quadrilateral shape at the proximal cast, requiring a separate molded plastic brim, a forming device, or hand forming the mold. Usually, two hours or more were required to apply the fracture orthosis. The method described below attempts to alleviate these problems.

### COMPONENTS

The critical component is a pre-molded, quadrilaterally shaped thigh support (Fig. 2). Through experience it has been determined that three sizes (small, medium, large) will fit nearly all patients. Eighty percent of all patients can be fitted with the medium size. Because the brim is molded according to contours at the root of the leg, either a right or left thigh section must be used. The plastic chosen for this portion is polypropylene because of its well demonstrated toughness and resistance to tearing. Multiple perforations in the plastic are necessary, however, to allow the skin to "breathe." The tongue is of polyethylene which is slightly more pliable than the polypropylene. Three elastic-backed web belt straps are used. They are riveted to the posterior portion of the thigh section, but are fully adjustable to any position.

The knee joints are the flexible polyethylene joints originally designed at Tripler Army Hospital to substitute for the more expensive, and

<sup>1</sup>Amputee and Fracture Service, Rancho Los Amigos Hospital, 7601 East Imperial Highway, Downey, California 90242

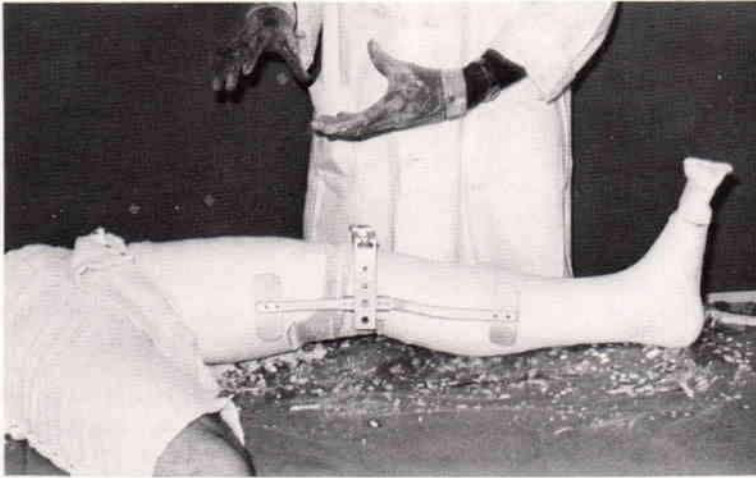


Fig. 1. The previously used technique (7) that required special alignment tools, bending irons, hose clamps, proximal brims, and a thigh cast.




Fig. 2. Components unassembled. From top to bottom, quadrilateral thigh section with adjustment holes, polyethylene tongue, polyethylene knee joints, elastic-backed web straps. Components are delivered assembled.

often unavailable, metal polycentric hinges. For this particular application they are ideally suited because the multiaxis motion of these joints makes alignment far less critical. Furthermore, since motion is not biased in any direction, the joints will not bind if they are not parallel as is the case when the thigh portion is tightened to maintain total contact. The joints are fixed to the plastic thigh portion with screws. Considerable adjustability is available in terms of proximal-distal length as well as anterior and posterior positioning so that proper location in the coronal mid-line can be achieved.

Additional components are not critical and are quite variable. A Spandex cast sock is ideal for under both the plastic and plaster portions. In that no tissue compression need be achieved by the initial dressing, tube stockinet may serve just as well. Standard plaster-of-Paris bandage is used for the lower leg portion. There is no advantage in use of elastic plaster-of-Paris bandage here. When particularly hard wear or uncontrollable moisture is expected, the use of a plastic laminate is appropriate as an alternative for plaster-of-Paris.

In summary, the new components have the following advantages:

1. Total contact is always available because the straps and flexible brim can be tightened when atrophy occurs, thereby saving cast changes.
2. There is no need to use a separate brim which must be incorporated in the cast.
3. The orthosis is lighter than the earlier type, can tolerate draining wounds, and makes wound dressing easier.
4. No alignment tool is needed. Plastic joints do not need to be square when applied, and will not bind as they lose parallel orientation when the thigh portion is tightened.
5. No shaping of joints is needed. Flexibility of the plastic joints allows them to fit flush on the cast without use of bending irons.
6. Varus and valgus adjustments can be made. Extra holes on the thigh section where the joints attach allow angular and A-P adjustments simply by removal of two or four screws.

#### THE TECHNIQUE

The following materials are needed:

- 4 each 4-in. standard plaster bandages

- 6 each 3-in. standard plaster splints  
 1 each Spandex cast sock or tube stockinet  
 1 each Molded plastic thigh section<sup>2</sup> with polyethylene hinges.<sup>3</sup>

These are available in three sizes: small, 7- to 11-in. length, 16- to 19-in. circumference; medium, 8- to 12-in. length, 19- to 23-in. circumference; and large, 9- to 13-in. length, 23- to 28-in. circumference. Length is measured from the adductor tubercle to a point one inch distal to the perineum; circumference is measured at the level one inch distal to the perineum.

Because minimal special equipment is necessary for the application of the fracture brace, the work can be accomplished in the emergency room, cast room, or even the patient's own room. The traction pin can be removed if the fracture has reached skeletal stability. If there is the expectation the fracture may need additional traction, the traction pin in the tibia should be left intact and incorporated in the plaster-of-Paris cast.

The stockinette or Spandex cast sock is rolled on the leg as high into the groin as possible. If drainage is present, bandages should be on the outside of the stockinette so that they may be changed as necessary (Fig. 3).

The plastic thigh portion is placed as proximal as possible up the leg so that the buttock fold matches the posterior portion of the folded thigh section (Fig. 4). The straps are tightened and the alignment of the plastic joints is confirmed to be parallel to the sagittal plane and slightly posterior to the mid-coronal plane.

For the lower leg and foot, Webril is applied over the cast sock or stockinet. Inclusion of the foot is not necessary if the traction pin remains intact since the pin will keep the system from sliding distally. An initial layer of 4-in. plaster-of-Paris bandage is applied. Several thicknesses of 3-in. plaster splints are overlapped around the distal portion of the plastic joints and these in turn are incorporated with additional rolls of

<sup>2</sup>U.S. Manufacturing Company, 623 S. Central Avenue, Glendale, California 91209; Orthomedics, Incorporated, 8332 Iowa St., Downey, California 90242

<sup>3</sup>Ultra High Molecular Weight (UHMW) Polyethylene

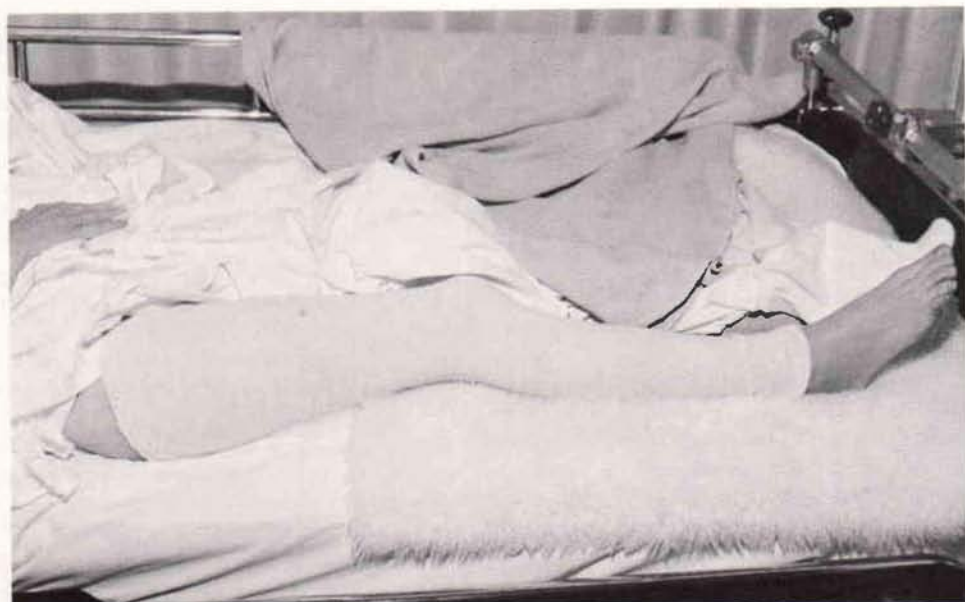

Fig. 3. Stockinet or a Spandex cast sock is rolled on the leg. Traction pins were removed in this instance but should be left intact if further traction is expected.

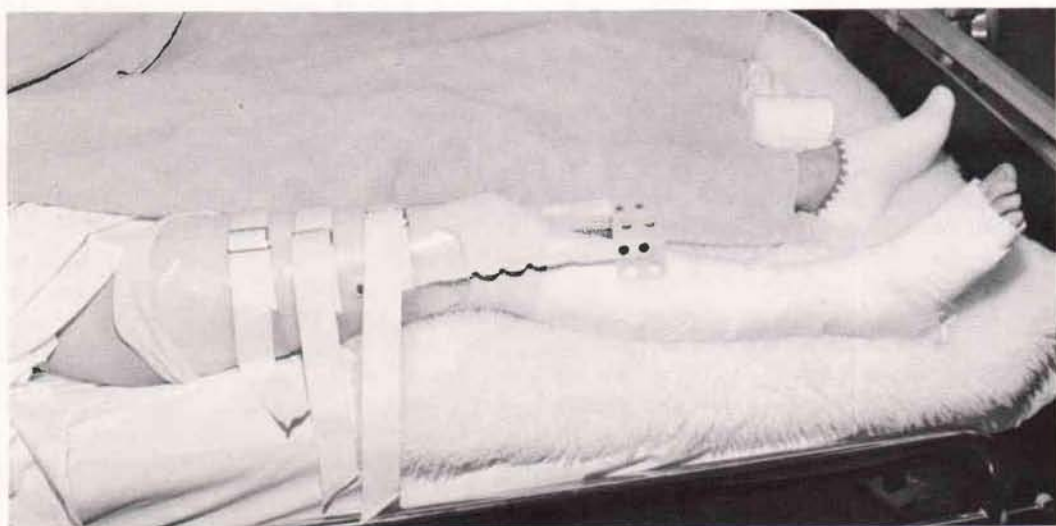


Fig. 4. Plastic thigh section is located properly on the thigh and the straps are tightened.

plaster-of-Paris bandage into a complete total contact plaster (Fig. 5). The foot should be held in neutral position both from the standpoint of plantar and dorsiflexion as well as varus and valgus so that weight-bearing to the limb is with the foot in its physiological position.

Excessive belt material is cut off. The patient is instructed in tightening and loosening the thigh section, and lines are drawn along the buckles with a ball point pen to identify the tightness. In time, these can be tightened as atrophy occurs.

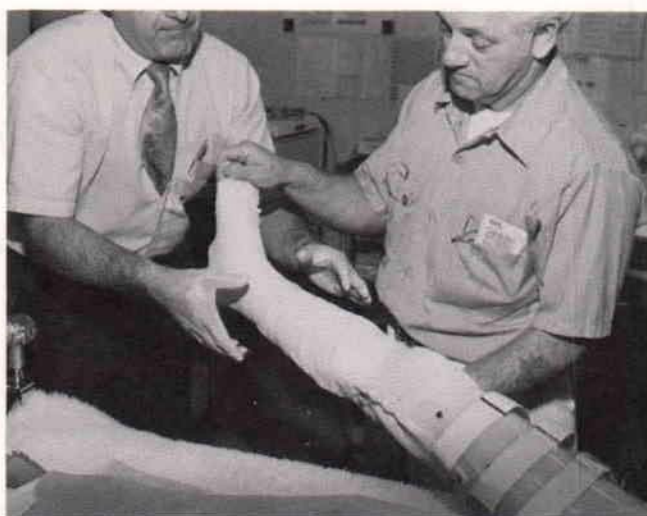

Fig. 5. Plaster is applied to the leg with the foot maintained in a neutral position. Once the initial wrap is set, the attachment plates of the joints are wrapped in the cast.

The patient can start to ambulate on the fracture orthosis the following day, once the plaster has had sufficient time to harden (Fig. 6). When the patient is recumbent at bed rest the belts may be loosened to allow the skin to "breathe" and dressings to be changed as necessary. Whenever the patient uses the limb to stand or become ambulatory, however, the belts should be tightened to the previous degree of tension.

#### EXPERIENCE

This method of adjustable fracture bracing has been used for over fifty patients at Rancho Los Amigos and Martin Luther King Hospitals (3). It has been applied both as a suspension method while the patient is in traction and as a definitive fracture orthosis when the patient becomes ambulatory following the discontinuation of traction care. In five patients it has been used as an auxiliary support system when internal fixation was felt to be inadequate or fracture healing lethargic. When the fracture has become nearly completely healed, the lower portion of the orthosis can be removed, leaving the plastic thigh section to give additional support during the final fracture maturation.

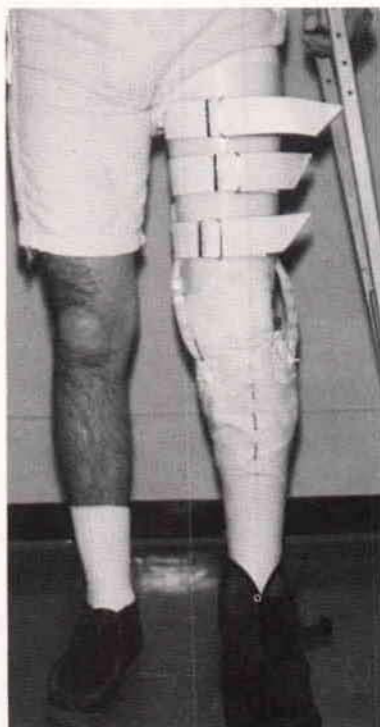

Fig. 6. The patient is instructed to keep the straps tight whenever he uses the limb, and is allowed to ambulate the following day.

## SUMMARY

A simplified method of fracture orthosis care has been described. It is lightweight and adjustable, and can be applied with less specialized equipment and knowledge than with previous designs.

## ACKNOWLEDGEMENT

Mr. Hank Meyer, Engineer and Plant Superintendent, U.S. Manufacturing Company, was of great help during the development of the components by searching out new materials and providing prototypes of the knee joints.

## REFERENCES

1. Brown, P. W. and J. G. Urban, *Early weight bearing treatment of open fractures of the tibia*, J.B.J.S., 51-A:1, pages 59-75, January 1969.
2. Dehne, E., P. A. Deffer, R. M. Brown, and E. V. Johnson, *The natural history of the fractured tibia*, S. Clin. North America, 41: 6, pages 1495-1513, December 1961.
3. Lesin, B., V. Mooney and M. E. Ashby, *Second generation cast bracing: a preliminary report*, Presented at the 1975 Meeting of the Western Orthopaedic Association.
4. Mooney, V., V. L. Nickel, J. P. Harvey, Jr., and R. Snelson, *Cast brace treatment for fractures of the distal part of the femur*, J.B.J.S., 52-A: 8, pages 1563-1578, December 1970.
5. Sarmiento, Augusto, *A functional below-the-knee cast for tibial fractures*, J.B.J.S., 49-A: 5, pages 855-875, July 1967.
6. Sarmiento, A. and W. F. Sinclair, *Application of prosthetics-orthotics principles to treatment of fractures*, Artif. Limbs, 11:2, pages 28-32, Autumn 1967.
7. Snelson, R., G. Irons, and V. Mooney, *Application of cast brace for post acute care of lower extremity fractures*, Ortho. and Pros., Vol. 24: No. 4, pages 21-26, December 1970.
8. Smith, Henry H., *On the treatment of ununited fractures by means of artificial limbs*, Am. J. of Med. Sci., June 1855.