

# An Innovation in Symes Prosthetics

by

Herbert W. Marx, C.P.O.<sup>1</sup>

For many years, the prosthetist as well as the amputee were faced with the problems of low-level amputation. Many attempts have been made to provide the amputee on whom the Symes or other low-level amputation has been performed, with a suitable prosthetic device. Since early designers seemed to be concerned with replacement of lost motion rather than with intimacy of fit and restoration of cosmesis, the conventional Symes prosthesis left in most cases something to be desired. However, the introduction of plastic laminates to the prosthetic profession not only multiplied and improved the ways with which the

prosthetist could accomplish more accuracy in fit, it also gave him the tool for improving the cosmesis without the addition of weight to the prosthesis. Even though the use of steel reinforcements in the construction of plastic prosthesis appeared to be of necessity at first, it was soon learned that the proper use of plastics would provide enough strength to replace all weight-adding steel reinforcements. The first all plastic Symes prosthesis which did not require any metal reinforcements, was the Canadian design, introduced in 1956. It is still the most widely accepted design for this level of amputation. However, the bulbousness of this type of prosthesis combined with the rather slim appearance in the calf region is objectionable, especially to the female patient. The unsatisfactory

<sup>1</sup> Assistant Research Scientist, N.Y.U. School of Medicine and Post Graduate Medical School and Supervisor, Orthotics and Prosthetics Laboratory, Institute of Rehabilitation Medicine, N.Y.U. Medical Center.

cosmesis as well as the posterior opening on this prosthetic device gave the initiative for the search of improvements. One of these improvements was the elimination of any opening, whether lacing or otherwise, in any region in the middle half of the socket. Since the nature of this type of amputation requires a wider socket diameter than stump diameter in the middle third of the shank, the fitting was based on total contact in distal and proximal weight-bearing areas only. An edema in the middle two thirds of the stump was frequently discovered. To eliminate this medical problem, an entirely new approach was necessary. A double-wall socket construction with a flexible inner shell seemed to be the most logical solution.

To improve cosmetic as well as functional characteristics of this type of prosthesis the following total contact Symes technique was developed:

## CASTING

For casting, the use of elastic plaster bandages is of extreme importance because it assures the required even compression of redundant tissue, and, consequently, a more accurate cast.

The use of  $\frac{1}{8}$  inch adhesive felt patches applied to the bony prominences before casting appears to be superior to modifications made in these critical areas on the male mold. The measuring technique consists mainly of principles applied in casting a PTB prosthesis. In addition, peripheral measurements, starting at the patella-tendon level in two incre-

ments distally, should be taken. The length measurement, medial-tibial-plateau to end of stump is taken after the distal portion of the stump is wrapped and the bandage hardens under moderate weight bearing, thus establishing the fit of the distal portion in the final product. For this procedure, an adjustable height block similar to the one designed at the Prosthetic Service Center in Toronto is used, not only to maintain the patient in perfect balance but also to establish the amount of necessary elevation. Both the length measurement and the amount of elevation must be recorded. Applying the Patella Tendon Bearing principle in casting of the proximal two-thirds will satisfactorily distribute the weight between the distal and proximal portion.

Since the rubber-like properties of the material used for the construction of the flexible inner shell do not permit frictionless entry without a sock, the thickness of the sock to be worn by the patient is taken into consideration during casting.

To give additional assurance of accuracy of fit, a check-negative may be constructed. However, an opening should be provided in the medial, lateral or posterior mid-portion of this check-negative to provide ease of entry. The material which has been cut away to provide the opening should be re-inserted after the patient has stepped into the socket. Insufficient contact or excessive pressure at any one point in the check-negative may be checked through  $\frac{1}{2}$  inch holes drilled through the

socket walls. To assure a good weight bearing distribution between the proximal and distal portions, the patient should stand with even weight bilaterally for approximately 15 minutes on this check-negative. If reference lines in the frontal and saggital planes were not established at the initial casting, they should be established now and used as alignment guides during static alignment. The negative might then be removed and the skin checked for indications of excessive pressure in either distal or proximal portions. Necessary adjustments, such as adding or removing material, can be done on this negative, which might then be used as form for a new positive mold.

## LAMINATION OF THE DOUBLE-WALL SOCKET WITH FLEXIBLE INNER SHELL

After the vertical reference lines have been transferred from the check-negative to the male-mold and marked with roundhead screws or nails driven into the proximal and distal sections, the cast is sealed in the conventional manner with a PVA bag. For the fabrication of the inner shell, 4 layers of nylon stockinette are applied to the sealed cast. The PVA bag, which is then pulled over the work piece has to be taped distally and proximally as shown in figures 1 and 2. Taping off of these regions has been found necessary to prevent the flexible plastic which will be used in the center section from penetrating too far into them.

(The distal and proximal sections will be laminated with rigid or semirigid plastic after the flexible part has cured.) The PVA covering in the center section is then removed. Care must be taken, that the layup is not cut during this procedure. A third PVA bag is pulled over the work piece. A mixture of silicone elastomer 384 and 385 in proportions 80 per cent to 20 per cent is used for the lamination of the center section. It is advisable, not to use more than 20 per cent of No. 385 silicone elastomer, because a higher percentage of this material will result in excessive foaming action, which will not only be hard to control, but it will also reduce durability of the center section in the final product. A higher percentage of silicone elastomer No. 384 is not desirable since expandability of this material will be reduced. After the flexible material has cured, the PVA covering is removed completely. Figures 3 and 4 illustrate the anterior and medial view of the flexible center section with the PVA covering removed. A new PVA bag is then applied and the distal and proximal portions laminated with a 75 per cent to 25 per cent mixture of 4110 and 4134 laminac or similar material. While laminating, all material has to be strung out of the flexible portion because any rigid plastic left in this area may decrease its durability.

Cosmesis and necessary rigidity of the prosthesis will depend on the outer shell which will be constructed in a similar fashion as is the outer shell of a double-wall socket of an upper extremity pro-

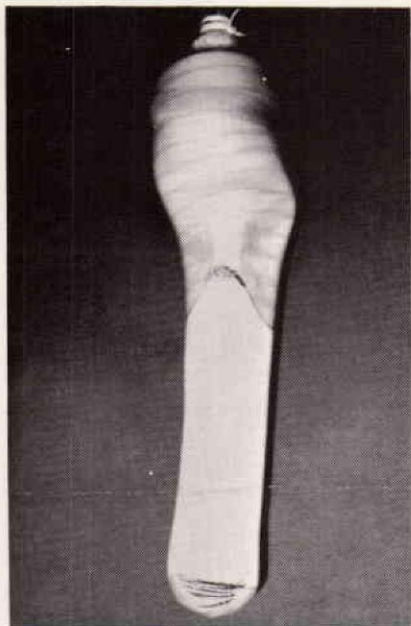


FIGURE 1

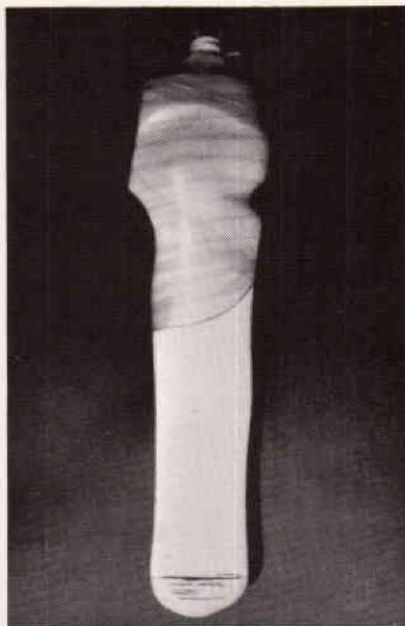

FIGURE 2

FIGURES 1 and 2—Preparation of first lay-up for silicone impregnation. (Anterior and lateral view).

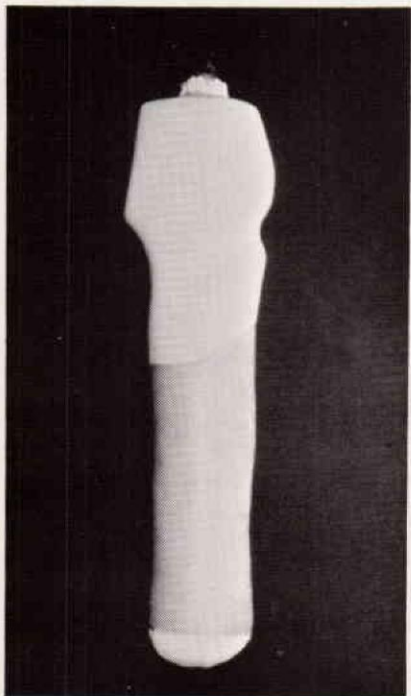


FIGURE 3

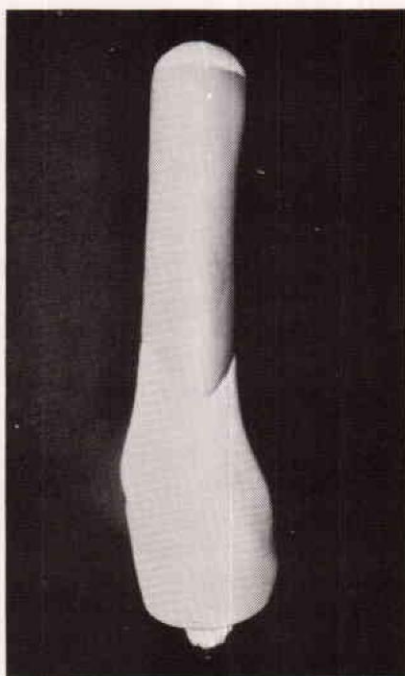


FIGURE 4

FIGURES 3 and 4—Flexible center section of inner shell with PVA covering removed.

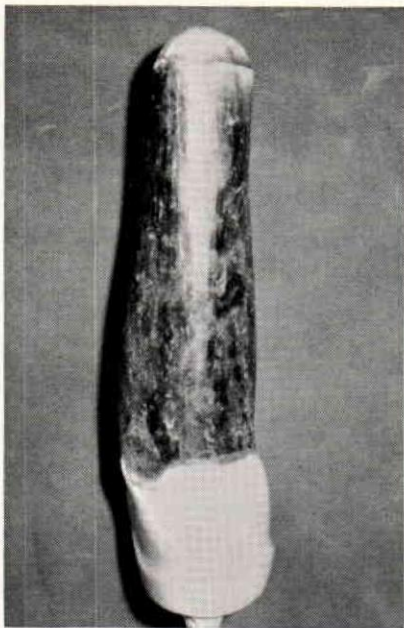


FIGURE 5

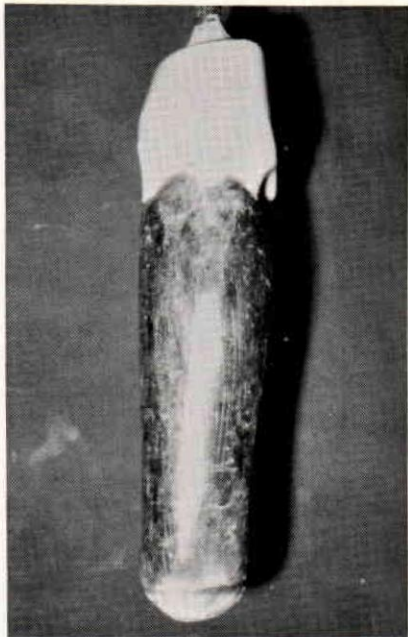


FIGURE 6

FIGURES 5 and 6—Wax built up over laminated inner socket.

thesis. A wax build up, as shown in figure 5 and 6 will give the necessary backing for the outer shell. It is of utmost importance to build a paper or celluloid sleeve around the work piece, into which the soft wax can be poured. We found, that if the cosmetic backing is built up with semi-soft wax, airpockets within the wax build up are usually unavoidable. While laminating the outer shell, these airpockets will fill up with plastic residue. Since these plastic accumulations can not be removed from between the two laminations, they will not only interfere with the expansion of the flexible inner shell but also introduce the possibility of discomfort for the patient.

After the wax has hardened it is shaped down to the necessary di-

mensions. The originally recorded dimensions of the sound leg should be reduced by  $\frac{3}{8}$  to  $\frac{5}{8}$  inches and then duplicated on the wax build up. To assure minimum weight and maximum strength of the final product, an epoxy lamination is preferable. Five layers of fiberglass, either tubing or matting, will provide sufficient strength. Before laminating the outer shell, it is advisable to roughen the distal and proximal portion of the first lamination to assure proper bond in these areas. To remove the wax build up, a  $\frac{3}{8}$  inch hole may be drilled through the outer shell in the lower popliteal area. The wax may be melted in an oven and drained through this hole. Because of the bulbousness of this type of amputation, we found it very difficult to re-

move the male mold from the laminated work piece. In most cases the cast has to be fractured and removed piece by piece. This should be done while the wax build up is still between the two laminations since it will provide a little more rigidity to the flexible middle section of the inner shell.

For length adjustment and easier alignment, a 3 inch wooden block is fitted and adhered to the distal portion of the laminated socket.

The base of this wood extension is removed as far as possible without disturbing the socket itself. Removal of this excess material should be done in consideration with the established flexion and adduction angle. Since only minor modifications in the angular relationship during dynamic alignment are possible, special attention should be given to this procedure.

## SACH-FOOT MODIFICATIONS

Since the loss of length in a Symes amputation amounts to approximately three inches, it does not appear necessary to use a foot designed solely for the construction of this type of prosthesis. However, a standard SACH foot can be used. Figure 7 illustrates one way of utilizing the limited space available for SACH foot attachment.

The SACH-foot keel, weakened by the removal of material from its base, has to be reinforced. This is accomplished by means of a hardwood plug, in dimensions outlined in Figure 7, inserted from the

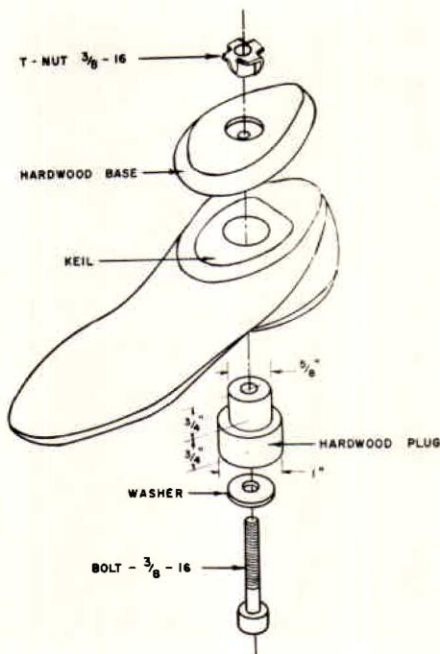


FIGURE 7—Exploded view of SACH foot modification for Symes adaptation.

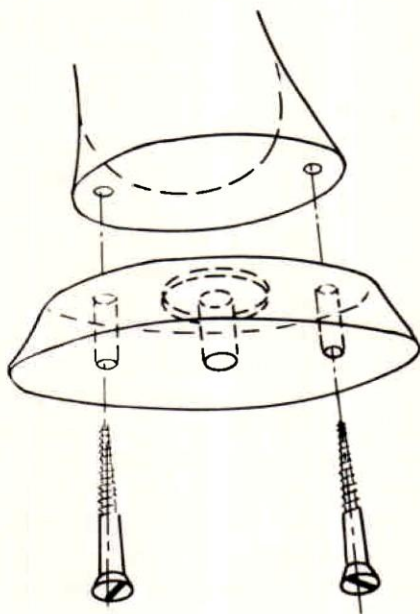


FIGURE 8—Attachment of hardwood base to socket base for dynamic alignment.

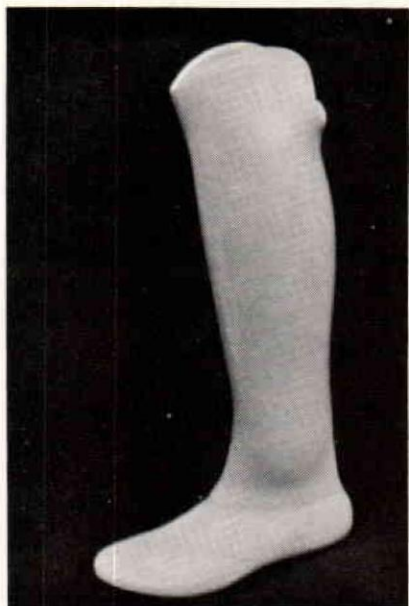


FIGURE 9

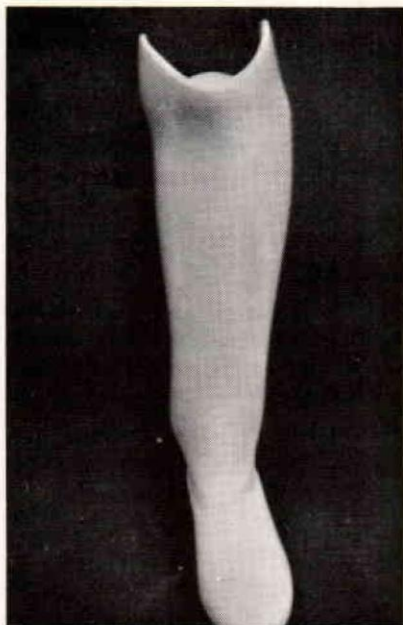


FIGURE 10

FIGURES 9 and 10—Finished Symes prosthesis.

underside into the foot. A hole is drilled into the center of this wood-plug to accommodate the foot attachment bolt.

Static alignment is done in the conventional manner. It is advisable to attach the hardwood ankle base with two wood screws No. 10-1¼ inch to the socket base (figure 8), since this arrangement allows easier alignment changes in the transverse plane. Alignment changes in flexion and extension as well as adduction and abduction angles should not be excessive if reference lines in the frontal and saggital planes have been established and transfered properly, and can be done at the socket base. Finishing the prosthesis after dynamic alignment is simply a matter of blending the ankle portion and applying the final lamination

in the conventional manner. To improve the cosmesis, the medial and lateral apexes of the bulbous ankle area may be sanded down to paper thickness, before the final lamination is applied, since these areas are not under excessive stress during gait cycle, and consequently do not require as much reinforcement as the anterior and posterior sections.

## SUMMARY

Limited expansion (approximately 1¼ to 1¾ inch, in the material required for a Symes prosthesis) of the silicone elastomer laminated inner shell, does not permit this technique to be used for all types of low-level amputations. The only three types of amputations for which this technique may possibly be used are

the Symes, Pyrogoff and Boyd amputations. However, different foot modifications are necessary on other than the Symes socket, because of difference in amputation level with its resulting length discrepancy also involves a difference in construction of the foot replacement. In general, the applicability of this technique depends largely on the dimensional difference between the distal circumferential measurement and any measurement more proximal to this point. It appears quite feasible to apply this type of TC construction in some cases of lower extremity congenital deformities or any amputation which results in distal scele-

tal bulbousness, as long as the maximum expandibility of the material is not overestimated.

A follow-up on patients provided with this type of prosthesis shows that the silicone elastomer used in proper proportions assures prolonged service. Inflating the air chamber between inner and outer shell was not found necessary. No material fatigue was found after the prosthesis has been actively used for more than 1½ years. According to patient reports, the cosmesis of this prosthesis is far superior to any other design, even though the bulbous ankle area could not be completely eliminated.

---

## REFERENCES

1. American Academy of Orthopaedic Surgeons, Inc. (Editors), *Orthopaedic Appliances Atlas*, Volume 2, J. W. Edwards Company, Ann Arbor, Michigan, 1952.
2. Maset Jr., Robert, M.D.: *Symes Amputation, A Follow-up of Fifty-one Adults and Thirty-two Children*, **The Journal of Bone and Joint Surgery Volume 50: A:8**, December 1968
3. Wilson Jr., A. Bennett: *Prosthesis for Syme's Amputation. Artificial Limbs*, April 1961
4. Sarmiento, Augusto, Gibner, Jr., Raymond E., and Finnieston, Alan: *A New Surgical-Prosthetic Approach to the Syme's Amputation, A Preliminary Report*