

The PTS Knee Brace

by

Robert O. Nitschke, C. P., Rochester, N. Y., and Kurt Marschall, C. P., Syracuse, N. Y.

Early in 1966 we initiated fitting patients with the patellar tendon supra-condylar prosthesis. It was immediately evident that the amount of flexion and extension of the stump during locomotion could be controlled through the high brimline and the intricate fit of the socket superior to the patella where the three vastus muscles and the rectus femoris unite to form the quadriceps tendon. By coincidence at this time, a female patient, suffering from extreme recurvatum of the right knee as a result of polio fifteen years ago, asked to be fitted with a long leg brace. She complained bitterly that the braces she wore before were cumbersome to apply to the extremity, excessively heavy, and most unsatisfactory of all, unsightly cosmetically with their bulky uprights, bands, and sharp protruding joints. Immediately

our curiosity was aroused as to whether the PTS principles were adaptable in this particular case. After securing the consent of the prescribing physician, we fabricated a light plastic knee brace, consisting of two half shells overlapping each other at their long axis, medially and laterally, and secured by four Velcro straps. This procedure, which has been duplicated since in many other cases, proved to be highly acceptable to this female patient cosmetically as well as functionally in preventing hyperextension of the knee with its accompanying pain.

THE CAST-TAKING PROCEDURE

Two women's nylon stockings and one cotton stockinette are applied to the patient's leg and secured with an elastic waist belt

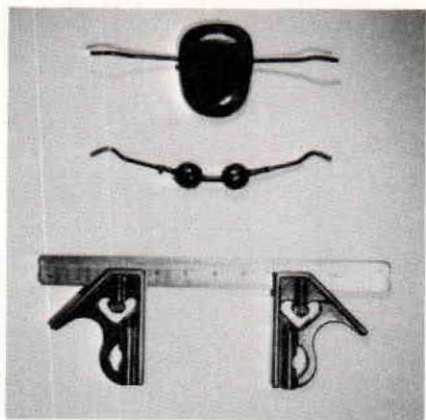


FIGURE 1—A.-P. tension clamp and M.-L. measuring device.

and clamps to prevent slippage. The following areas are then identified with indelible pencil: patella, level of tibial plateau, tibial tubercle, tibial crest, head of fibula, and the medial and lateral hamstrings. One M-L dimension is recorded at the level of the tibial plateau; a second one immediately above the femoral condyles. The proper A-P dimension is taken from mid-patellar tendon at a right angle to the popliteal area. For these measurements we use a special square consisting of one crossbar and two movable shanks (Fig. 1, Bottom). Three circumference measurements are taken for later reference on the positive mold starting with the first one just below the tibial flare. For casting, we use elastic plaster bandages only, beginning the wrap distally to the knee joint, continuing proximally to about two inches above the patella, applying only moderate tension to the bandage. Immediately above the patella, the bandage is twisted once 180° in such a fashion as to

create an indentation and firm pressure at the quadriceps tendon. Care should be taken at this point not to displace the patella downward. The wrap is then completed distally, well past the bulge of the gastrocnemius, and the A-P tension clamp is applied before the plaster hardens. In our opinion, the use of the A-P tension clamp (Fig. 1, Top), which can easily be fabricated in any facility, or the use of a Coleman tension clamp, is an absolute must to assure even compression and to free your hands for proper molding of the cast, particularly in the area above the femoral condyles. At this stage careful attention should be given to the amount of flexion desired, ranging from 15° to 25° in most cases. After the plaster has hardened, the A-P tension clamp is removed, and the cast is reinforced with regular plaster of Paris bandages. With a cast cutter, cut along the medial and lateral hamstrings to a point of ½" above the level of the tibial plateau. Then fold back the posterior flap to allow knee flexion. It is at this early stage that it is determinable whether the brace will be effective for the patient by using the cast on a trial basis. After that the cast can be removed by cutting along the long axis of the extremity, medially and laterally. The resulting two halves should be joined together again by use of an additional bandage. The negative cast is then filled in the conventional manner.

CAST MODIFICATION

After removal of the negative wrap, the three circumference measurements of the positive mold are compared with the measurements taken previously. If the patient's subcutaneous tissue is average, these measurements should be reduced by $\frac{1}{4}$ ". The A-P and M-L dimensions of the positive mold should coincide with the recorded measurements. If they prove to be larger, plaster should be removed without destroying the overall contour. Care should be taken not to remove any plaster from the bony protuberances. The crest of the tibia is built up $\frac{1}{16}$ " to $\frac{1}{8}$ " in its entire length. A generous flare is created at the popliteal aspect. The entire cast is then smoothed and sealed.

FABRICATION PROCEDURE

The layup for the anterior shell is as follows: Two layers of nylon stockinette are pulled over the whole cast with 6 layers of fiberglass in between. This fiberglass reinforcement should cover the entire length of the half shell but should be staggered in width from $\frac{1}{2}$ " to $3\frac{1}{2}$ " so as to provide the greatest strength along the tibial crest. For the lamination, a mixture of 60% Laminac 4110 and 40% Laminac 4134 is used. After this lamination has cured sufficiently, the outer PVA bag is kept in place and the layup for the posterior shell is begun. Since the posterior shell overlaps the anterior one by about 1" on both sides, it

should be somewhat stronger. Use, therefore, 3 layers of nylon stockinette and 8 layers of fiberglass. Again the fiberglass is staggered in width from 2" to 4". After this lamination has cured

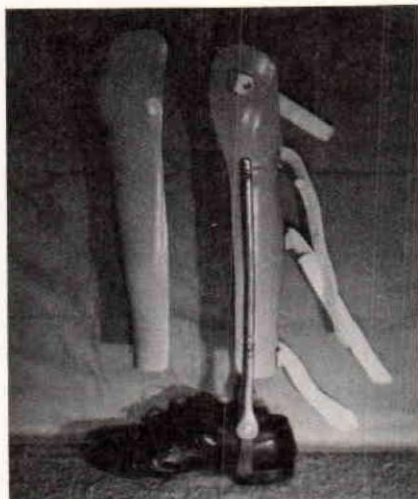


FIGURE 2—PTS Brace, anterior and posterior shell from a medial view.

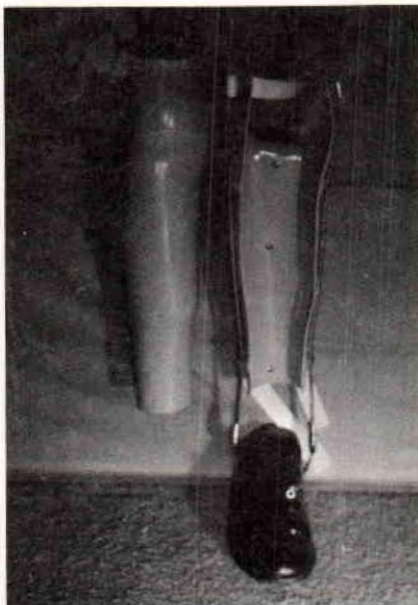


FIGURE 3—Anterior and posterior shell From an anterior view.

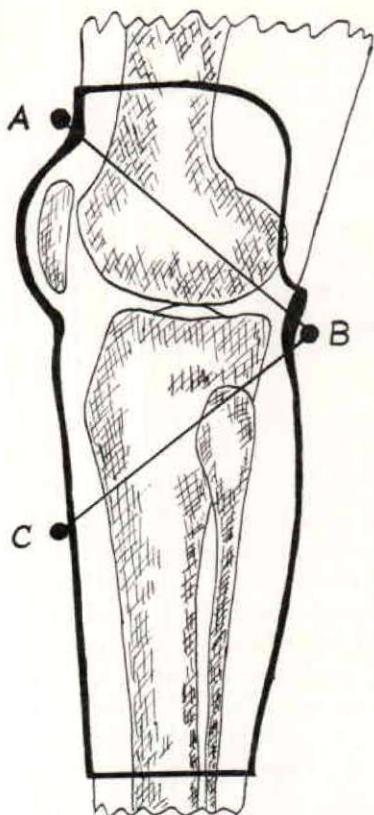


FIGURE 4—Pressure Distribution in the PTS knee brace.

sufficiently, the two halves can be removed from the master mold. In cases where the attachment of a short leg brace is necessary, the fiberglass reinforcement should cover more than half of the posterior shell (Fig. 2 and 3).

As previously mentioned, the two halves are trimmed so that they overlap each other by 1". The anterior superior brimline is kept purposely high in the beginning about 1½" above the patella. It is only lowered when it is established that no undue pressure is placed upon the quadriceps tendon. The posterior brimline is cut as

outlined by the mold. The distal brimline should run well below the bulge of the gastrocnemius. Three or four Velcro straps are usually enough to keep the desired tension between the two shells. It should be emphasized that the PTS brace should not be worn directly against the skin. A nylon or cotton underhose, cotton stockinette, or wool sock, should be worn underneath. In cases where the PTS brace is not attached to a short leg brace, it must be suspended by a light waist belt.

SUMMARY

The PTS knee brace encloses the medial and lateral femoral condyles in their entirety, thus assuring maximum stability. The desired degree of flexion is controllable by the intricate fit superior

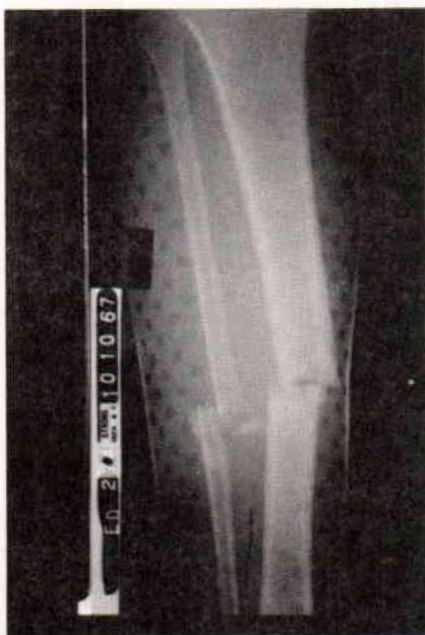

FIGURE 5—Fracture of tibia and fibula on 62-year-old male patient.

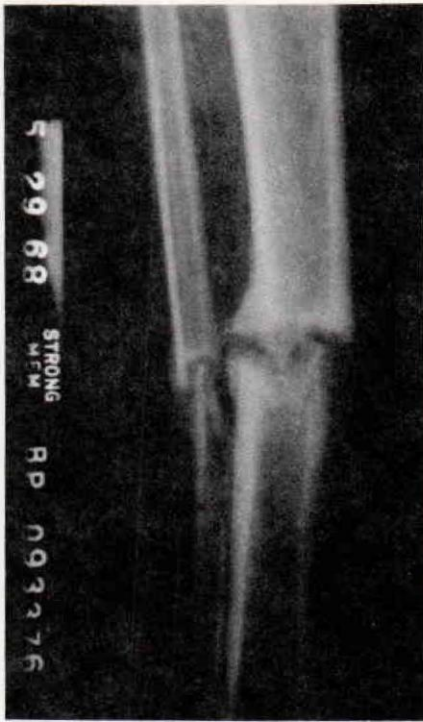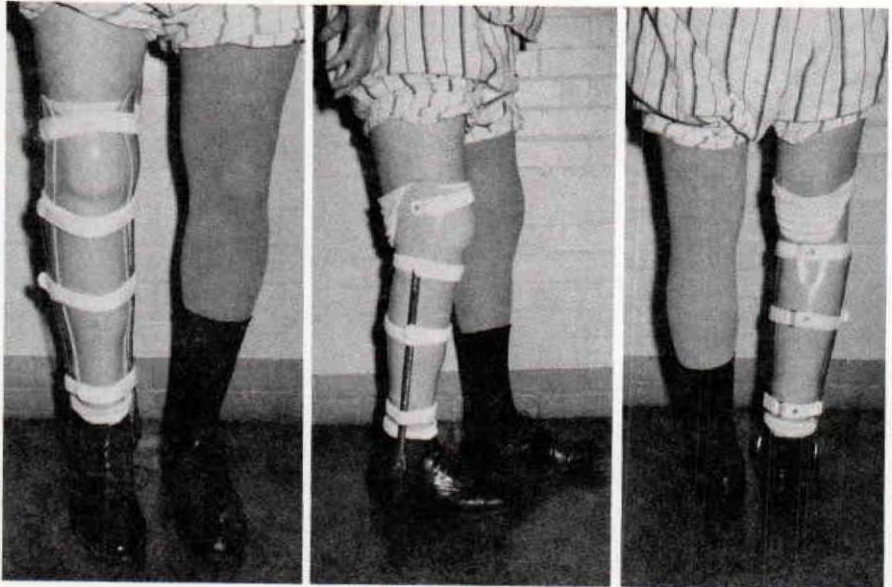


FIGURE 6—Same fracture after 7½ month.

to the patella at the beginning of the quadriceps tendon. To maintain the desired degree of flexion, three areas of pressure and counter-pressure are of the utmost importance: 1. Quadriceps tendon superior to the patella; 2. The entire area of the tibial crest; 3. The popliteal area (Fig. 4).

The PTS brace is fabricated in two plastic shells partially overlapping each other and secured with three to four Velcro straps. Since it is fitted intimately to the long structure of the extremity, its cosmetic appearance is superior to metal braces. If necessary, the brace can be easily connected to a short leg brace without increasing the weight appreciably.

Since 1966, the PTS knee brace, adapted from the PTS prosthesis, has been fitted in eight cases, each



FIGURES 7, 8, 9 PTS brace attached to short leg brace from anterior lateral and posterior view.

involving one of the following: fractures of the tibia and fibula immediately below the tibial flare; non-union or pseudarthrosis of the tibia; medio-lateral instability of the knee; and in cases of extreme recurvatum of the knee.

Figures 5 and 6 show you a 62-year-old male with fractures of the right tibia and fibula about 8" below the tibial plateau. He

remained in a cast from October, 1967 until May, 1968. He was then placed in a PTS knee brace with short leg brace attachments. He is now ambulating under full weight bearing without auxiliary aids, and X-rays show a marked increase in callus formation. (Fig. 7, 8, 9)

X rays and photographs courtesy of Dr. William Boger, Strong Memorial Hospital, Rochester, N. Y.