

The P. T. S. Prosthesis

(Complete enclosure of patella and femoral condyles
in below knee fittings)

By KURT MARSCHALL, C.P., *Syracuse, N. Y.* and
ROBERT NITSCHKE, C.P., *Rochester, N. Y.*

The UCB prosthesis, or PTB prosthesis, as it is more commonly known, has undoubtedly enjoyed widespread popularity with patient and prosthetist in recent years. It has solved many problems which could not have been overcome with the conventional BK prosthesis, although it has not claimed to be the "cure all" for all types of amputations, especially not for extremely short stumps (4" or less) or for patients whose work requires them to carry heavy loads over uneven ground (farmers, construction workers, etc.). A suspension strap is needed to hold the PTB in place and very often a light waist belt is used to minimize piston action.

Many attempts have been made to eliminate the suspension strap. It was two years ago, on a study trip abroad, that I first came in contact with two types of prostheses that utilize the suspensionless fitting method. One was developed by Dr. G. G. Kuhn at the Research Institute in Muenster/Westfalen, Germany, showing high enclosure of the femoral condyles but complete exposure of the patella (KBM Method).

The other type was first introduced in theory and practice by Guy Fajal of Nancy, France, at an International Seminar on Prosthetics in Copenhagen, Denmark in 1964. Fajal calls it a PTS prosthesis because of its patellar and supracondylar enclosure without any further suspension aid above the knee. It is his method we shall discuss here with due credit to Mr. Fajal for his pioneer work in and development of this particular type of prosthesis.

Before we present some of the cases that have been fitted by us at our prosthetic facilities in Syracuse, N. Y. and Rochester, N. Y., we should like to point out several specific advantages of the PTS prosthesis:

1. Relationship Between Socket and Stump

The socket of the PTS prosthesis encloses the patella frontally and the femoral condyles medially and laterally completely. The anterior brim line is brought in direct contact with the tendon of the quadriceps, thus eliminating the need for any suspension above this level.

2. Increased Knee Stability

It is this intimate, intricate and high enclosure that affords piston action free contact with the stump and a maximum of medial and lateral knee stability. It provides the patient with the incalculable comfort of not being restricted above socket level while standing, walking or sitting.

3. Normal Knee Flexion and Swing-Through

The correct fitting of the area of the quadriceps tendon as a main source of suspension can not be stressed enough. Its proper flare contributes to a smooth swing-through and normal knee flexion in the stance phase.

4. Ideal for Short Stumps

The high walls decrease the amount of pressure taken per square inch of stump surface. Stumps of extreme shortness, which frequently were rejected for fitting with a PTB, can be accommodated with the PTS prosthesis in most cases. Also, we found it advantageous to use this type socket for fitting the below knee amputee with the temporary prosthesis.

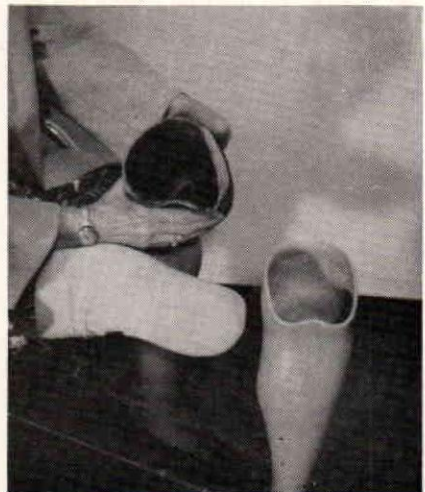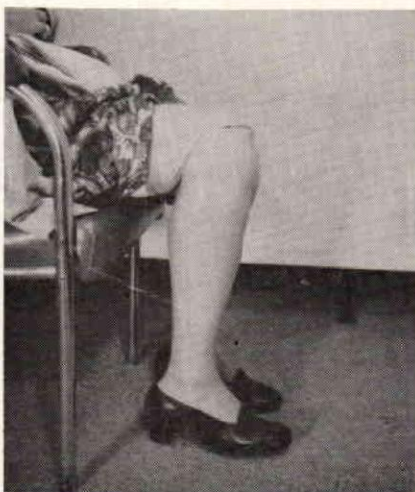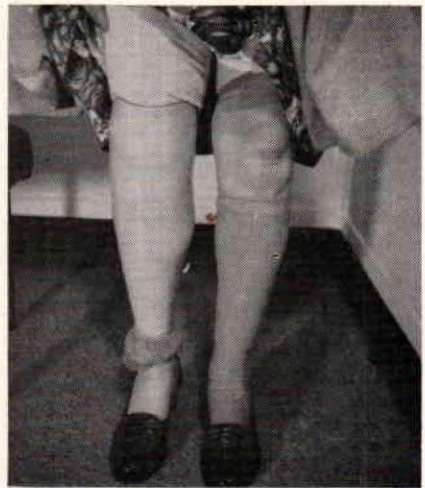5. Cosmesis

Due to its high brim line and strapless suspension, the PTS is excellent in its cosmetic appearance and should appeal especially to young girls and women.

Success or failure in the construction of the PTS prosthesis hinges largely on the correct taking of the negative plaster mold. Very often we have taken two or three casts, using each one as a trial socket, retaining the one that proved the most satisfactory to us as well as to the patient.

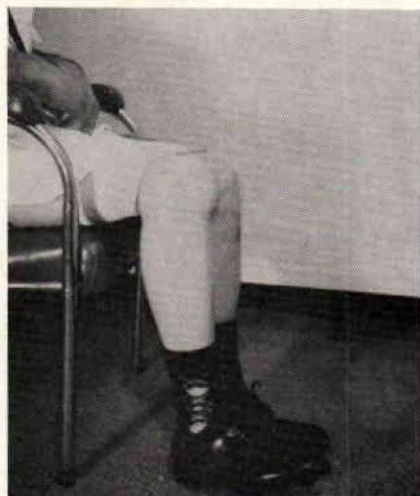
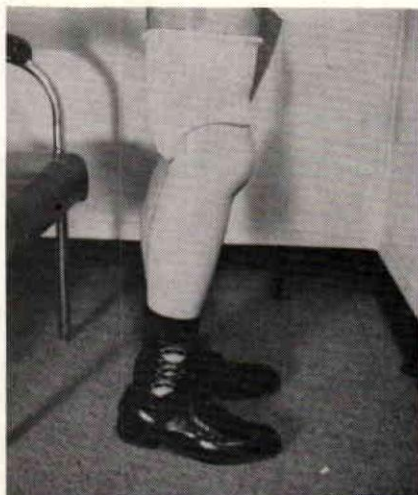
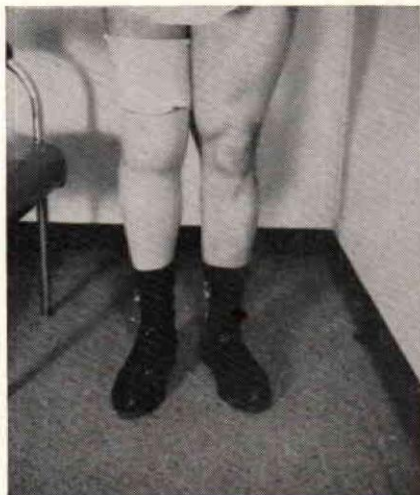Another point of equal importance while first experimenting with this

Case 1. Shows 58 year old female, housewife, amputated since 1965 with 6" bulbous stump in standing and sitting position. She also has traumatic wrist disarticulation since age 16.



CASE #1

CASE #2

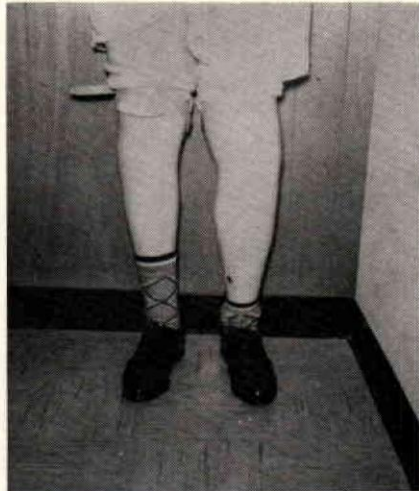
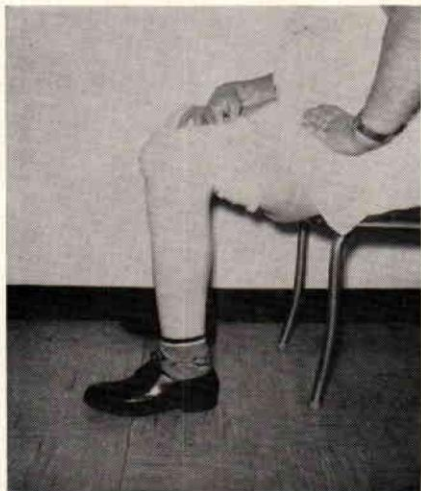
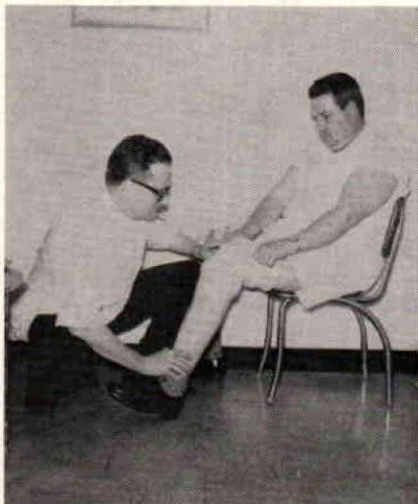


new type of prosthesis was communication with the patient. We made it a rule with every amputee, new or old, to explain to him what we tried to accomplish, what we were looking for and what he had to expect in the process of fitting. We did not use layman's language, but proper nomenclature, which was picked up readily by the patient, stimulated his interest and gave him a feeling of importance that assured us of his utmost cooperation.

The fabrication procedure of the PTS prosthesis is identical with the one used in fabricating a PTB. The purchase of new material or equipment is not necessary. The adjustable leg is still an important factor in proper alignment. A soft insert can be used for bulbous stumps (ease of donning the prosthesis) or a hard socket with soft end can be fabricated where excessive perspiration makes this kind desirable (ease of cleaning prosthesis).

Case 2, Shows 37 year old male, salesman, amputated since 1958 with 5" stump, fitted first with standard BK prosthesis. Wore PTB since 1963. Note the normal knee flexion in standing position and excellent cosmesis despite 10° of abduction.

CASE #3



Case 3. Shows a 36 year old male bilateral Korean War veteran who wore conventional prostheses since 1952. Fitted in 1962 with PTB prostheses. Developed an extreme case of dermatitis at the distal end of his left stump after that. Due to patient's heaviness, reverting to the conventional prosthesis on that leg was thought able to correct this condition; however, this was not the case. Was recently fitted with the PTS prosthesis on the left leg and patient reported considerable improvement of his skin condition due to better blood circulation (no strap or corset restriction).

Summary

Like the PTB, the PTS prosthesis of Guy Fajal does not solve all the problems of every below knee amputee; however, it presents a valuable and welcome addition to the family of BK prostheses. Because of its outstanding advantages it should become in the near future an integral part of every prosthetic facility.