

Fitting of Lower Extremity Prostheses Immediately After Surgery

By DIETER L. MOZER,

Chief Prosthetist and Orthotist

Centrallasarettet, Boras/Sweden—Chief: Docent Dr. F. Stahl

Introduction and Translation by WILLIAM A. TOSBERG

The following article on the "Fitting of Lower Extremity Prostheses Immediately After Surgery" was sent to the Editor of *Orthopedic and Prosthetic Appliance Journal* by Dieter L. Mozer.

Mr. Mozer is a dedicated and capable prosthetist in Boras, Sweden. I have known him for many years and have met with him at several International Prosthetics Training Courses. I have been very favorably impressed with his work and his interest in our profession.

In the article, Mr. Mozer writes about the experience of fitting lower extremity prostheses almost immediately after surgery. This concept of prosthetic fitting may offer many advantages. Professor M. Weiss, from Poland, showed a film in the United States in which a temporary prosthesis was applied to the patient under anaesthesia. In the Swedish approach the fitting is delayed for one day.

Although the paper by Mr. Mozer concerns only a limited number of patients, it covers a rather wide cross-section of lower extremity amputations. Therefore, this subject is timely and should be of great interest to all members of the prosthetic profession.

For a limited time we have been utilizing a new procedure in the prosthetics shop of our Clinic, the goal of which is to apply lower extremity prostheses to patients as soon as possible after surgery. We have been practicing this approach for slightly more than four months and have fitted nine patients. The diagnosis, age, and sex of these nine patients are listed below:

Cause of Amputation	Amputation	Age	Sex
Vascular insufficiency	BK	82	Male
Vascular insufficiency	AK	69	Female
Vascular insufficiency	AK	68	Female
Vascular insufficiency	BK	64	Male
Accident	BK	33	Male
Accident	BK	17	Male
Sarcoma	AK	18	Male
Congenital osteomyelitis	BK	29	Female
Congenital deformity	BK	15	Female

In the following I will elaborate on the steps which we follow. It is essential for a successful result with this method that the general health and condition of the patient make it possible for him to be able to walk independently (with crutches, if necessary) prior to surgery. In principle

it is essential that the patient assume a sitting position as soon as possible after amputation, either in bed or in his wheelchair. On the day after surgery the drainage tube is removed from the stump, the wound is covered with a compress, or compresses, and the whole stump is wrapped with a thin layer of elastic bandages. Over this a plaster cast is taken. The cast for an above-knee stump should be constructed in the accepted manner, although it is obvious that as a result of the edematous condition of the stump no marked contours can be achieved. A cast for the below-knee stump is made according to the PTB principle; i.e., with a slightly flexed knee joint. In order to avoid the PTB cuff suspension, one carries the cast slightly above the proximal border of the patellar (Fajal). This, in connection with the pear-shaped swollen end of the stump, provides a guarantee that the stump is well anchored in such a cast.

At this stage the stump is severely swollen. Amputation above the knee causes an edema of the total stump. In amputation below-the-knee, the areas surrounding the knee are relatively undistorted and the swelling is concentrated in the distal area. Since at this point, and for several more weeks, the proximal circumference of the stump is smaller than the distal, it is impossible to construct a conventional cast. The only alternative in this case would be to construct a split cast. For this purpose one proceeds as follows:

The cast (negative) is trimmed and modeled from the inside. This is essential in the case of above-knee stumps. Following this the positive cast is constructed and modified in the accepted manner. The positive model is covered with Molton, or thin felt. A sponge plastic pad of the thickness of approximately 20 mm. (4/5 inch) is placed over the end of the stump. Over this one or two plaster-of-Paris bandages are wrapped. An attachment plate with the four vertical metal pieces is fitted to the cast and is secured with one or two plaster-of-Paris bandages. After the cast is set it is cut medially and laterally and around the distal end of the socket, and the edges are smoothed down. The plate is attached to an adjustable leg (Hosmer, Habermann). The foot is attached and the prosthesis is ready for fitting, just one day after surgery. The simplest way of suspension is by means of tightening the two halves of the plaster cast by means of a bandage. The patient receives crutches or canes, and is now ready to make his first steps. Following this, ambulation training will take place systematically.

Starting from the first day, the patient receives Tanderil tablets which, in connection with ambulation exercises and constant compression of the stump, by means of stump shrinking socks or elastic bandages, brings about a relatively rapid atrophy of the stump. This necessitates the replacement of the first cast after two to four days. The time elapsing before a third socket is needed may be three weeks. Sometimes even a fourth socket will be necessary. After this the patient may be discharged from the hospital and for several weeks he is permitted to use his temporary prosthesis at home, after which time the stump is generally sufficiently atrophied that a permanent prosthesis can be constructed.

As a result of the frequent changes of sockets there is an excellent opportunity, especially with above-knee amputations, to influence the shape of the stump towards better function. The change from the plaster-of-Paris to the permanent socket and prosthesis is generally accepted as pleasant, since the temporary prosthesis is, as a rule, considerably heavier than the permanent one. This, however, has contributed to the strengthening of the musculature of the stump.

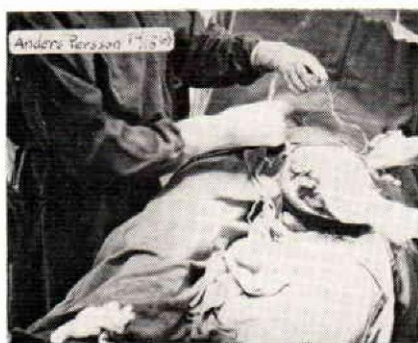


Fig. 1—Oct. 14, 1963

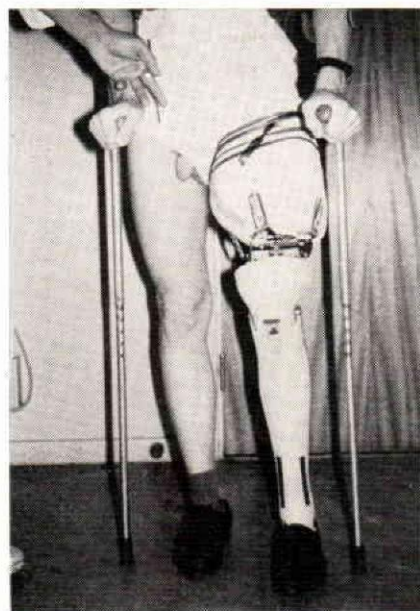


Fig. 3—Oct. 17, 1963

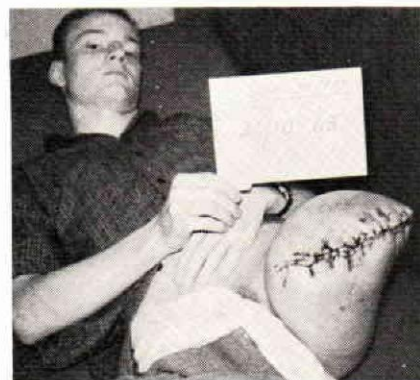


Fig. 4—Oct. 21, 1963

MALE A/K PATIENT



Fig. 2—Oct. 15, 1963

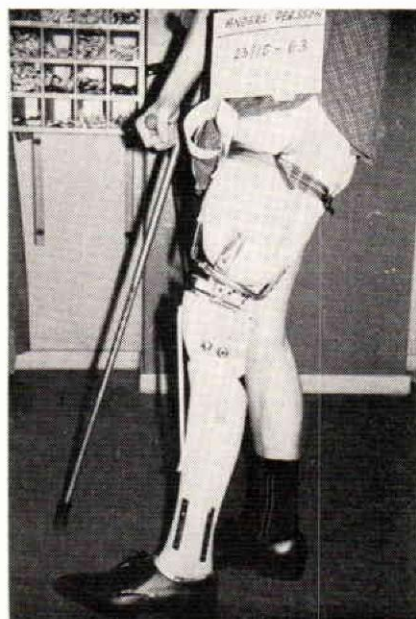

Fig. 5—Oct. 23, 1963

MALE B/K PATIENT

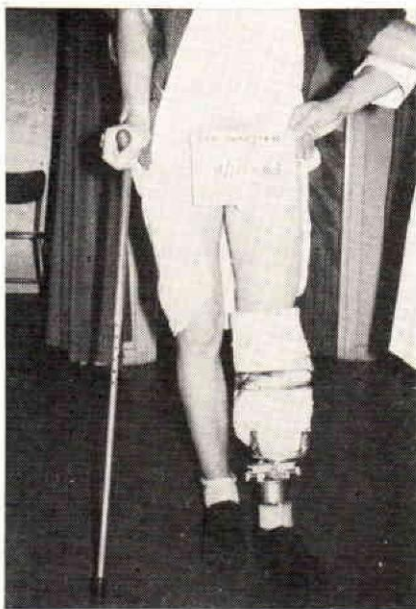

Fig. 6—Oct. 9, 1963
(Two days after amputation)

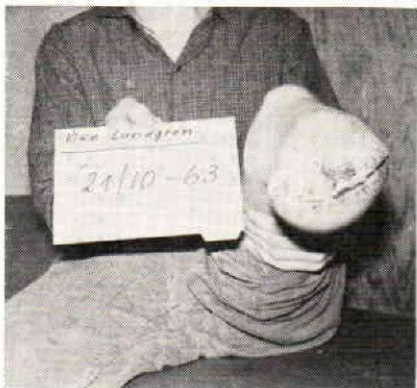


Fig. 7—Oct. 21, 1963

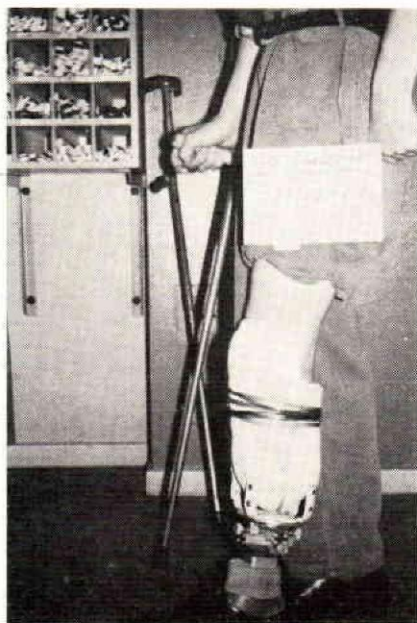

Fig. 8—Oct. 23, 1963

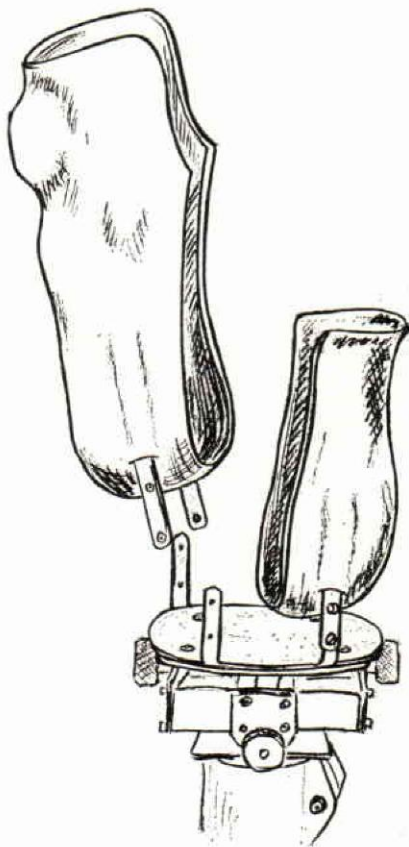


Fig. 9—Split Socket

For reasons easily understandable, it is impossible with this system to make a socket which is open at the end since the proximal pull to which the soft parts of the stump are exposed during the ambulation phase would make rapid healing of the wound difficult if not impossible. It is therefore necessary to construct a socket which is closed at the end and has a relatively soft springy insert. To call this an end-bearing socket would be erroneous. One must construct a contact socket where the load is distributed as evenly as possible over the whole surface of the stump. This type of socket is conducive to a better vascular circulation through the alternating compression of the stump during ambulation, and this probably has a positive influence on the healing process. It has been proved, for example, that the healing takes place at the same rate as an amputation without immediate prosthetic ambulation attempts.

Studies based partially on the comments of the patients and partially on our own observations indicate that the pain which unavoidably follows an amputation is not intensified by the ambulation exercise immediately after surgery.

In conclusion I would like to underline the following observations. Based on the material which has been discussed, it can be stated that no complications have been observed by this type of treatment. The only disadvantage noted is the fact that through the repeated changing of casts, additional labor is required, which should be charged to the general cost. It should be possible to compensate for these disadvantages as, in many cases, they are counterbalanced by the advantages of this method. These advantages are not only of an economic, but, primarily, of a psychologic nature. The depressing and expensive waiting time for a prosthesis is eliminated. The cost of hospitalization is reduced and the patient can return to gainful employment in a shorter time.

Although the financial point of view is important, we consider the greatest advantage to be of a physical and psychological nature. These in turn affect the economic questions favorably, due to the fact that the patient is not immobilized between the day of amputation and delivery of the permanent prosthesis. The body functions are not adversely affected, the general condition is improved, in contrast to patients treated in the conventional manner; that is, sitting or lying at home, gaining considerable weight, and losing muscular efficiency. Ambulation exercises are made easier because the patient has no time to forget how to walk; proprioceptive sense is not eliminated, since the patient has not become adjusted to a one-legged condition.

First and last, it may be seen that the newly amputated patient realizes from the day after surgery, that something is being done for him—the feeling of being an invalid cannot take hold of his subconscious mind in the same way as if he were left for a month or longer with the uncertainty of what his future prosthesis will look like and how it will function.

The preceding material is relatively limited. The results, however, encourage further efforts.