

# Transparent Preparatory Prostheses for Upper Limb Amputations

by Terry J. Supan, C.P.O.

The use of preparatory prostheses for lower extremity amputations has been widely published and publicized throughout the United States. Although techniques may differ from thermoplastic, laminated, or synthetic casting material for the socket, the concept of early fitting with a prosthesis to reduce the volume of the residual limb are fairly well adhered to. However, little has been publicized about preparatory fitting for arm amputations.

Since 1982, the Southern Illinois University School of Medicine has extensively used preparatory prostheses within the 30 day post-amputation time period. Techniques have changed gradually over the last four years, but a fairly constant, successful technique has evolved at the present time. Although myoelectric prostheses with their ease of therapy training have been the componentry of choice, the prosthesis design can also use conventional componentry.

The technique has also allowed us to utilize different componentry on an experimental basis to best determine the optimum componentry for the individual amputee. Prostheses have been

used on all levels of amputation from wrist disarticulation through forequarter amputation (Figures 1-6). Since 1984, all prosthetic interfaces have been fabricated out of transparent material. Materials have either been Surlyn® or Durr-Plex. The transparent materials were chosen to improve monitoring of the residual limb during volume change. Surlyn® is used for below and above fitting sockets, while Durr-Plex is used for shoulder disarticulation and forequarter frames. With each of these systems, the prosthesis can be altered through heat forming as the patient's volume changes.

Standard electric prosthetic componentry has been used in all cases. However, minor modifications to the prosthesis/componentry interface have been necessary. Componentry which utilizes separate stainless steel electrodes from the amplifiers (Motion Control, VANU, and UNB) have been modified to use the stainless steel electrode developed for the Motion Control systems. Prostheses which utilize one piece electrode amplifiers (Otto Bock, Liberty Mutual) are primarily held in place utilizing Velcro® compression straps (Figures 7 and 8).

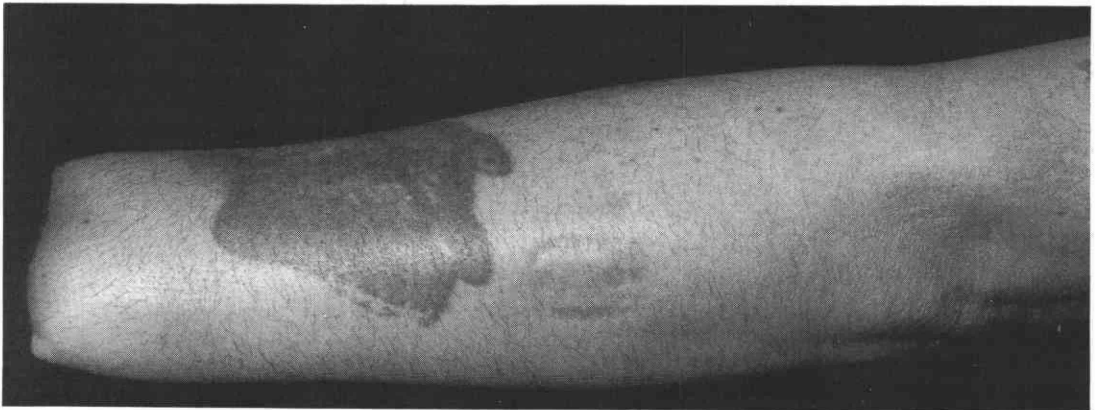

Figure 1. Left wrist disarticulation amputation secondary to trauma.

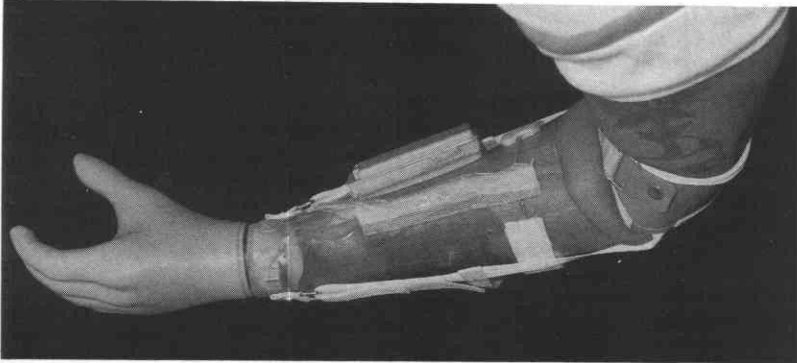


Figure 2. Left wrist disarticulation myoelectric prosthesis with supracondylar cuff to maximize supination and pronation.

Figure 3. Right mid-shaft below-elbow amputation, secondary to trauma and reattachment failure.

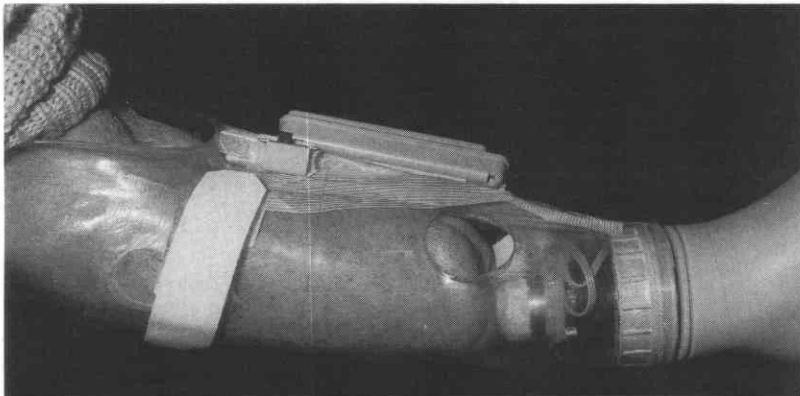
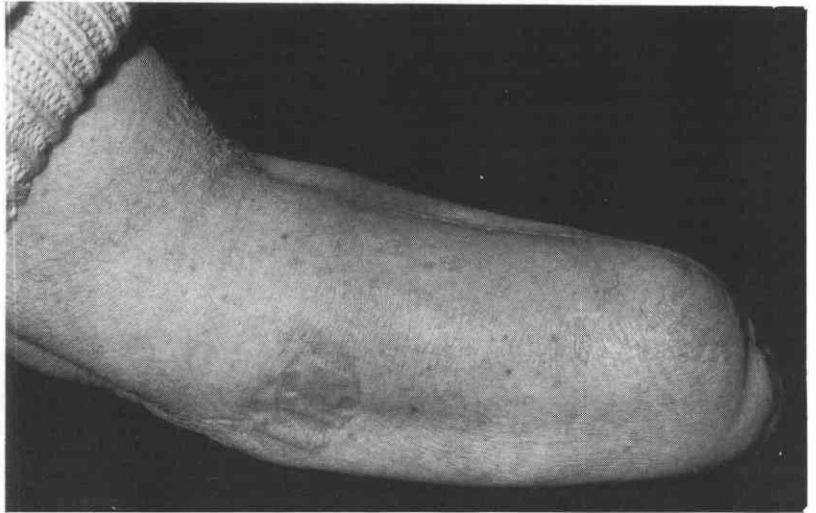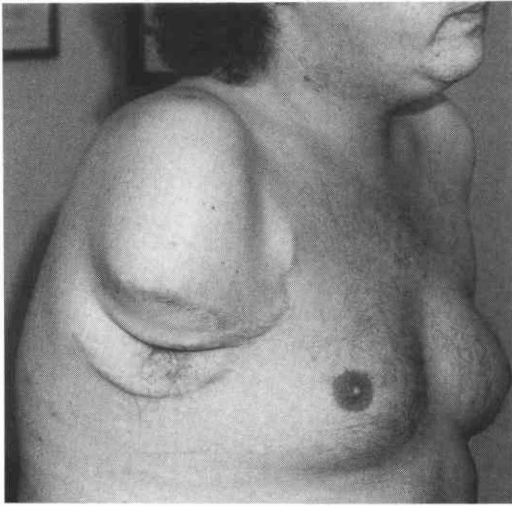


Figure 4. Right below-elbow prosthesis with supracondylar suspension and electric wrist rotator. Note that electronic controls, Otto Bock #, are mounted parallel to the electric rotator.

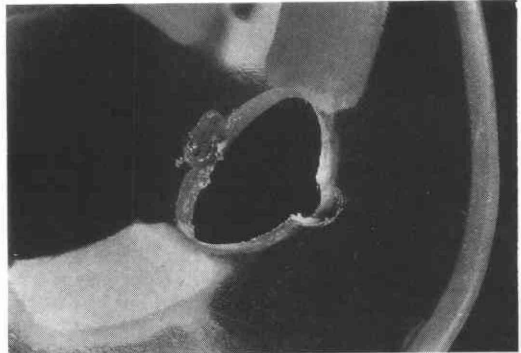
All loose wires are held in place with either strapping tape or duct tape. Manufacturers' recommendations concerning shielding of wires and electrodes are also followed.

An amputee's decrease in limb volume is monitored monthly until the volume has stabilized. If revisions of scar tissue, skin grafts,

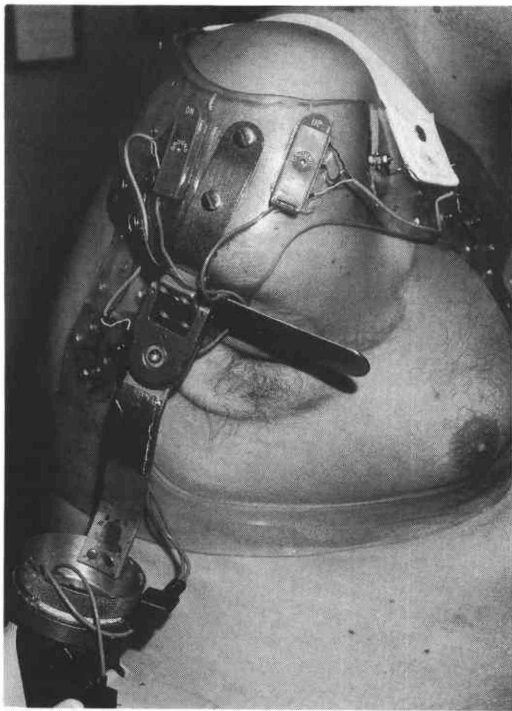
etc., are necessary, it is recommended that they be done during this time period as well. Modifications to the prosthesis must be made to maintain good electrode contact as well as suspension. Sockets may be split and Velcro® compression straps added if necessary. Electrodes may be replaced or locations adjusted if




**Figure 5.** Right humeral neck above-elbow amputation secondary to trauma.



**Figure 7.** Close-up view of electrode site in Surlyn® wrist disarticulation prosthesis. The area of the Otto Bock electrode extension tabs have been modified in the socket with a Dremmel tool to prevent rotation of electrode on skin.



**Figure 6.** Shoulder disarticulation frame type prosthesis fitted to short above-elbow amputation.



**Figure 8.** Otto Bock electrode mounted into preparatory prosthesis. Velcro® maintains the electrode from passing completely through the socket.

necessary (Figure 9). Although this is easily done with the Motion Control stainless steel electrodes by simply drilling another hole, it also can be accomplished with the Otto Bock or Liberty Mutual electrodes. If a hole saw is used to drill out the new location for the electrode, the cut-out material can be utilized to repair the previous location in the preparatory prosthesis.

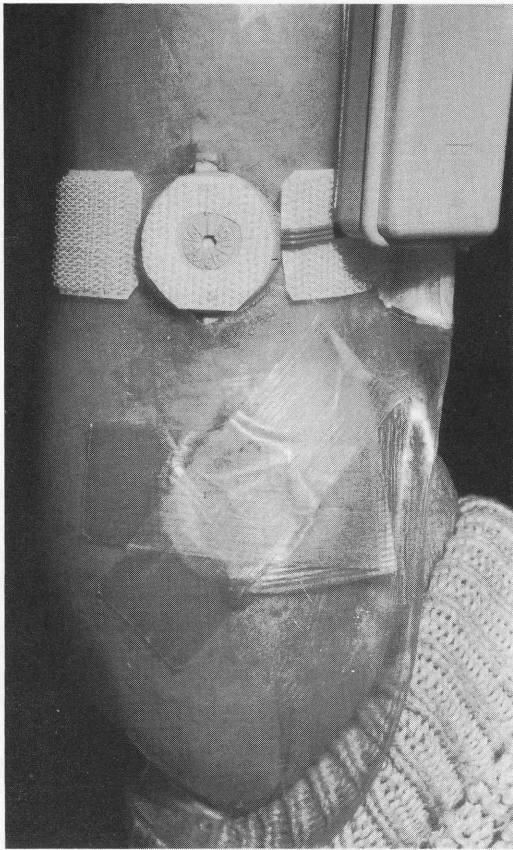


Figure 9. Close up view of preparatory below-elbow prosthesis. Hook Velcro® adhesive backing is used to suspend the electrode in the prosthesis. Previous incorrect electrode site is repaired with cut-out from new electrode site. Battery pack is held in place with adhesive backed Velcro® as well.

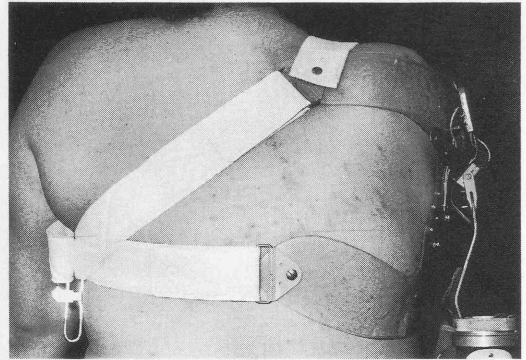


Figure 10. Posterior view of preparatory shoulder disarticulation prosthesis. Elastic strap superior to the shoulder improves comfort. Split of posterior frame into sections allows sitting comfort without electrode displacement.

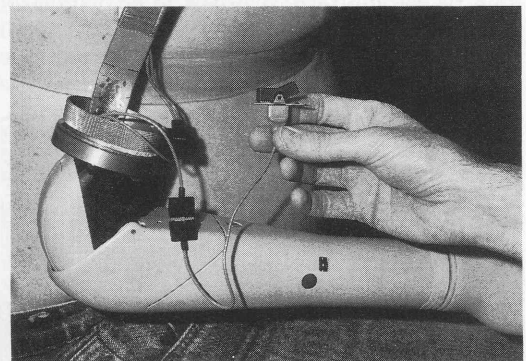


Figure 11. Lateral view of shoulder disarticulation prosthesis. Auxiliary switch is used to alternate EMG control between electric wrist rotation, hand opening, and closing.

Since 1982, 25 upper extremity amputees have been fit with this system. It has allowed us to closely monitor the development of the maturation process of the residual limb. Adjustments to the prosthesis have been made with minimal fabrication time. Total replacement of the preparatory prosthesis was only necessary in two cases. All other cases could be accommodated by modifying existing prostheses. All but one patient (forequarter amputation) went on to fitting and delivery of their permanent prosthesis. The results of these patients' permanent prostheses are consistent with the findings of Malone, et al.<sup>1</sup>

#### AUTHOR

The author is a member of the clinical faculty at Southern Illinois University School of Medicine. Correspondence should be addressed to Southern Illinois University, Orthotic and Prosthetic Services, Room 102, 707 North Rutledge Street, Springfield, IL 62702.

#### REFERENCES

- 1 Malone, J.M., M.D., et al., "Immediate, Early, and Late Postsurgical Management of Upper-Limb Amputation," *Veterans Administration Journal of Rehabilitation*, Volume 21, No. 1, May, 1984, pp. 33-42.