

Use of a Bivalved Thoracic Suspension Jacket in the Orthotic Seating Management of Severe Arthrogryposis Multiplex Congenita

by Carrie L. Beets, C.O.
Louis Whitfield, R.T. (O)
Jan Minnich, L.P.T.
J. Leonard Goldner, M.D.

INTRODUCTION

The thoracic suspension orthosis^{1,2,3} was developed to aid in the management of patients with neuromuscular disease and has been used primarily in individuals with myelodysplasia. The principle of the device is to use the rib cage as a weight bearing structure and thus provide improved seating posture for the patient while attempting to limit spinal deformity and relieve excess ischial pressure. Additional benefits include improvement of balance and mobility, freeing of the hands and arms for feeding and other activities of daily living. The body image of the patient is improved while seated in a wheelchair and the patient may interact better with the environment.

The thoracic suspension orthosis should be considered for those patients who cannot tolerate surgery, or when surgery should be delayed until they reach maturity.

The patient presented in this paper does not fit the usual criteria for use of a thoracic suspension orthosis. The needs of this patient went beyond those provided by usual orthotic seating devices and led to the adaptation of established techniques and development of a different design to provide a functional seating arrangement for a severely involved child who had failed with other custom seating devices.

This seven year old girl with severe generalized arthrogryposis multiplex congenita had functional limitation in the upper extremities and no voluntary action in the lower extremities. Surgical releases of soft tissue contractures and proximal and distal femoral osteotomies had been performed to adapt the patient to a sitting position. Past attempts to provide molded seating inserts to allow a comfortable sitting position had failed. She was most functional supine in a custom designed portable bed-like seating insert which permitted feeding.

Examination of the child revealed severe muscle atrophy of both upper extremities. There was active elbow extension but no active flexion. She was able to get her left hand to within several inches of her mouth by abducting and forward flexing her shoulder and then allowing gravity to bring her hand to the mouth.

The spine revealed right thoraco-lumbar scoliosis, thoracic kyphosis, fixed lumbar lordosis, and a fixed pelvic obliquity in which the left pelvic brim was higher than the right.

The left hip had a range of motion from 30 degrees flexion to about 90 degrees for a total of 60 degrees of flexion, with an external rotation deformity. The right hip was fixed in +20 degrees flexion. Both knees had flexion contractures of 70 degrees with 10 degrees motion.

In order to flex the right femur for sitting, a subtrochanteric osteotomy had been performed with creation of a silicone capped pseudoarthrosis. While this was relatively successful, pain occurred when the patient was placed in a sitting position with any weight bearing occurring on the right ischium. For this reason, she was evaluated for use of a thoracic suspension orthosis.

The patient was initially placed in a plaster cast thoracic suspension jacket for a three week trial. During this time, the periods of suspension were gradually increased. Her skin was not accessible for monitoring; however, since she had normal sensation and was cooperative, we depended on her complaints of pain to assess the support. She tolerated the three week trial period and experienced no skin breakdown or abrasion. At that time, a cast impression was taken for the fabrication and fitting of a thoracic suspension orthosis.

FABRICATION AND FITTING

Due to the lack of spinal flexibility, the need for easy and accurate application of the orthosis, as well as the need to make the device as simple as possible for the parents, a bivalved design was chosen rather than the traditional single anterior opening. The bivalved design (Figure 1) necessitated fabrication of two plastazote™ linings complete with conventional additional plastazote™ layers over the inferior costal margins. Special attention was needed to insure that the anterior and posterior halves of the two linings matched up accurately during the vacuum forming process (Figure 2).

The suspension spools were incorporated into the posterior shell, which was fabricated of low density polyethylene. High density polyethylene was chosen for the anterior shell, as it was felt that the additional rigidity provided by this material would be needed to maintain the integrity of the circumferential containment of the jacket under weight bearing. A large abdominal opening was provided in the anterior shell because the patient had experienced some distress in the plaster jacket, especially following meals, which had been relieved by the addition of an opening in the plaster cast

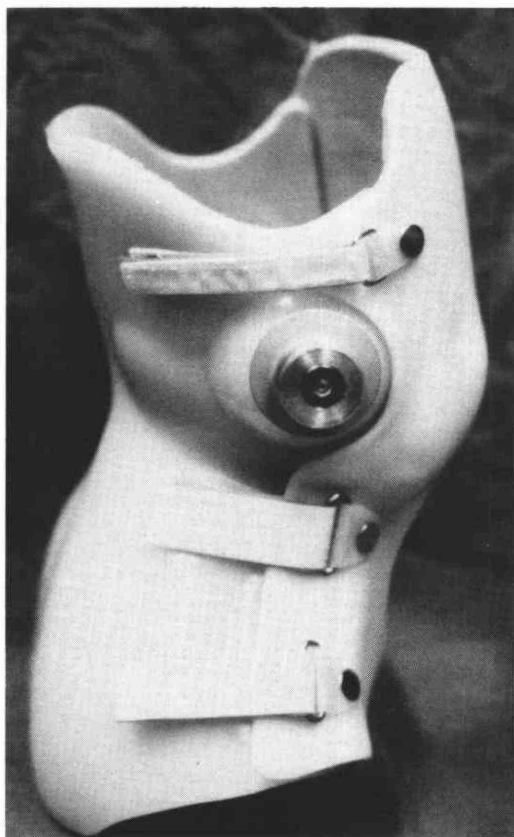


Figure 1. Lateral view of bivalved thoracic suspension orthosis showing anterior shell trimlines.




Figure 2. View from above, the anterior and posterior linings match up to provide an even pressure just distal to the lateral and anterolateral inferior costal margins.

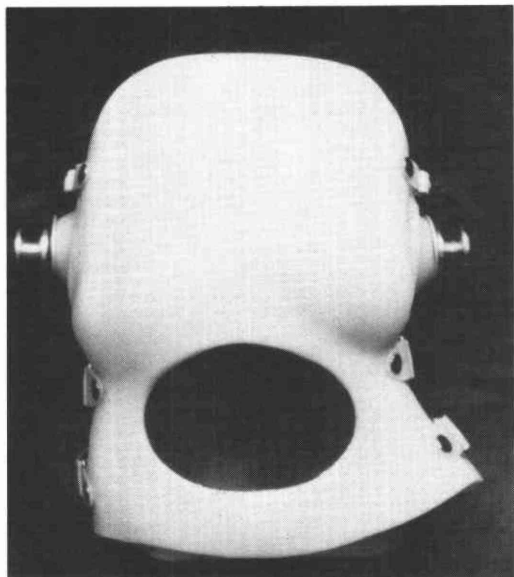

Figure 3. Anterior view of bivalved thoracic orthosis showing abdominal opening.

(Figure 3). The two half shells were held in place as a unit with Velcro® closures.

Fitting of the orthosis was followed by an in-hospital program of gradually increasing wearing time both in the nonsuspended and suspended states. Her original supine positioning device was modified to permit her to lie in this with the thoracic suspension jacket on, eliminating the need to take off the jacket between periods of suspension. Since she could not tolerate any weight bearing on her right hip, the suspension brackets on the wheelchair were positioned for full weight bearing suspension. She tolerated the conditioning program well, and at the time of discharge was wearing the jacket all day long and was tolerating uninterrupted suspension for periods of two and one-half hours. Her electric wheelchair was outfitted with a chin operated joy stick control (Figure 4). While suspended, she could operate the wheelchair well, but at the end of two and one-half hours in suspension, the patient would begin to complain of discomfort and, at that time, would be transferred to her supine positioning device.

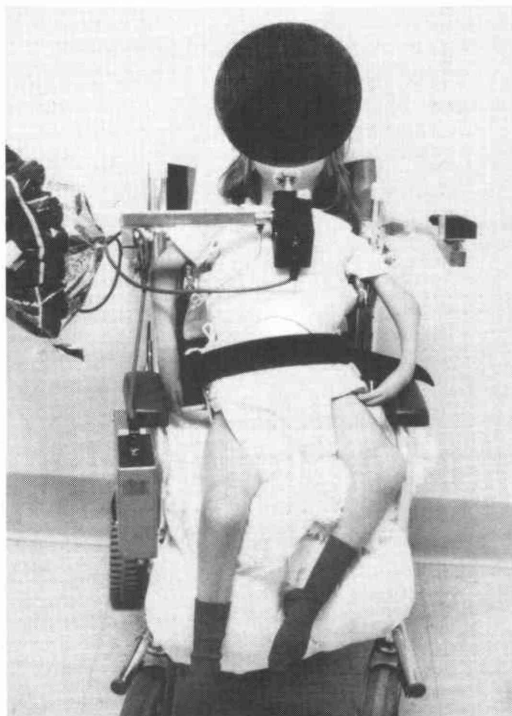


Figure 4. Patient sitting in suspension in wheelchair.

CONCLUSION

The application of a thoracic suspension jacket is a way of successfully providing a functional sitting position for a patient with severe arthrogryposis. In conjunction with a modified electric wheelchair, the patient was given an opportunity to interact actively with her environment, including a vertical position for eating.

The bivalved design not only affords easy application and removal, but also permits visual monitoring of the skin. The crucial circumferential containment in the area of and just distal to the inferior costal margin was maintained satisfactorily with a bivalved design.

REFERENCES

¹ Drennan, J.C.; Renshaw, T.S.; and Curtis, B.H., "The Thoracic Suspension Orthosis," *Clinical Orthopaedics and Related Research*, No. 139, March/April, 1979, pp. 33-39.

² Drennan, J.C., *Orthopedic Management of Neuromuscular Disorders*, J.B. Lippincott Co., Philadelphia, p.83.

³ Fillauer, C.E.; and Pritham, C.H., "The Thoracic Suspension Jacket—Review of Principles and Fabrication," *Orthotics and Prosthetics*, Vol. 38, No. 1, Spring, 1984, pp. 36-44.

AUTHORS

Carrie L. Beets, C.O., is with the University of Virginia. She was formerly with the Duke University Medical Center at the time of submission of this article.

Louis Whitfield, R.T.(O), is with the Department of Prosthetics and Orthotics at Duke University Medical Center.

Jan Minnich, L.P.T., is with Lenox Baker Children's Hospital, Durham, North Carolina.

J. Leonard Goldner, M.D., was former Chief of Orthopedics, Division of Orthopedic Surgery, Duke University Medical Center.