

REFERENCES

¹ Cotrel, Y., "Le corset de platic E.D.F. dass le treatment de la scoliose idiopathegirel," *Med. Hyg.*, 28:1032, 1970.

² Harrington, P.R., "Correction and internal fixation by spine instrumentation," *J. Bone Joint Surg.*, 42A:1448, 1960.

³ Luque, E.R., "The anatomic basis and development of segmental spinal instrumentation," *Spine*, 7:256-259, 1982.

⁴ Ponseti, E.V. and Friedman, B., "Changes in the sciotic spine after fusion," *J. Bone Joint Surg.*, 32A:751-766, 1950.

⁵ Risser, J.C., "The application of body casts for the correction scoliosis," *Am. Acad. Orthop. Surg.*, Instructional Course Lect., 12:255-259, 1955.

⁶ Risser, J.C.; Lauder, C.H.; Norquist, D.M.; and Craig, W.A., "Three types of body casts," *Am. Acad. Orthop. Surg.*, Instructional Course Lect., 10:131-142, 1953.

⁷ Wenger, D.R.; Euroollo, J.J.; Wilkerson, J.A.; Wau-
ters, K.; and Herring, J.A., "Laboratory testing of seg-
mental spine instrumentation versus traditional Harrington
instrumentation for scoliosis treatment," *Spine*, 7:265-
269, 1982.

AUTHORS

Robert D. Fitch, M.D., is Assistant Professor at the Division of Orthopaedic Surgery, Duke University Medical Center.

Carrie L. Beets, C.O., is formerly of the Department of Prosthetics & Orthotics, Duke University Medical Center. She is presently with the University of Virginia, Department of Prosthetics and Orthotics, 1224 W. Main Street, Charlottesville, Virginia 22908.

Technical Article

Dual Function Orthotic Ankle Joint

by **Gustav Rubin, M.D., FACS**
Malcolm Dixon, M.A., R.P.T.
Eugenio Lamberty, C.O.

This is a brief report of a simple mechanism which permits locking and unlocking of an orthotic ankle joint. It allows an individual who requires a locked ankle for ambulation to unlock the ankle, permitting plantar flexion of the foot for pedal control while driving a car.

We have found this to be a useful device for patients who have painful arthritic ankles which interfere with ambulation, but who find the discomfort tolerable when they are seated and the limb is unweighted. In such instances, an immobile ankle interferes with the smooth operation of the pedal while contributing little to the relief of pain when sitting.

The following cases illustrate the manner in which this problem was solved with two different types of AFO.

L.S. was 57 years of age when first seen by the VAPC Clinic Team in 1978. He had sustained a fracture of the right femur in WWII, which had healed in 20° of internal rotation of

the distal fragment and with subsequent post-traumatic arthritis of the knee. A concomitant sciatic nerve injury indicated the need for a drop foot orthosis and the patient was provided with a light-weight shoe clasp orthosis.^{1,2} Because of the internal rotation deformity, the patient was pushing off from the lateral aspect of the foot, and he developed callosities beneath the fifth metatarsal base. Subtalar, ankle, and mid-tarsal motion were painful. The shoe clasp orthosis did not adequately control the flexible equinovarus of the foot; a double bar orthosis with varus correction T-strap and spring loaded ankle was prescribed. The spring loading was permitted because the patient indicated that a solid ankle would interfere with the operation of the gas pedal of his car. The spring loaded ankle did not sufficiently relieve the pain and on October 10, 1984, the VAPC Clinic Team prescribed an AFO with an ankle joint which could be locked for ambulation and unlocked

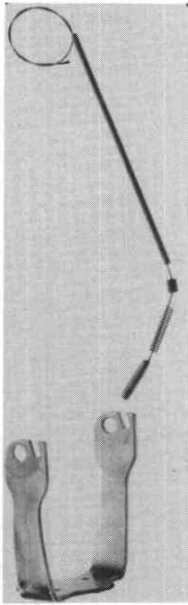


Figure 1. The stirrup has been slotted to receive the pin, the threaded screw drilled to permit passage of the cable and the pin welded to the cable. Note also the spring and the cable housing.

for driving. This functioned well and accomplished the purpose for which it was designed. The shoe incorporated a rocker bar and long steel spring.

FABRICATION

1. A $\frac{1}{4}$ " wide by $\frac{3}{8}$ " deep slot was prepared in each stirrup upright with a $\frac{1}{4}$ " drill. The tubular area in the distal upright (for the adjustment screw and Klenzak spring) was used to guide the drill (Figure 1).
2. A drill hole was made vertically through the center of the adjustment screw with a size 40 drill and a conventional upper extremity control cable was passed through this hole (Figures 1 and 2).
3. One end of the cable was welded to a $\frac{1}{4}$ " wide steel pin, 1" long (Figures 1 and 2).
4. The above components were assembled as shown in Figure 2. Each cable was passed through a conventional upper extremity cable housing, which was then strapped

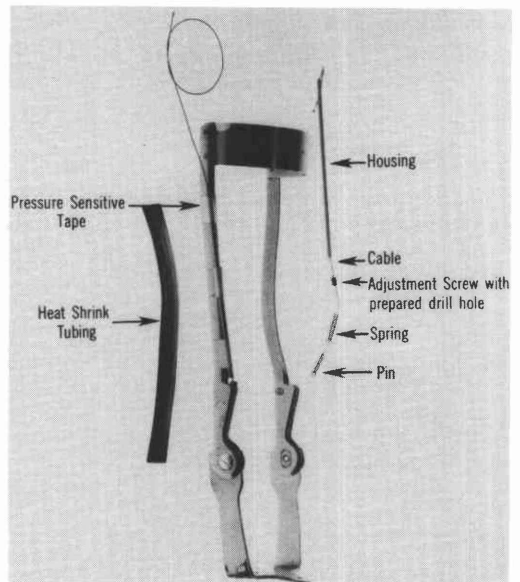


Figure 2. The basic components of the dual function ankle.

to each upright of the AFO, using pressure sensitive tape (Figure 2). Finally, the housing was covered with heat shrink tubing (Figures 1, 2 and 3).

5. A plastic "handle" was fabricated for attachment to the proximal ends of the cable and adjusted to lock, under spring tension, to a pin fixed to the middle of the calf band (Figures 3 and 4). When hooked over the retention pin, the locking rod was released from the stirrup slot allowing ankle motion. When the handle was disengaged, the spring became effective, locking the ankle.

A similar approach was also used for a PTB orthosis (Figures 5 and 6). The basic fabrication technique was the same, although the pathological problem required a PTB Orthosis rather than an AFO.

A.T. was initially seen by the VAPC Clinic Team in 1973 when he was 49 years of age. As a result of multiple injuries sustained in 1967, several surgical procedures had been carried out: an arthrotomy of the left knee, followed by an osteotomy of the tibia to correct valgus, and, in 1970, a triple arthrodesis of the right foot. Non-union of the right talo-navicular joint and medio-lateral ankle stress pain developed. Special shoes incorporating a support for the long arch on the right were ordered, as well as a right AFO with free motion ankle. A KAFO was prescribed for the left side, with free mo-

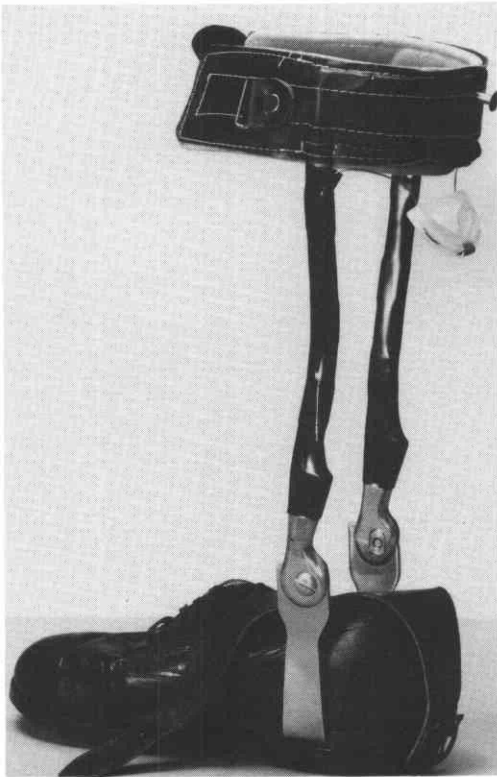

Figure 3. The AFO in the locked mode.

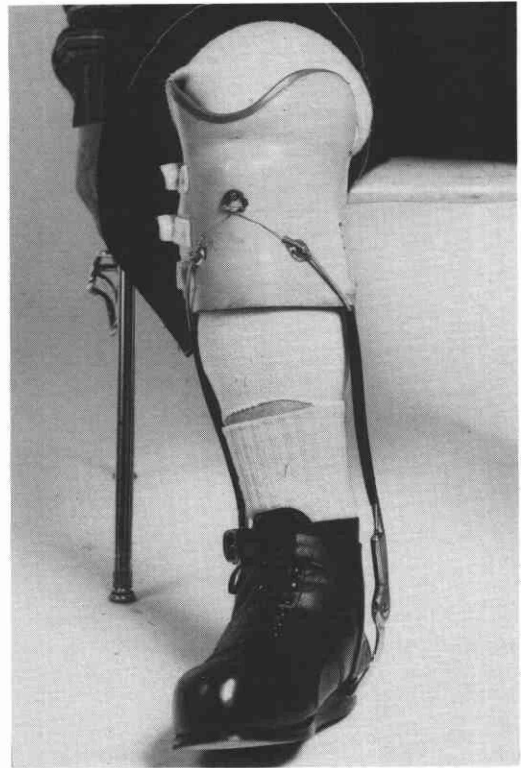


Figure 5. PTB Orthosis with anterior cuff retention button.



Figure 4. The unlocked AFO.



Figure 6. Lateral view of PTB.

tion ankle, because of persistent pain in the left knee with progressively increasing varus deformity and secondary ankle pain due to malalignment.

In January, 1977, a rocker bar was prescribed for the right shoe in an attempt to diminish A.P. ankle stress in view of moderate limitation of anatomical ankle motion.

In July, 1978, the patient returned and reported that his right ankle pain had increased with progression of osteoarthritis and a PTB^{2,3} orthosis was ordered. When this was shown to the patient, he indicated a reluctance to try it because limited ankle motion or the absence of ankle motion would interfere with his driving and he did not wish to consider hand controls.

The Clinic Team decided to prescribe an ankle joint which the patient would be able to unlock for driving and relock for walking. This was to be designed as a tongue-in-groove, manually controlled lock similar to that previously described.

In this instance, since the retention button was on the anterior cuff and readily visualized, a less obtrusive metal device was fabricated to hook over the retention button.

SUMMARY

A modified ankle joint has been described which permits the user to lock the ankle for ambulation and unlock it for specific sedentary functions.

REFERENCES

¹ Rubin, G.; Bonarrigo, D.; Danisi, M.; and Dixon, M., "The shoe as a component of the Orthosis," *Orthotics and Prosthetics*, 30:2, pp. 13-25, June, 1976.

² Rubin, G.; Dixon, M.; and Danisi, M., "VAPC Prescription Procedures for Knee Orthoses and Knee-Ankle-Foot Orthoses," *Orthotics and Prosthetics*, 31:3, pp. 9-25, September, 1977.

³ Rubin, G., "The Patellar-Tendon-Bearing (PTB) Orthosis," *Bulletin of the Hospital for Joint Diseases*, XXXIII:2, pp. 155-173, October, 1972.

AUTHORS

Gustav Rubin, M.D., Malcolm Dixon, M.A., R.P.T., and Eugene Lamberty, C.O. are all members of the Special Clinic Team at Veterans Administration Prosthetic Center (VAPC), 252 Seventh Avenue, New York, NY 10001.