

# A New Approach to Patient Analysis for Orthotic Prescription— Part I: The Lower Extremity

NEWTON C. MCCOLLOUGH III. M.D.  
CHARLES M. FRYER. MA..<sup>2</sup> AND  
JOHN GLANCY, CO.<sup>3</sup>

There is little question that the field of orthotics has taken a back seat to prosthetics in modern times, and perhaps for good reason. The needs of the amputee are more immediate and obvious, and the wars of the past thirty years have yielded untold numbers of young men in their prime whose productivity depended upon satisfactory functional restoration of their missing limbs. Medicine, engineering, and the prosthetic profession have responded to the needs of the amputee through extensive research and development, widespread educational programs, improved fabrication and fitting techniques, and better delivery of services. The field of orthotics remains in comparative disarray with more limited, though no less sophisticated, research activities, few educational endeavors, and little improvement upon local fabrication and delivery services over the past fifty years.

Much of the blame for this rather distressing state of affairs must be laid to the physician, whose approach to orthotic prescription has been somewhat less than scientific. More often than not, little thought is given to analyzing specific bio-

mechanical defects present in an extremity with the aim of translating them into an appropriate mechanical substitute. Even when this is done, all too often the device that is prescribed impairs to some degree the normal biomechanical functions which coexist in the same extremity. For example, a long leg brace prescribed for genu recurvatum may also limit normal functioning of the subtalar joint. Much of the physician's casual approach to orthotic prescription stems from a relatively sparse education in orthotic principles, but an even greater deficiency is the failure to relate well-known biomechanical principles to the mechanical substitute, or orthosis. Therein lies the trap, for without this awareness, prescriptions will continue to reach the orthotist calling for simply a "short leg brace" or a "long leg brace," and thus there is no stimulation for new or improved design criteria for orthotic components and systems.

There is little doubt that the great advances which have been made in prosthetics in recent years have resulted primarily from a systematic appraisal of normal human posture and locomotion, with resultant attempts to duplicate not only the missing anatomy but also the biomechanical functions of the extremity. The problem in orthotics is somewhat different: specific functional losses must be substituted for in the presence of intact anatomy, and the variety of functional losses which may be present in a given extremity necessitates correspondingly var-

<sup>1</sup> Assistant Professor of Orthopaedics, Associate Director of Rehabilitation, University of Miami School of Medicine, Miami, Fla. 33152.

<sup>2</sup> Director, Prosthetic-Orthotic Center, Northwestern University Medical Center, Chicago, Ill. 60611.

<sup>3</sup> Orthotic Division, Indiana University Medical Center, Indianapolis, Ind. 46207.

ied design criteria. It is apparent, therefore, that an initial step in developing a rational approach to orthotic design and prescription would be some means of systematically analyzing the biomechanical losses in an impaired extremity. Once properly identified, these losses could then be matched against specific components or component systems to substitute for the functions lost. In addition, such an analysis might point up certain areas or functions for which truly satisfactory components are not available, and thus it might serve as a stimulus for future design and development.

Recognizing the need for a more organized and systematic approach to orthotic prescription as a part of current efforts to revise volume 1 of the *Orthopaedic Appliances Atlas*, the Committee on Orthotics and Prosthetics of the American Academy of Orthopaedic Surgeons appointed an ad hoc committee for the development of a lower-extremity analysis form. In essence, this article represents a report of that committee, whose work commenced two years ago. During the development of the form, workshops were held periodically with the parent committee, together with representatives of the American Orthotic and Prosthetic Association, the Veterans Administration Prosthetics Center, and the Committee on Prosthetics Research and Development of the National Research Council. The form underwent periodic revision as it was applied to patients with a variety of disabilities, utilizing several clinics. The most recent and final application of the lower-extremity analysis form was in conjunction with the Workshop Panel on Lower-Extremity Orthotics held at Rancho Los Amigos Hospital in Downey, California, in March 1970. Its applicability to the evaluation of lower-extremity disability is now felt to be such as to warrant description for more widespread usage.

#### LOWER-EXTREMITY ANALYSIS FORM

The form consists of four pages of appropriate size for insertion into the

patient's hospital chart. The first page (Fig. 1) contains spaces for patient data, including the diagnosis and a summary of major impairments existing in one or both extremities. At the bottom of the first page there is a legend for symbols to be used on the extremity diagrams. The second and third pages (Figs. 2 and 3) contain skeletal outlines of the right and left lower extremities, respectively, in the sagittal, coronal, and transverse planes. Overlying the major joints are shaded areas, representing the normal ranges of joint motion within a circle divided into thirty-degree segments. Similar smaller circles overlie the mid-shafts of the long bones for diagraming angular, rotational, or translational deformities of the femur and tibia. The fourth page (Fig. 4) includes spaces for summarizing the functional disability, and for orthotic recommendations based upon this summary.

#### INSTRUCTIONS FOR USE

Most of the "Major Impairments" portion of the form is self-explanatory. "Abnormal bone and joint" conditions may include such entities as osteoporosis, Paget's disease, and coxa vara. "Muscle" may be normal, flaccid, or spastic, but a space is provided for description of rarer disorders such as muscular dystrophy and fibrosis of muscle. Under the heading of "ligament," check boxes are provided to indicate abnormal laxity of the major ligaments of the knee and ankle. The sections on "sensation," "skin," and "vascular" impairments cover considerations which may influence orthotic design, and are self-explanatory.

"Balance" is either normal or impaired, and if impaired, the following definitions are applicable: "mild" impairment is compatible with independent ambulation; "moderate" impairment is compatible with ambulation utilizing external support; and "severe" impairment indicates the need for maximal support or personal assistance in ambulation.

"Extremity shortening" is recorded as follows: ischial tuberosity to sole of heel,

DIAGNOSIS \_\_\_\_\_ NAME \_\_\_\_\_  
 \_\_\_\_\_ NO \_\_\_\_\_ SEX \_\_\_\_\_  
 \_\_\_\_\_ AGE \_\_\_\_\_ HEIGHT \_\_\_\_\_ WEIGHT \_\_\_\_\_  
 DATE \_\_\_\_\_

**MAJOR IMPAIRMENTS:**

**A. Musculoskeletal:**  
 1. Bone & Joint: Normal  Abnormal \_\_\_\_\_  
 2. Muscle: Normal  Flaccid  Spastic   
 Other \_\_\_\_\_  
 3. Ligament: Normal  Abnormal : Knee: AC  PC  MC  LC   
 Ankle: MC  LC   
 Other \_\_\_\_\_

**B. Sensation:** Normal  Abnormal   
 1. Anaesthesia  Location \_\_\_\_\_  
 Protective Sensation: Lost  Retained   
 2. Proprioceptive Loss   
 Location \_\_\_\_\_ Degree: Mild  Moderate  Severe   
 3. Pain  Location \_\_\_\_\_

**C. Skin:** Normal  Abnormal \_\_\_\_\_

**D. Vascular:** Normal  Abnormal  RT  LT   
 1. Arterial  2. Venous  3. Coagulation Defect

**E. Balance:** Normal  Impaired: Mild  Moderate  Severe

**F. Extremity Shortening:** None  LT  RT   
 Amount of Discrepancy:  
 I.T. - Heel \_\_\_\_\_  
 I.T. - M.T.P. \_\_\_\_\_  
 M.T.P. - Heel \_\_\_\_\_  
 X-ray \_\_\_\_\_

**LEGEND**







 = Direction of Translatory Motion  = Abnormal Degree of Rotary Motion  = Fixed Position  = Fracture	<p><b>Volitional Force</b></p> <p>G = Good                  F = Fair                  P = Poor                  T = Trace                  Z = Zero</p> <p><b>Spastic Muscle (SP)</b></p> <p>SP<sub>M</sub> = Mild                  SP<sub>MO</sub> = Moderate                  SP<sub>S</sub> = Severe</p>	 = Pseudarthrosis  = Absence of Segment <p>E = Edema                  D = Local Distension or Enlargement</p>
---	---	---

Fig. 1. Front sheet of patient analysis form, including summary of major impairments and legend.

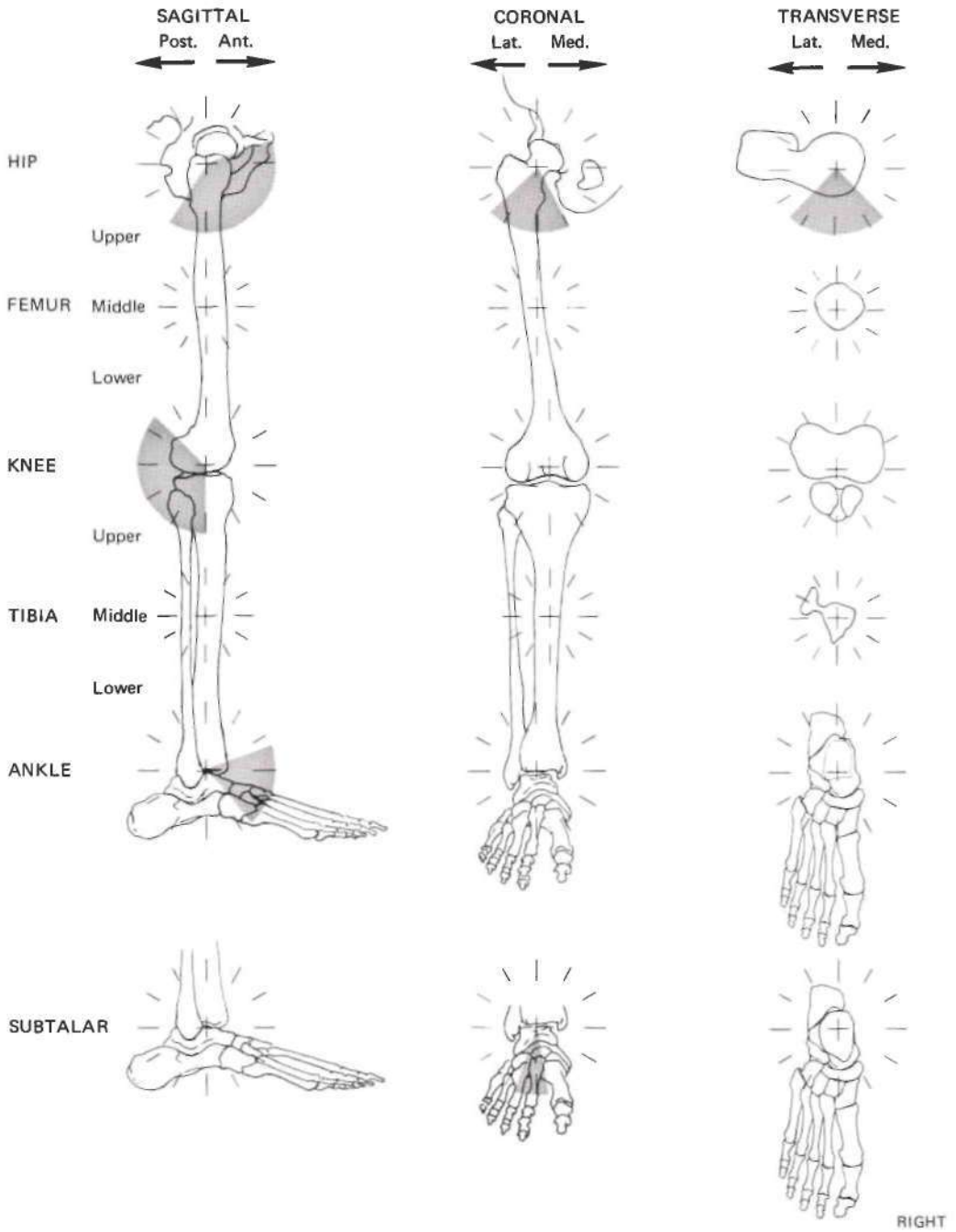
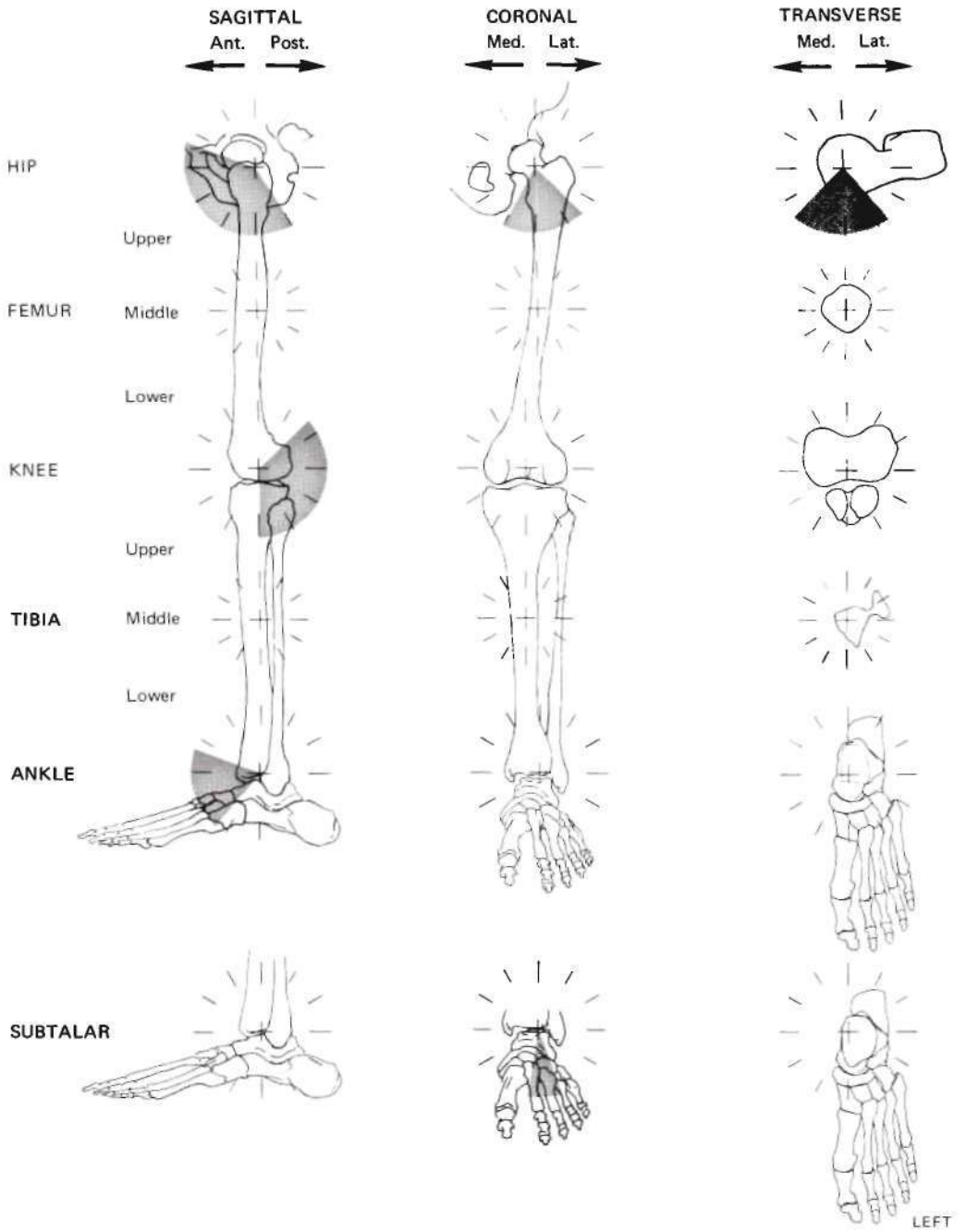


Fig. 2. Second page of patient analysis form, with diagram of right lower extremity.



(OVER)

Fig. 3. Third page of patient analysis form, with diagram of left lower extremity.

Summary of Functional Disability \_\_\_\_\_  
 \_\_\_\_\_  
 \_\_\_\_\_  
 \_\_\_\_\_  
 \_\_\_\_\_  
 Orthotic Recommendation \_\_\_\_\_  
 \_\_\_\_\_  
 \_\_\_\_\_

Fig. 4. Fourth page of patient analysis form provides space for summary of patient's functional disability and for the orthotic recommendation.

ischial tuberosity to medial tibial plateau, and medial tibial plateau to sole of heel.

In leg-length discrepancies exceeding one-half inch, X-ray studies of leg length may be indicated, and an appropriate space is provided for this measurement.

*Legend and Extremity Diagrams*

Two terms must first be defined:

1. "Translatory motion" is motion in which all points of the distal segment move in the same direction, with the paths of all points being exactly alike in shape and distance traversed (Fig. 5).
2. "Rotary motion" is motion of a distal segment in which one point in the distal segment or in its (imaginary) extension always remains fixed (Fig. 6).

The symbols described in the legend are used in conjunction with the right- and left-extremity diagrams according to the following rules:

1. Recording motion

The degrees of rotary motion or centimeters of translatory motion are to be obtained from passive manipulation, and are to reflect passive (not active) motion at the site being examined. In the lower extremity, joints are to be observed during weight-bearing, and if the degree of joint excursion is greater under conditions of loading than under passive manipulation, this figure is diagramed rather than the smaller figure (e.g., recurvatum of the knee).

a) Translatory motion

Linear arrows horizontally placed below the circle indicate the pres-

ence of (abnormal) translatory motion at one or more of the six designated levels of the lower extremity listed on the left side of the form. The head of the arrow always points in the direction of displacement of the distal segment relative to the proximal segment. Linear arrows vertically placed on the right side of the circle indicate

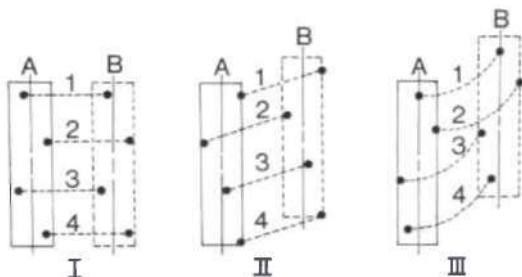


Fig. 5. "Translatory motion": motion in which all points of the distal segment move in the same direction, with the paths of all points being exactly alike in shape and in distance traversed. In all three examples, the pathways between original position "A" and final position "B" of four arbitrarily selected points in each figure are each exactly alike in direction, form, and distance traversed. Note that the long axes of the figures also remain parallel throughout the "translation" from A to B.

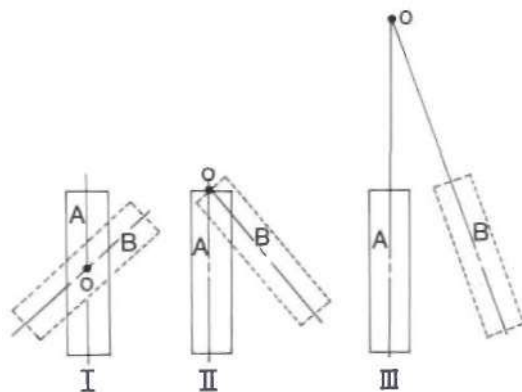


Fig. 6. "Rotary motion": motion of a distal segment in which one point in the segment, or in its (imaginary) extension, always remains fixed. The axis "O," in each of the three examples, represents a point in the figure (or as in "III" in its imaginary extension) that always remains fixed in position when the body "rotates" from position "A" to position "B."

(abnormal) translatory motion along the vertical axis at the site indicated.

b) Rotary motion

Normal ranges of rotary motion about joints are preshaded on the diagram. Abnormal rotary motion, either as limited or excess motion, is indicated by double-headed arrows placed outside and concentric to the circle, to indicate the extent of available motion present in the affected joint. In certain instances, it may be more meaningful to use two double-headed arrows in order to describe the range of motion to either side of the neutral joint axis, rather than a single arrow which describes the total range of motion present. If one head of an arrow fails to reach the preshaded margin, limitation of joint motion is denoted. Conversely, if one head of an arrow projects beyond the preshaded margin, excess motion is designated. Numbers in degrees are placed adjacent to the arrows to indicate the arc described. In addition, radial lines drawn from the center of the circle and passing through its perimeter at the tips of the double-headed arrow are to be used for more graphic representation of the arc of available motion. At sites where rotary motion does not occur (e.g., fracture site, or knee joint in the coronal plane), the presence of abnormal rotary motion is similarly designated by a double-headed arrow with adjacent numerical value in degrees.

c) Fixed position

Double radial arrows indicate a fixed joint position, and describe in degrees the deviation from the neutral joint position. Horizontal or vertical double arrows indicate a fixed joint position in a translatory sense, and the extent of abnormal translation is indicated in centimeters adjacent to the arrow (e.g.,

subluxation of the tibia in a hemophilic knee).

2. Muscle dysfunction

a) Flaccid muscle

Flaccid muscle is designated as such under the section on major impairments. Muscle-group strength, not individual muscle strength, is determined by conventional means on the examining table, and the letter grade corresponding to volitional force is recorded adjacent to the skeletal outline at the proper location for each muscle group. The letter grades correspond to the standard muscle-grading system used in poliomyelitis. No symbol is used if muscle strength is normal.

b) Spastic muscle

Spastic muscle is designated as such under the section on major impairments. It is further identified in the legend as "SP." The letter grade (e.g., SP<sub>MO</sub>) for muscle-group tone, not individual muscles, is to be placed adjacent to the skeletal outline at the proper location for each muscle group. Spastic-muscle estimates are to be made with the patient in the functional position for the lower extremity, i.e., observation during standing and walking. The subletter grades for spastic muscle are as follows:

"M" indicates a mild degree of spasticity;

"MO" indicates a moderate degree of spasticity sufficient for useful holding quality;

"S" indicates severe spasticity, obstructive in terms of function.

In certain instances, muscle groups in a patient with spastic paralysis may be more appropriately graded according to volitional force, e.g., dorsiflexion of the foot in a hemiplegic.

3. Recording fracture or bone deformity

All translatory or rotary motions at the fracture on the shaft of a long bone are diagramed on the circle located

DIAGNOSIS Left Hemiplegia NAME E. L.  
 NO 819644 SEX M  
 AGE 63 HEIGHT 5'11" WEIGHT 162  
 DATE 5/20/69

MAJOR IMPAIRMENTS:

A. Musculoskeletal:  
 1. Bone & Joint: Normal  Abnormal \_\_\_\_\_  
 2. Muscle: Normal  Flaccid  Spastic   
 Other Anterior tibial inverts foot in swing phase  
 3. Ligament: Normal  Abnormal : Knee: AC  PC  MC  LC   
 Ankle: MC  LC   
 Other \_\_\_\_\_

B. Sensation: Normal  Abnormal   
 1. Anaesthesia  Location \_\_\_\_\_  
 Protective Sensation: Lost  Retained   
 2. Proprioceptive Loss   
 Location Foot Degree: Mild  Moderate  Severe   
 3. Pain  Location \_\_\_\_\_


C. Skin: Normal  Abnormal \_\_\_\_\_

D. Vascular: Normal  Abnormal  RT  LT   
 1. Arterial  2. Venous  3. Coagulation Defect

E. Balance: Normal  Impaired: Mild  Moderate  Severe

F. Extremity Shortening: None  LT  RT   
 Amount of Discrepancy:  
 I.T. - Heel \_\_\_\_\_  
 I.T. - M.T.P. \_\_\_\_\_  
 M.T.P. - Heel \_\_\_\_\_  
 X-ray \_\_\_\_\_

LEGEND



Volitional Force

G = Good  
 F = Fair  
 P = Poor  
 T = Trace  
 Z = Zero

Spastic Muscle (SP)

SP<sub>M</sub> = Mild  
 SP<sub>MO</sub> = Moderate  
 SP<sub>S</sub> = Severe

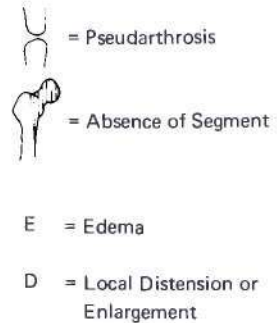
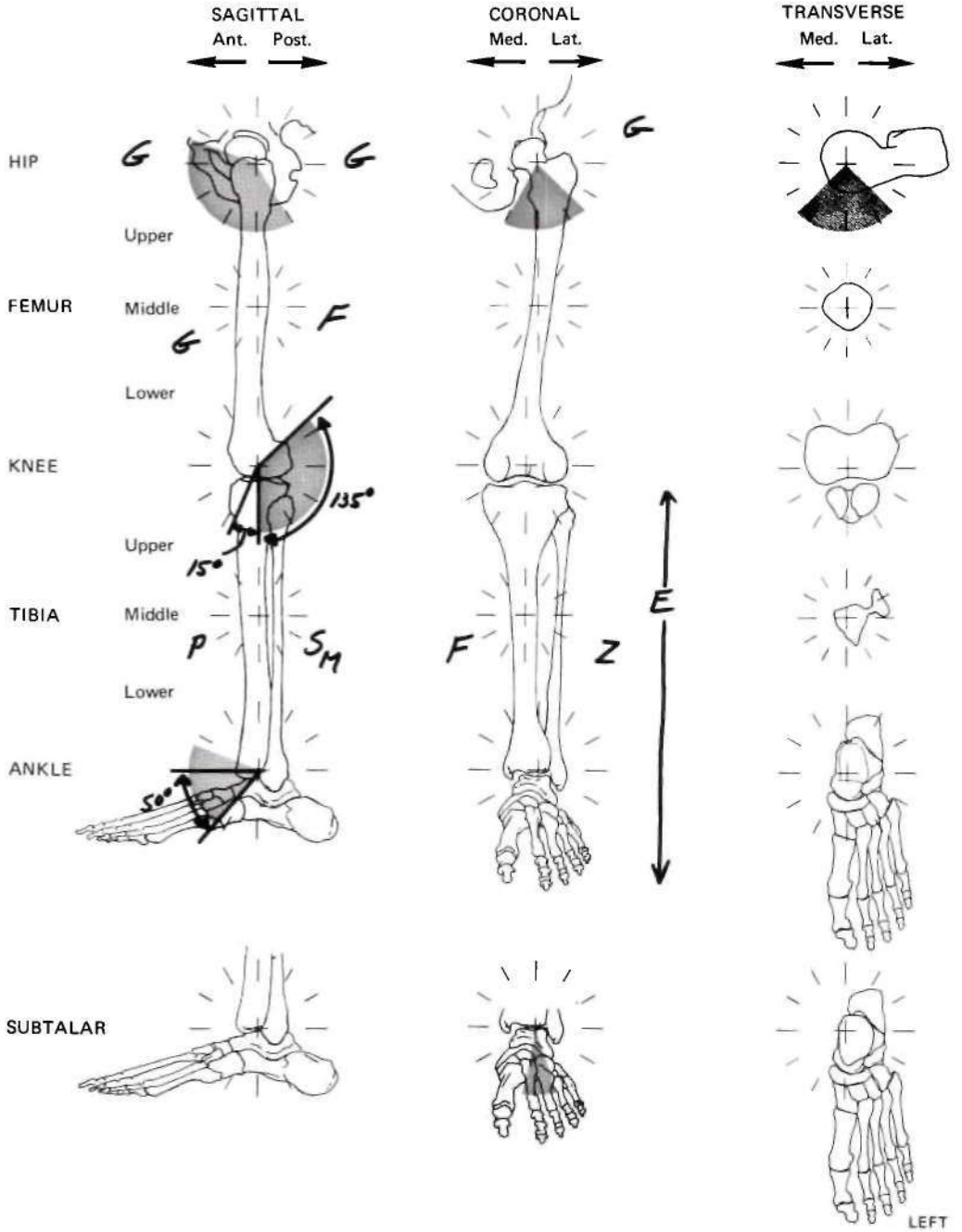


Fig. 7. Record for patient with left hemiplegia. Information given on front sheet includes spastic muscle picture with inversion deformity of foot, mild loss of proprioception, venous stasis in left leg, and mild impairment of balance.





(OVER)

Fig. 8. Diagram of patient E.L.'s left lower extremity. Muscles which are not normal are designated by letter grade. Muscles which are not spastic clinically and which possess volitional control are designated by conventional letter grading. The diagram illustrates presence of good hip flexors, extensors, and abductors, good knee extensors, fair knee flexors and foot invertors, poor foot dorsi flexors, zero foot evertors, and mild calf spasticity. There is 15° of hyperextension at the knee, and the heel cord is tight, limiting dorsiflexion of the foot to neutral. The presence of edema from the knee to the foot is also noted.

Summary of Functional Disability *Dorsiflexion of foot inadequate in swing phase;*  
*inversion of foot in swing phase; tight heel cord with slight spasticity,*  
*probably contributing to recurvatum at knee.*

---

Orthotic Recommendation *Double upright below-knee brace with adjustable*  
*anterior and posterior stop ankle joint, lateral T strap; steel shank*  
*antire length of shoe.*

Fig. 9. Summary of the patient's functional limb disability, and the orthotic recommendation based upon that summary.

at the mid-shaft of each bone. The actual fracture site is indicated by the fracture symbol. All bony deformities such as valgus angulation of the shaft are likewise diagrammed on the circle located at the center of the shaft, regardless of the position of the angular deformity. The location of the angular deformity is designated by circling the appropriate level on the left side of the chart.

The technique of completing the analysis forms for specific lower-extremity disabilities is shown in Figures 7 through 12.

#### DISCUSSION

The stated purpose of developing a patient analysis form of this type is to organize a systematic approach to orthotic prescription. In addition, through stimulation of a careful appraisal of biomechanical faults in a given extremity, it may also serve as a basis for identifying certain areas in need of new or further design and development. It is also viewed as a valuable teaching tool for students of orthotics at both the technician and physician levels. Most importantly, it may serve as a common ground upon which both the orthotist and the physician can meet to work out satisfactory solutions to bracing problems. (Sample copies of the form are available from the CPRD office).

As a further step in making such an analysis form more meaningful to orthotists and physicians, a list of available lower-extremity orthotic components is currently being compiled in such a way as to categorize these components by their biomechanical function. Ideally then, one might diagrammatically plot the biomechanical losses present in a limb and then select a mechanical device from the appropriate category to substitute for the lost function. In this way, the orthotic prescription can evolve as a carefully thought-out combination of specific components to create a suitable orthotic system for the deficient limb.

A revitalized approach to orthotics is urgently needed. According to a recent estimate, there are 3,370,000 orthotic patients in the United States as opposed to 311,000 amputees, or ten times as many patients who need orthoses as need prostheses (1). Little that is new has been done for many of these patients until very recently. Several research centers in the United States and Canada are engaged in sophisticated and promising orthotic research. Unfortunately, by and large, the products of this research have not yet reached the masses of handicapped people. Stimulation of new approaches to mechanical design at the local level must be achieved through close and meaningful collaboration between physician and or-

DIAGNOSIS Poliomyelitis NAME W. S.  
 (L) Lower extremity residual NO. 608213 SEX M  
 AGE 22 HEIGHT 6'0" WEIGHT 195

## MAJOR IMPAIRMENTS:

## A. Musculoskeletal:

1. Bone & Joint: Normal  Abnormal  old triple arthrodesis (L) Foot  
Old, healed supracondylar Fx (L) Femur
2. Muscle: Normal  Flaccid  Spastic   
 Other Severe atrophy thigh & calf, left
3. Ligament: Normal  Abnormal  Knee: AC  PC  MC  LC   
 Ankle: MC  LC
- Other \_\_\_\_\_

B. Sensation: Normal  Abnormal 

1. Anaesthesia  Location \_\_\_\_\_  
 Protective Sensation: Lost  Retained
2. Proprioceptive Loss   
 Location \_\_\_\_\_ Degree: Mild  Moderate  Severe
3. Pain  Location \_\_\_\_\_

C. Skin: Normal  Abnormal D. Vascular: Normal  Abnormal  RT  LT 

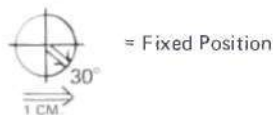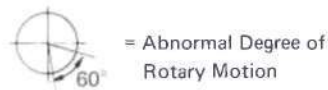
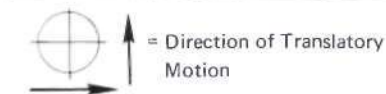1. Arterial  2. Venous  3. Coagulation Defect

E. Balance: Normal  Impaired: Mild  Moderate  Severe F. Extremity Shortening: None  LT  RT 

Amount of Discrepancy:

I.T. - Heel 1 3/4"  
 I.T. - M.T.P. 3/4"  
 M.T.P. - Heel 1"  
 X-ray \_\_\_\_\_

## LEGEND




## Volitional Force

G = Good  
 F = Fair  
 P = Poor  
 T = Trace  
 Z = Zero

## Spastic Muscle (SP)

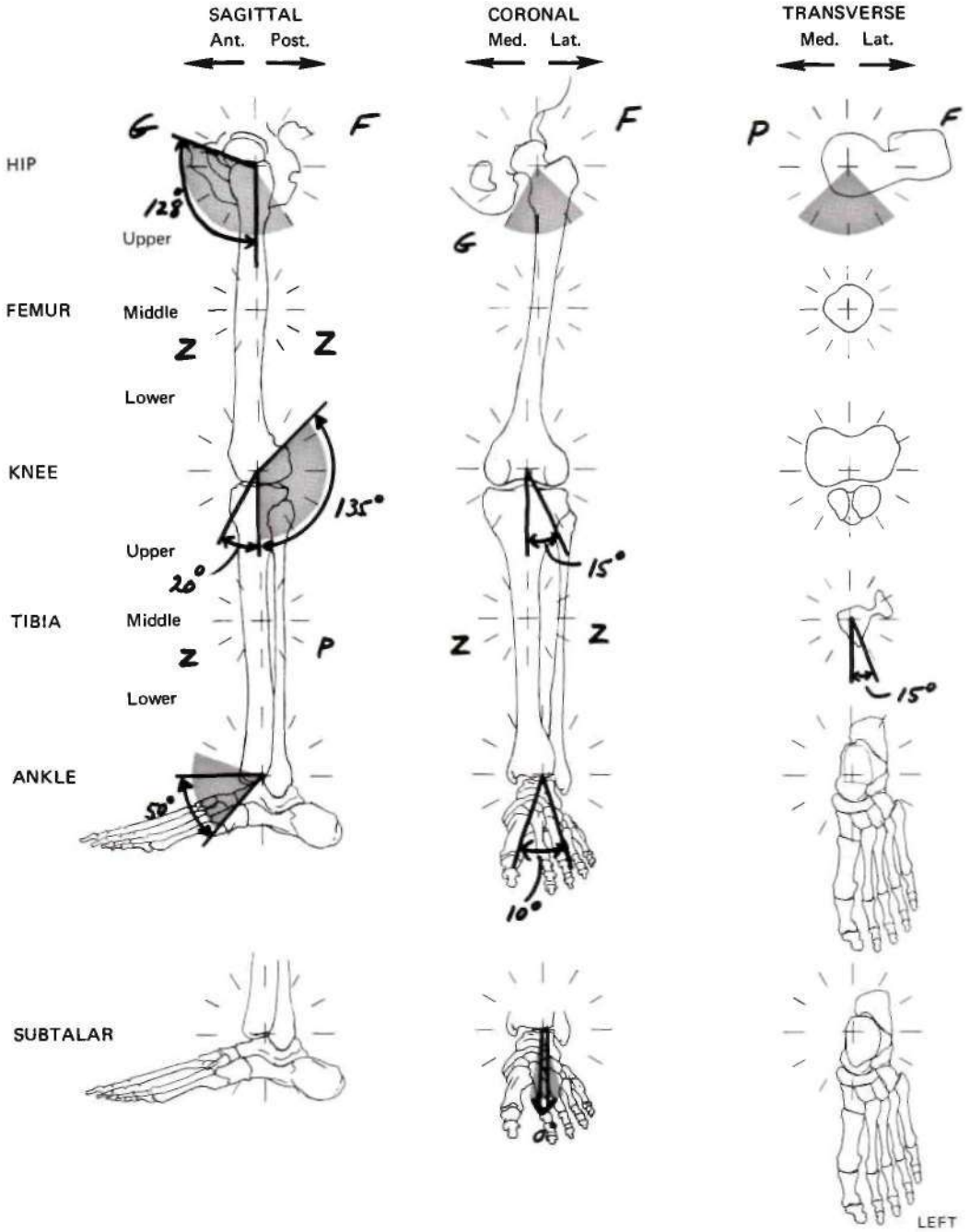
SP<sub>M</sub> = Mild  
 SP<sub>MO</sub> = Moderate  
 SP<sub>S</sub> = Severe



E = Edema

D = Local Distension or Enlargement

Fig. 10. Record for patient with residual poliomyelitis affecting his left lower extremity. Information given indicates flaccid paralysis with severe atrophy, laxity of the medial collateral ligament of the knee, and 1 3/4 in. shortening of the left lower extremity. In addition, the patient had an old supracondylar fracture of the femur and a previous triple arthrodesis.



(OVER)

Fig. 11. Diagram of patient W.S.'s left lower extremity. In addition to showing the letter grades for muscle-group strength, the diagram also shows 20° of hyperextension at the knee, 15° of valgus instability of the knee, 15° of external tibial torsion, limitation of dorsiflexion at the ankle, abnormal inversion and eversion at the ankle, and a fixed position of the subtalar joint.

Summary of Functional Disability *Flail knee and ankle; recurvatum (30°) and valgus (15°) of knee on weight-bearing; hip extensors inadequate for knee stability; abnormal ankle inversion and eversion 2° to triple arthrodosis; external tibial torsion 15°.*

Orthotic Recommendation *Single lateral upright (double bar) long leg brace with heavy-duty drop-look knee joint; posterior thigh cuff; Silesion bands; proximal pretibial cuff with posterior straps; 90° planter step at ankle; accommodate external tibial torsion.*

Fig. 12. Summary of patient W.S.'s functional limb disability, and the orthotic recommendation based upon that summary.

thotist. It is hoped that the material presented in this article will be an initial step toward that goal.

Work is currently being done on a similar approach to the upper extremity and the spine. These areas will be the subjects of future reports.

#### ACKNOWLEDGMENTS

The authors wish to express special appreciation to Dr. George T. Aitken, former chairman of the American Academy of Or-

thopaedic Surgeons Committee on Prosthetics and Orthotics; Dr. Robert Keagy; Mr. A. Bennett Wilson, Jr.; Mr. Anthony Staros; and Dr. Edward Peizer for their specific contributions to this work.

#### REFERENCES

1. Committee on Prosthetics Research and Development, *Report of the Seventh Workshop Panel on Lower-Extremity Orthotics of the Subcommittee on Design and Development*, National Research Council—National Academy of Sciences, March 1970.